

IMAGING PERFORMED BY

IntraPet.com



**SonoPath**

Clinical Sonography & Telecytology

EDUCATIONAL TELECONSULTATION SERVICES™

1-800-838-4268 info@sonopath.com SonoPath.com

**DATE**

2/27/23

**PATIENT**

Khaleesi Flores

**SPECIES**

Feline

**BREED**

DSH

**SEX**

Spayed Female

**AGE**

12/12/14

**WEIGHT**

8.4 Pounds

**INTERPRETED BY**

Eric Lindquist, DMV  
DABVP, Cert. IVUSS

**HOSPITAL NAME**

Animal Emergency  
Hospital

**REFERRING VET**

Dr. Martinoli

**INVOICE**

45520

**PRESENTING CLINICAL SIGNS**

Vomited w/blood today; hx of chronic vomiting. Appetite still good.

Current Medications: Protonix, Ondansetron, Gabapentin, Buprenorphine.

Date of Previous IntraPet Ultrasound: No previous.

Sedation: Not required to complete full diagnostic ultrasound.

Stat Report: Not requested.

Imaging Performed By: Andi Parkinson, BS, RDMS.

**ULTRASONOGRAPHIC EXAMINATION OF THE ABDOMEN**

**Urinary System**

The **urinary bladder**, trigone, and pelvic urethra presented normal thicknesses and normal tone. The ureters were not visible which is normal. No uroliths or sediment were visualized and anechoic urine was present. No evidence of inflammatory or neoplastic changes were noted. Ureteral papillae were normal.

The **kidneys** revealed normal size and structure, corticomedullary definition and ratio for this age. The cortices presented largely uniform texture with normal echogenic relationship to liver and spleen. Medullary structure differed distinctly from the cortex and no evidence of pelvic dilation was present. The capsules were acceptably uniform without significant irregularities. The left kidney measured 3.74 cm. The right kidney measured 3.74 cm.

**Adrenal Glands**

The regions of the **adrenal glands** were unremarkable.

**Spleen**

The **spleen** presented a smooth homogeneous parenchyma hyperechoic to liver and renal cortical parenchyma. The capsule was smooth without noticeable expansion or deviation from within the spleen or adjacent pathology. The splenic vasculature demonstrated normal volume without signs of congestion or thrombosis. No sonographic evidence of acute or chronic inflammatory, neoplastic, or infarctual changes were noted.

**Liver**

The **liver** images submitted revealed subjectively normal liver size, contour, and structure. Parenchymal echogenicity was naturally coarse and hypoechoic to the spleen. Vascular and biliary tracts were of normal volume with no evidence of congestion. The gallbladder presented acceptably thin walls with primarily anechoic content. The cystic and common bile ducts were normal. No pathological hepatic lymphadenopathy was evident. No overt structural evidence of inflammatory, infiltrative or regenerative pathology was evident.

**Gastrointestinal**

The **stomach** in this patient revealed concentric thickening of the fundus with loss of mural detail and enhanced surrounding mesentery. Maximum width of 2.5 cm. The entire pathology measured approximately 4.6 cm x 4.3 cm and continued into the gastroesophageal inlet. The abnormal tissue was significantly vascular. Some retention of ingesta was noted in the stomach. Areas of small intestine revealed minor wall thickening. Some enhanced fat consistent with inflammation noted around the gastric pathology.

**Pancreas**

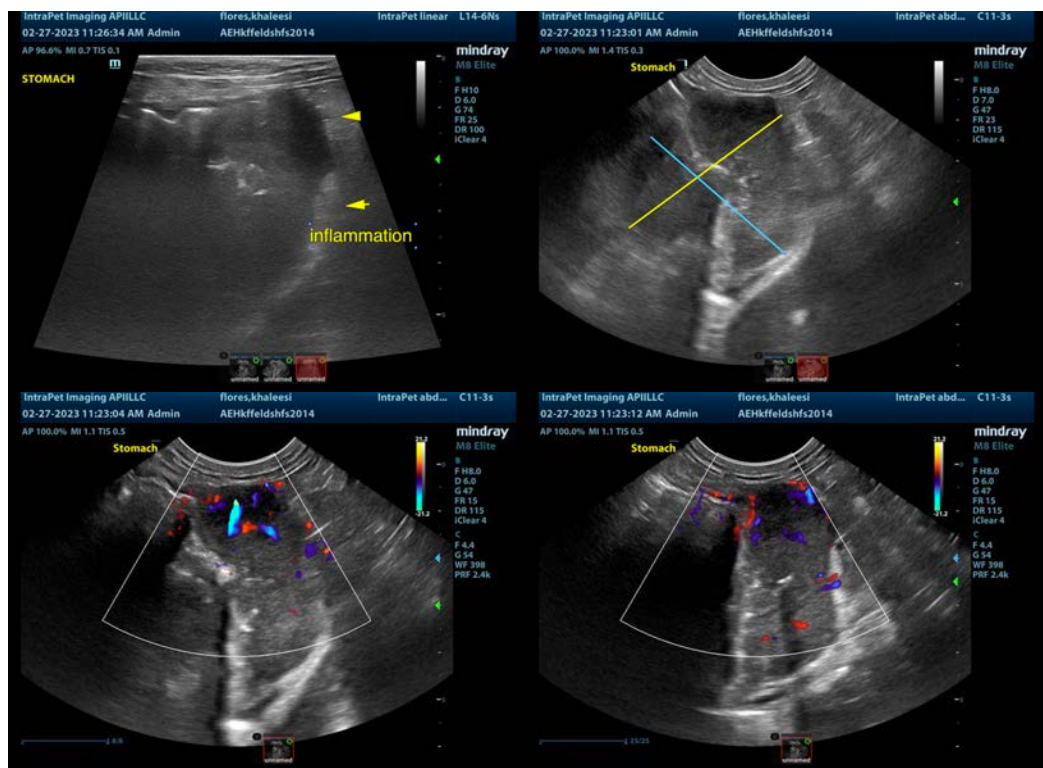
The base and limbs of the **pancreas** were observed to be largely isoechoic to surrounding omental fat. Pancreatic duct and capsular contour were acceptably normal and parenchyma respected normal curvilinear patterns. No overt evidence of active inflammatory or neoplastic disease was noted.

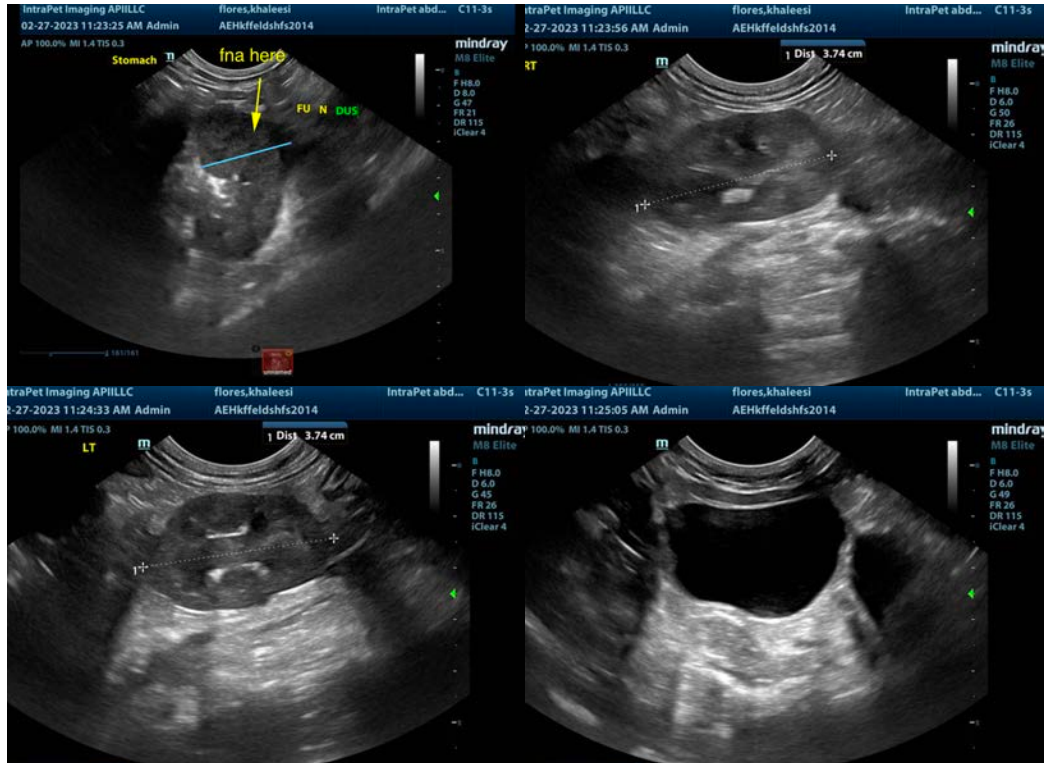
## ULTRASONOGRAPHIC FINDINGS

- Upper gastric mass with infiltration into the gastroesophageal inlet, unremarkable abdomen otherwise

## INTERPRETATION OF THE FINDINGS & FURTHER RECOMMENDATIONS

FNA warranted to confirm suspicion of lymphoma, and immediate chemotherapeutic intervention recommended. Granulomatous disease unlikely. The pathology is non-resectable, given its concentric fashion and infiltration into the gastroesophageal inlet.





The information and recommendations provided are based on the images presented by the referring veterinarian/sonographer. No evaluation can be communicated regarding pathology that was not visible in the image/video clips provided.

Thank you for this referral. If the clinical or image interpretation does not parallel your findings or if I can be of any further assistance please contact me.

**Eric Lindquist, DMV, DABVP, Cert. IVUSS, CEO of SonoPath.com**  
[info@SonoPath.com](mailto:info@SonoPath.com)