



PATIENT

Molly Ashby

SPECIES

Canine

BREED

Dachshund Mix

SEX

Spayed female

AGE

16 years

WEIGHT

18.6 lbs

INTERPRETED BY

Eric Lindquist, DMV
DABVP, Cert. IVUSS

IMAGING PERFORMED BY

Emma Flott

HOSPITAL NAME

Portland Veterinary
Wellness Center

REFERRING VET

Dr. Erickson

INVOICE

72011

DATE

2/26/26

PRESENTING CLINICAL SIGNS

- Patient presented for GI pain 5 days ago with reported softer stools. Appetite has been normal. Normal water intake, normal urination. No vomiting
- PE - heavy dental calculus, low BCS with muscle wasting over spine CBC - mild non-regenerative anemia, mild neutrophilia, mild monocytosis, thrombocytosis Chem - elevated ALP (297), elevated GGT (34), elevated Cholesterol (409) UA - USG 1.015, 1+ protein

ULTRASONOGRAPHIC EXAMINATION OF THE ABDOMEN

Urinary System

The **urinary bladder**, trigone, and pelvic urethra presented normal thicknesses and normal tone. The ureters were not visible which is normal. No uroliths or sediment were visualized and anechoic urine was present. No evidence of inflammatory or neoplastic changes was noted. Ureteral papillae were normal.

The **kidneys** revealed largely normal size and structure, corticomedullary definition and ratio (cortex 1/3 of medulla) were essentially maintained with some age-related loss of curvilinear patterns regarding the capsule and C/M junction. The cortices presented largely uniform texture with some increased echogenicity expected for this age patient. Medullary structure differed distinctly from that of the cortex. Slight pyelectasia was noted and measured 0.23 cm. The left kidney measured 5.6 cm in length. The right kidney measured 5.4 cm.

Adrenal Glands

The left **adrenal gland** was enlarged, hypoechoic and irregular measuring 1.5 cm at the caudal pole and 0.8 cm at the cranial pole and 0.8 cm at the cranial pole. There was capsular expansion without capsular escape nor vascular invasion appeared to be present. The right adrenal gland was enlarged, hypoechoic and irregular with swollen contour measuring 1.5 cm at the caudal pole and 1.4 cm at the cranial pole.

Spleen

The **spleen** was normal size and relatively normal contour with multifocal hyperechoic areas of mineralization. This is a benign change; however, can be related to Cushing's disease or other endocrinopathies.

Liver

The **liver** images from right and left intercostal as well as subcostal views revealed subjectively normal liver size, contour, and structure. Some age-related parenchymal remodeling was noted but likely not clinically significant at this time. Vascular and biliary tracts were of normal volume and no evidence of congestion was noted. The gallbladder presented some dependent debris with essentially normal contour. The cystic and common bile ducts were normal. No overt evidence of active inflammatory, infiltrative or regenerative pathology was noted but should be paired with current or past LE elevations regarding any clinical significance to this presentation. The hepatic lymph nodes were unremarkable.



PATIENT

Molly Ashby

SPECIES

Canine

BREED

Dachshund Mix

SEX

Spayed female

AGE

16 years

WEIGHT

18.6 lbs

INTERPRETED BY

Eric Lindquist, DMV
DABVP, Cert. IVUSS

IMAGING PERFORMED BY

Emma Flott

HOSPITAL NAME

Portland Veterinary
Wellness Center

REFERRING VET

Dr. Erickson

INVOICE

72011

DATE

2/26/26

Gastrointestinal

There was some residual chyme and gas was noted in the **stomach**, yet not pathological. This is consistent with post prandial presentation. There was a hypoechoic polyp in the gastric fundus measuring 2.0 cm and should be monitored. Transit of chyme into the small intestine was normal. Curvilinear patterns were maintained throughout the GI tract. No evidence of pathology. Small and large intestine demonstrated normal luminal chyme and stool consistency respectively. No obstructive or overt infiltrative disease was noted. No associated abnormal lymphatic activity was noted.

Pancreas

Diffuse hyperechoic changes were present in the area of the **pancreas**. The pancreatic remodeling was evident with multifocal to diffuse hyperechoic changes. These changes are consistent with fibrosis, amyloid, saponification of fat and may contain areas of low-grade chronic active inflammation especially if pain on imaging (+ Murphy sign) was present +/- focal subxiphoid palpation reveals pain response. No overt masses were noted.

ULTRASONOGRAPHIC FINDINGS

Bilateral irregular adrenal enlargement, most consistent with PDH.

Mineralized spleen, consistent with endocrinopathy.

Minor GI thickening.

Luminal material in the stomach, likely ingesta. This should be paired with prandial timing along with the sonogram. Hypoechoic polyp in the in the gastric fundus.

INTERPRETATION OF THE FINDINGS & FURTHER RECOMMENDATIONS

If the patient appears Cushingoid and urine specific gravity is persistently less than 1.020, then work-up for PDH is indicated. Management for gastrointestinal irritability/inflammatory bowel is possible. Ulcerative disease should all be considered.

Efficient & Accurate Cushing's Work up-Lindquist

Notes regarding Cushing's Clinical Presentations:

Nearly all Cushing's dogs have SAP elevations and true PU/PD (USG < 1.025) and most are polyphagic.

Cushing's dogs are > 6 years and usually > 9 years old, usually have poor skin coats, body scores > 3/5, and are usually sedentary animals.

Its important to remember that Cushing's dogs usually look and play the part and other diseases cause false + stress related cortisol spikes. On rare occasion a Cushing's dog will not follow the rules but this is truly an exception.

Potential Cushing's patient workups can be costly and frustrating if not definitive and, in my experience, the non-definitive patient usually has something else going on that may be contributing to



PATIENT

Molly Ashby

SPECIES

Canine

BREED

Dachshund Mix

SEX

Spayed female

AGE

16 years

WEIGHT

18.6 lbs

INTERPRETED BY

Eric Lindquist, DMV
DABVP, Cert. IVUSS

IMAGING PERFORMED BY

Emma Flott

HOSPITAL NAME

Portland Veterinary
Wellness Center

REFERRING VET

Dr. Erickson

INVOICE

72011

DATE

2/26/26

some of the clinical signs a Cushing's dog will have, especially SAP elevations or PU/PD. Based on this prelude of information I came up with the following algorithm in the spirit of diagnostic efficiency. The following suggested protocol is based on current available literature on Cushing's disease and extensive clinical-sonographic experience evaluation + Cushing's and False + LDDST & ACTH stim. cases in order to maximize the efficiency of a Cushing's workup in practice.

Screen first, workup second

1) **UA:** Repeatable (2-3 urine samples) Urine specific gravity & urine cortisol/creatinine ratio (UCCR): If **repeatable USG < 10.20 and + UCCR** move to next step 2.

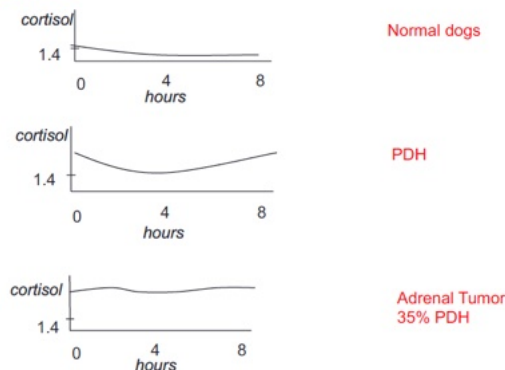
Note: UA is inexpensive and easy to obtain and if UA criteria is not met for Cushing's then resources can be spent into other more pertinent diagnostics or left on hold until the UA criteria is met in emerging Cushing's cases.

2) **Sonogram:** Does the patient **have concurrent disease** clinically or sonographically as non-Cushing's illness will influence the potential false + LDDST or even ACTH stim. The sonogram gives a global perspective of the internal health of the patient to be considered in the Cushing's workup as an assessment of concurrent disease. Is there a concurrent neoplastic process, UTI pancreatitis, mucocele...? Are the adrenals enlarged (Cushing's-PDH, stress, age related or breed variant), or atrophied (iatrogenic Cushing's or adrenal burnout), have asymmetric enlargement (Adrenal tumor, hyperplasia, adenoma, age related variant), or is there vascular invasion (Invasive pheo with false + UA criteria or adenocarcinoma or phrenic thrombosis)? The sonogram answers these questions proactively.

Address & treat concurrent disease first before performing Cushing's testing or testing will be artificially altered increasing false negatives and positives.

3) **LDDST** (0.01 D-Sodium phosphate mg/kg IV **with precise dosing******) (Better screening test but plagued with false + but considered more specific than ACTH stim) Use if there is potential early Cushing's or if adrenal asymmetry present on sonogram suspecting tumor. Use LDDST in cats at a higher dose (0.1 mg/kg IV). **Interpretation LDDST:** Look at 8-hour post first: If > 1.4 = Cushing's. Then look at 4-hour: if > 1.4 or > 50% baseline = Cushing's. 4-hour do then 8-hour spike most consistent with PDH. Flat line high constant curve without dip more consistent with tumor but can be PDH. See attached graph.

LDDS



Courtesy: Rebecca Berg DACVIM, DECVIM



PATIENT

Molly Ashby

SPECIES

Canine

BREED

Dachshund Mix

SEX

Spayed female

AGE

16 years

WEIGHT

18.6 lbs

INTERPRETED BY

Eric Lindquist, DMV
DABVP, Cert. IVUSS

IMAGING PERFORMED BY

Emma Flott

HOSPITAL NAME

Portland Veterinary
Wellness Center

REFERRING VET

Dr. Erickson

INVOICE

72011

DATE

2/26/26

4) **ACTH stim.** (Better confirming test but can have false +) Use if the patient “looks” Cushingoid or if bilateral adrenal enlargement is present, or high normal width on sonogram, or if iatrogenic Cushing’s suspected (Cortisone Tx in past). ACTH stim is better for diagnosis of Addisons, Iatrogenic Cushing’s, and Cushing’s therapy monitoring but problematic with initial Cushing’s diagnosis. First dx LDDST is suggested.

5) If **diabetic** then run both LDDST & ACTH stim but stabilize as much as possible first.

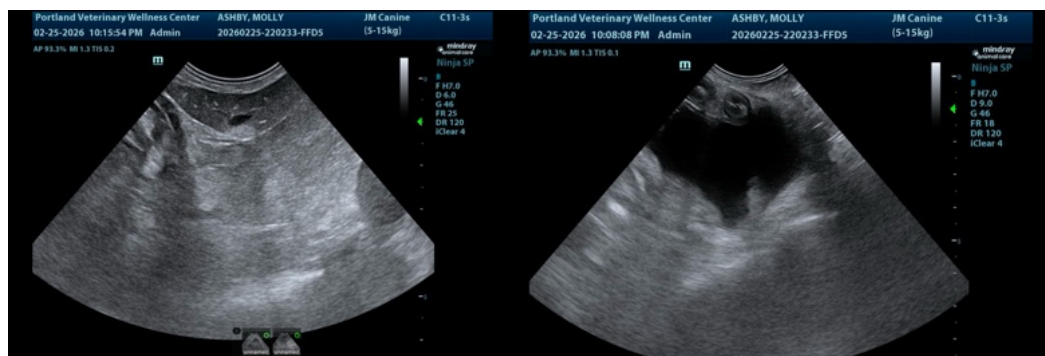
5) Run a **serial blood pressure** in a BP friendly non “white coat effect” atmosphere. Run at least 3 at different times over a few hours or when eating as the patient tends to be calm when eating or give Torbutrol when entering the facility. Cushing’s hypertension is usually 150-180 systolic range while pheochromocytoma range is more often > 180 systolic.

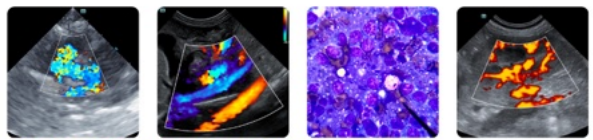
6) **Perform CT** of the pituitary to identify macro adenoma expansion if any lethargy or dullness or other central clinical CNS signs are minimally present. CT for adrenal may be more thorough for adrenalectomy surgical planning if ultrasound views of the CVC were problematic.

7) **Adrenalectomy** for adrenal mass is prescribed then it is essential to stabilize the patient first regarding secondary disease such as organ dysfunction, hypertension, diabetes mellitus, hypernatremia, thromboembolic risk urinary and other infection in order to minimize potential for operative and postoperative complications as they are common in adrenalectomy. Trilostane stabilization therapy for Cushing’s would be the first approach then address surgery and hypertension should be managed ideally < 160 systolic with ace inhibitors, phenoxybenzamine, or amlodipine.

Suggested reading:

Behrend EN, Kooistra HS, Nelson R, et al. Diagnosis of Spontaneous Canine Hyperadrenocorticism: 2012 ACVIM Consensus Statement (Small Animal). J Vet Intern Med 2013;27:1292-1304.





PATIENT

Molly Ashby

SPECIES

Canine

BREED

Dachshund Mix

SEX

Spayed female

AGE

16 years

WEIGHT

18.6 lbs

INTERPRETED BY

Eric Lindquist, DMV
DABVP, Cert. IVUSS

IMAGING PERFORMED BY

Emma Flott

HOSPITAL NAME

Portland Veterinary
Wellness Center

REFERRING VET

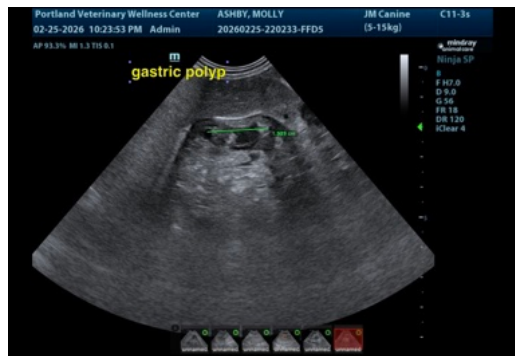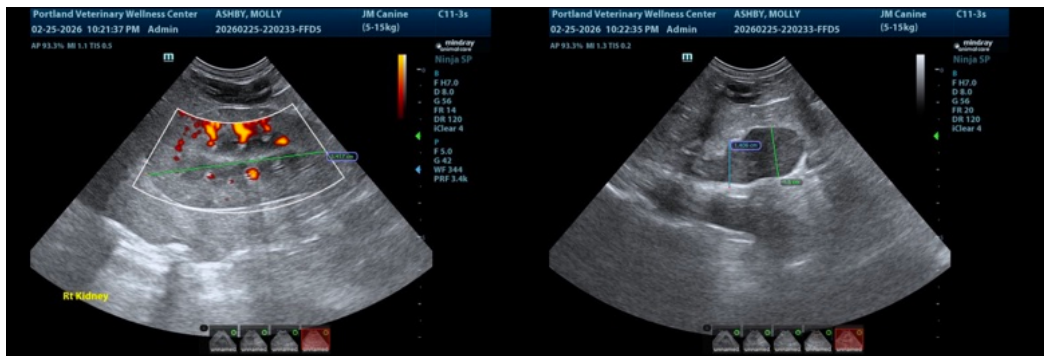
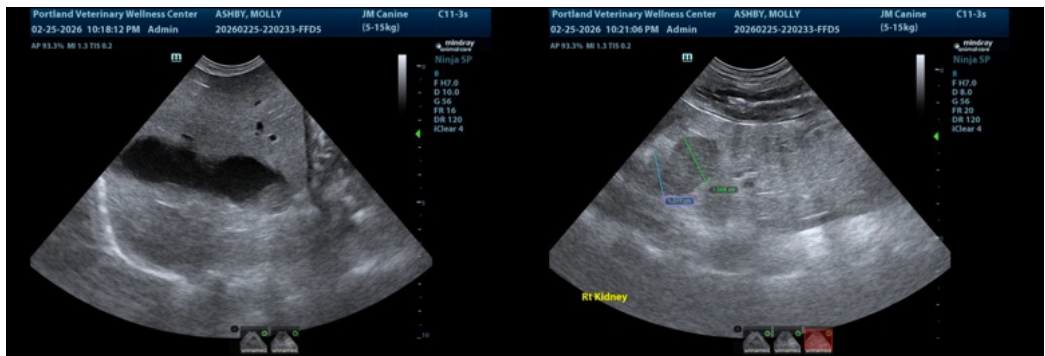
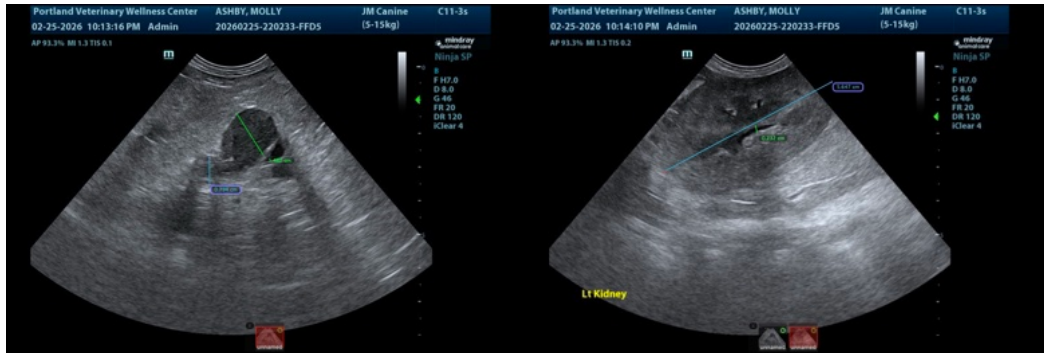
Dr. Erickson

INVOICE

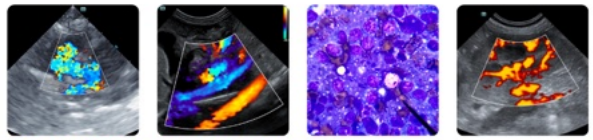
72011

DATE

2/26/26



The information and recommendations provided are based on the images presented by the referring veterinarian/sonographer. No evaluation can be communicated regarding pathology that was not visible in the image/video clips provided.



PATIENT

Molly Ashby

SPECIES

Canine

BREED

Dachshund Mix

SEX

Spayed female

AGE

16 years

WEIGHT

18.6 lbs

INTERPRETED BY

Eric Lindquist, DMV
DABVP, Cert. IVUSS

IMAGING PERFORMED BY

Emma Flott

HOSPITAL NAME

Portland Veterinary
Wellness Center

REFERRING VET

Dr. Erickson

INVOICE

72011

DATE

2/26/26

Thank you for this referral. If the clinical or image interpretation does not parallel your findings or if I can be of any further assistance please contact me.

Eric Lindquist, DMV, DABVP (CFM), Cert. IVUSS, CEO of SonoPath.com

info@SonoPath.com