



**PATIENT**

Sadie Hince

**SPECIES**

Canine

**BREED**

Pomeranian

**SEX**

Spayed Female

**AGE**

13 Years

**WEIGHT**

6.7 Pounds

**INTERPRETED BY**

Eric Lindquist, DMV

DABVP, Cert. IVUSS

**IMAGING PERFORMED BY**

Dr. Sarah Green

**HOSPITAL NAME**

Healing Spirit

**REFERRING VET**

Dr. Sarah Green

**INVOICE**

45507

**DATE**

2/26/23

**PRESENTING CLINICAL SIGNS**

Presented due to increased respiratory effort, several days duration. Diagnosed with cardiac disease elsewhere. Currently treated with Pimobendan and Enalapril, (no Furosemide). Thoracic radiographs showed cardiomegaly with pleural effusion. Ultrasound performed following administration of Butorphanol, Furosemide, thoracentesis, and supplemental oxygen

Abnormal PE/Chem/CBC/UA Results: Increased inspiratory effort, thin body condition, grade 5/6 left and right systolic murmur

**ULTRASONOGRAPHIC EXAMINATION OF THE HEART**

CANINE CARDIAC PARAMETERS	MR VMAX (m/s)	TR VMAX (m/s)	LA/AO (Boon method)	LA/AO (Heart Base; Swe)	FS (%)	EF (%)	EPSS (cm)
NORMAL PARAMETER	4.5-5.5	<2.7	1.3	<1.6	28-40	40-100	<0.6
PATIENT		3.5	1.3		40		0.1
CANINE CARDIAC PARAMETERS	HR (BPM)	AV VMAX (m/s)	PV MAX (m/s)	BODY WEIGHT (kg)	LA 2D short axis Base view (cm)	LVIDd Avg; 2D and m-mode short axis (cm)	LVIDs Avg; 2D and m-mode short axis (cm)
NORMAL PARAMETER	50-100	0.7-1.7	0.7-1.6	BELOW	BELOW	BELOW	BELOW
PATIENT	90		1.0		2.26	1.9	

**Cardiac Presentation**

Comet tail lung pattern noted, indicative of alveolar disease. Variable areas of lung consolidation noted with an overt mass at the heart base. Pleural effusion noted. Secondary passive congestion noted in the liver owing to likely a combination of extra-cardiac obstructive caval disease as well as pulmonary hypertension. The heart itself revealed mildly enlarged right side with tricuspid insufficiency. 1:1 ratio of the right atrium to left atrium noted. Minor vegetative changes noted in the mitral and tricuspid valves, yet the heart is not a primary issue, given that no left-sided volume overload is present. Severe hepatic vein dilation as present.

**ULTRASONOGRAPHIC FINDINGS**

- Mitral valve disease
- Compensated left heart with enlarged right heart

**INTERPRETATION OF THE FINDINGS & FURTHER RECOMMENDATIONS**

Pleurocentesis and cytospin warranted to assess for exfoliating neoplasia. Pleurocentesis drainage followed by chest CT would be ideal. Abdominal sonogram warranted to rule out primary disease. Sildenafil, ACE inhibitor, and Spironolactone could be considered from a palliative standpoint. However, extracardiac disease should be the focus of further diagnostic workup. Prognosis is poor.



**PATIENT**

Sadie Hince

**SPECIES**

Canine

**BREED**

Pomeranian

**SEX**

Spayed Female

**AGE**

13 Years

**WEIGHT**

6.7 Pounds

**INTERPRETED BY**

Eric Lindquist, DMV

DABVP, Cert. IVUSS

**IMAGING PERFORMED BY**

Dr. Sarah Green

**HOSPITAL NAME**

Healing Spirit

**REFERRING VET**

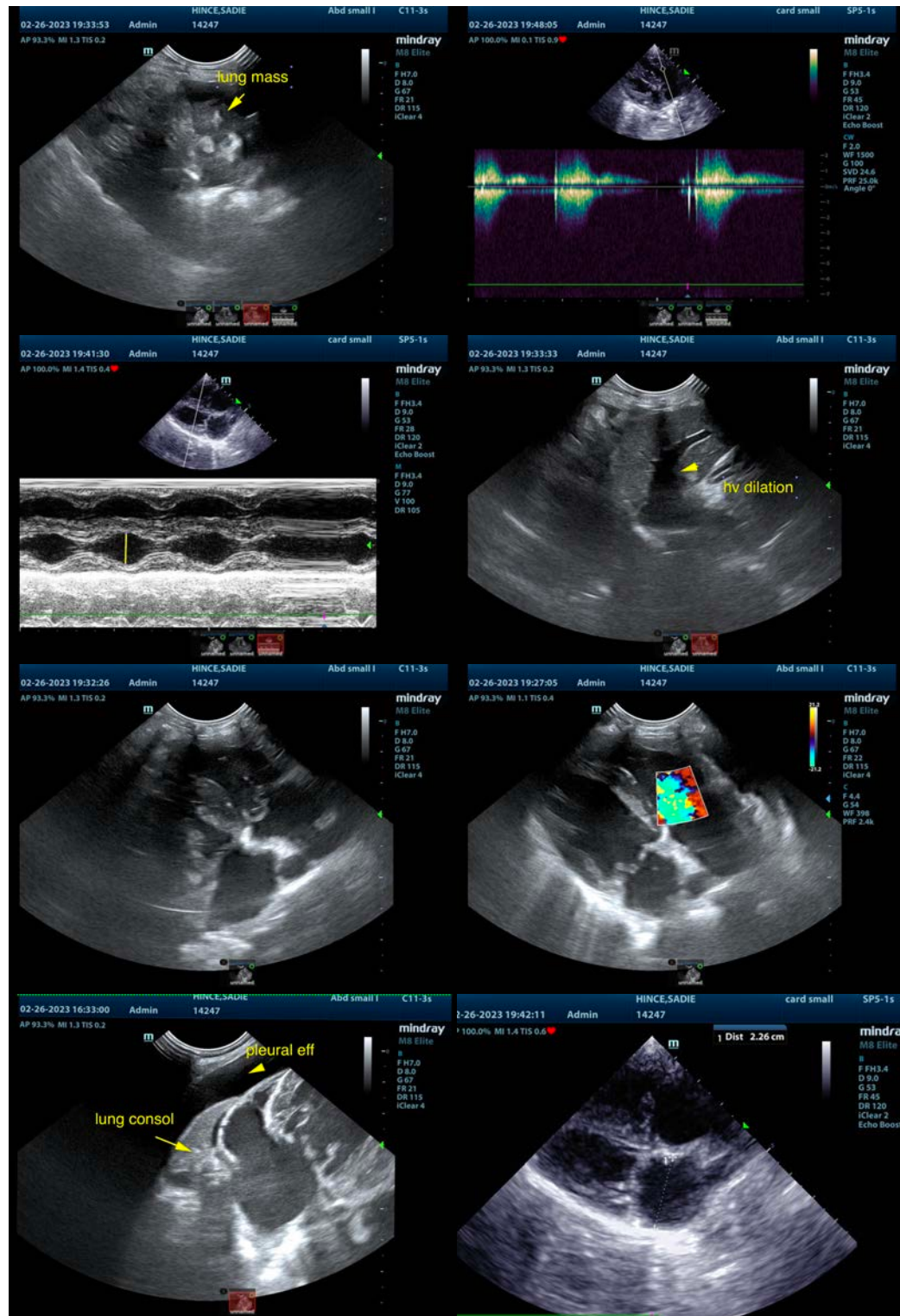
Dr. Sarah Green

**INVOICE**

45507

**DATE**

2/26/23





**PATIENT**

Sadie Hince

**SPECIES**

Canine

**BREED**

Pomeranian

**SEX**

Spayed Female

**AGE**

13 Years

**WEIGHT**

6.7 Pounds

**INTERPRETED BY**

Eric Lindquist, DMV

DABVP, Cert. IVUSS

**IMAGING PERFORMED BY**

Dr. Sarah Green

**HOSPITAL NAME**

Healing Spirit

**REFERRING VET**

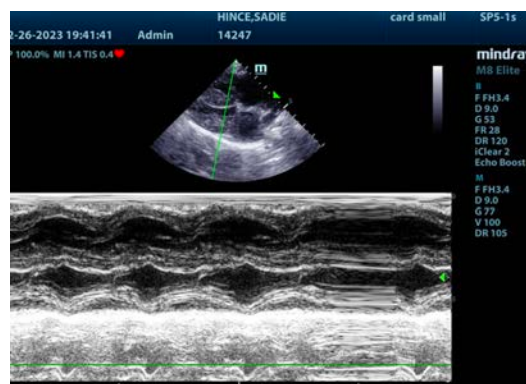
Dr. Sarah Green

**INVOICE**

45507

**DATE**

2/26/23



The information and recommendations provided are based on the images presented by the referring veterinarian/sonographer. No evaluation can be communicated regarding pathology that was not visible in the image/video clips provided.

Thank you for this referral. If the clinical or image interpretation does not parallel your findings or if I can be of any further assistance please contact me.

Eric Lindquist, DMV, DABVP, Cert. IVUSS, CEO of SonoPath.com

[info@SonoPath.com](mailto:info@SonoPath.com)