



PATIENT

Mary Jane Ely

SPECIES

Canine

BREED

Lab Retriever

SEX

Spayed Female

AGE

13 Years

WEIGHT

71.3

INTERPRETED BY

Eric Lindquist, DMV

DABVP, Cert. IVUSS

IMAGING PERFORMED BY

Dr. Sarah Green

HOSPITAL NAME

Healing Spirit

REFERRING VET

Dr. Sarah Green

INVOICE

45506

DATE

2/26/23

PRESENTING CLINICAL SIGNS

Presented due to acute onset of multiple syncopal episodes, had been hyporexic and lethargic the previous day, no other prior problems. No history of cough or exercise intolerance. No known exposure to toxins.

Abnormal PE/Chem/CBC/UA Results: Intermittent tachyarrhythmia, dropped beats coinciding with syncopal episodes, NSF otherwise. CBC: mild hemoconcentration, CHEMISTRY: elevated ALT=313 (10-118) U/L, ALP=457 (20-150) U/L, BUN=56 (7-25) mg/dL, Cr=2.2 (0.7-1.4) mg/dL, Lepto Ab - Negative

ULTRASONOGRAPHIC EXAMINATION OF THE HEART & ABDOMEN

CANINE CARDIAC PARAMETERS	MR VMAX (m/s)	TR VMAX (m/s)	LA/AO (Boon method)	LA/AO (Heart Base; Swe)	FS (%)	EF (%)	EPSS (cm)
NORMAL PARAMETER	4.5-5.5	<2.7	1.3	<1.6	28-40	40-100	<0.6
PATIENT			1.0	--	35	--	0.1
CANINE CARDIAC PARAMETERS	HR (BPM)	AV VMAX (m/s)	PV MAX (m/s)	BODY WEIGHT (kg)	LA 2D short axis Base view (cm)	LVIDd Avg; 2D and m-mode short axis (cm)	LVIDs Avg; 2D and m-mode short axis (cm)
NORMAL PARAMETER	50-100	0.7-1.7	0.7-1.6	BELOW	BELOW	BELOW	BELOW
PATIENT	--	--	--		--	3.9	

Cardiac Presentation

The echocardiogram in this patient demonstrated normal **left atrial** size based on 3 separate methods of LA evaluation. The cranial and caudal **mitral** valve leaflets presented normal linear structure, extension in systole, and union in diastole with normal kinesis. The **left ventricle** presented thicknesses with linear contour and was not dilated nor restricted. The **myocardium** presented normal echogenicity without subjective evidence of significant fibrotic or ischemic disease. **Contractility** of the ventricular walls was adequate and in normal range for this patient evidenced by the fractional shortening measurement and subjective evaluation of the different regions of the myocardium. The **left ventricular outflow** tract demonstrated normal laminar flow and subjective structural integrity. The **right atrium** and auricle revealed normal size, structure and content. No evidence of masses was noted. **Tricuspid** valvular assessment demonstrated adequate linear morphology and kinesis. The **right ventricle** was of normal size (1/3 diameter of LV), chordae structure, myocardial echogenicity and thickness. **Pulmonary outflow** tract assessment revealed normal valve structure, laminar flow, and diameter (approx.1:1 pa/ao ratio). No visible **pericardial** or free pleura fluid was noted. The cranial **mediastinum and pericardial and extra-cardiac regions** were free of masses in the visible window. Persistent arrhythmia noted.



PATIENT

Urinary System

Mary Jane Ely

The **urinary bladder**, trigone, and pelvic urethra presented normal thicknesses and normal tone. The ureters were not visible which is normal. No uroliths or sediment were visualized and anechoic urine was present. No evidence of inflammatory or neoplastic changes were noted. Ureteral papillae were normal.

SPECIES

Canine

BREED

Lab Retriever

SEX

Spayed Female

The **kidneys** revealed largely normal size and structure, corticomedullary definition and ratio (cortex 1/3 of medulla) were essentially maintained with some age-related loss of curvilinear patterns regarding the capsule and C/M junction. The cortices presented largely uniform texture with some increased echogenicity expected for his age patient. Medullary structure differed distinctly from that of the cortex and no evidence of pelvic dilation was present. Pinpoint mineralizations noted on the right kidney. The right kidney measured 6.25 cm.

AGE

13 Years

Adrenal Glands

The **left adrenal gland** was enlarged, irregular, and hypoechoic with irregular phrenic vein occupation, potential early invasion. The left adrenal gland measured 2.8 cm x 1.4 cm.

WEIGHT

71.3

A structure in the region of the **right adrenal gland** was present measuring approximately 3.4 cm x 1.15 cm, visualized obliquely.

Spleen

The **spleen** presented a smooth homogeneous parenchyma hyperechoic to liver and renal cortical parenchyma. The capsule was smooth without noticeable expansion or deviation from within the spleen or adjacent pathology. The splenic vasculature demonstrated normal volume without signs of congestion or thrombosis. No sonographic evidence of acute or chronic inflammatory, neoplastic, or infarctual changes were noted.

INTERPRETED BY

Eric Lindquist, DMV

DABVP, Cert. IVUSS

Liver

The **liver** was uniformly swollen with minor, excessive gallbladder debris and over distension with dependent and suspended bile without evidence of overt mucocele formation. However, excessive sludge was present. The liver presented coarse architecture with mildly increased portal markings and subtle, mixed echogenic changes. This is consistent with vacuolar hepatopathy and some level of remodeling and history of inflammatory component. There was no overt suspicion of neoplasia.

IMAGING PERFORMED BY

Dr. Sarah Green

HOSPITAL NAME

Healing Spirit

Gastrointestinal

REFERRING VET

Dr. Sarah Green

The **stomach** was filled with ingesta or soft foreign matter. The small intestine and colon were unremarkable.

INVOICE

45506

Pancreas

The base and limbs of the **pancreas** were observed to be largely isoechoic to surrounding omental fat. Pancreatic duct and capsular contour were acceptably normal and parenchyma respected normal curvilinear patterns. No overt evidence of active inflammatory or neoplastic disease was noted.

DATE

2/26/23

ULTRASONOGRAPHIC FINDINGS

- Normal echocardiogram with arrhythmogenic activity
- Enlarged irregular left adrenal gland with possible phrenic vein invasion
- Mildly heterogeneous right adrenal gland, though not visualized obliquely
- Age related renal changes
- Retention of ingesta or soft foreign matter in the stomach



PATIENT

- Low-grade inflammatory hepatopathy likely

Mary Jane Ely

INTERPRETATION OF THE FINDINGS & FURTHER RECOMMENDATIONS

SPECIES

Recommend EKG and holter monitor in this patient. Holter monitor can be obtained from our office. Blood pressure measurements warranted. If hypertension is present, urine catecholamine indicated. The kidneys do not appear end stage. Therefore, prerenal disease or complications owing to pheochromocytoma may be playing a role. The remainder of the abdomen appears to have changes consistent with geriatric patient of this breed. FNA of the liver could be considered for further definition, however subjectively appears benign.

Canine

BREED

Lab Retriever

SEX

Spayed Female

AGE

13 Years

WEIGHT

71.3

INTERPRETED BY

Eric Lindquist, DMV
DABVP, Cert. IVUSS

IMAGING PERFORMED BY

Dr. Sarah Green

HOSPITAL NAME

Healing Spirit

REFERRING VET

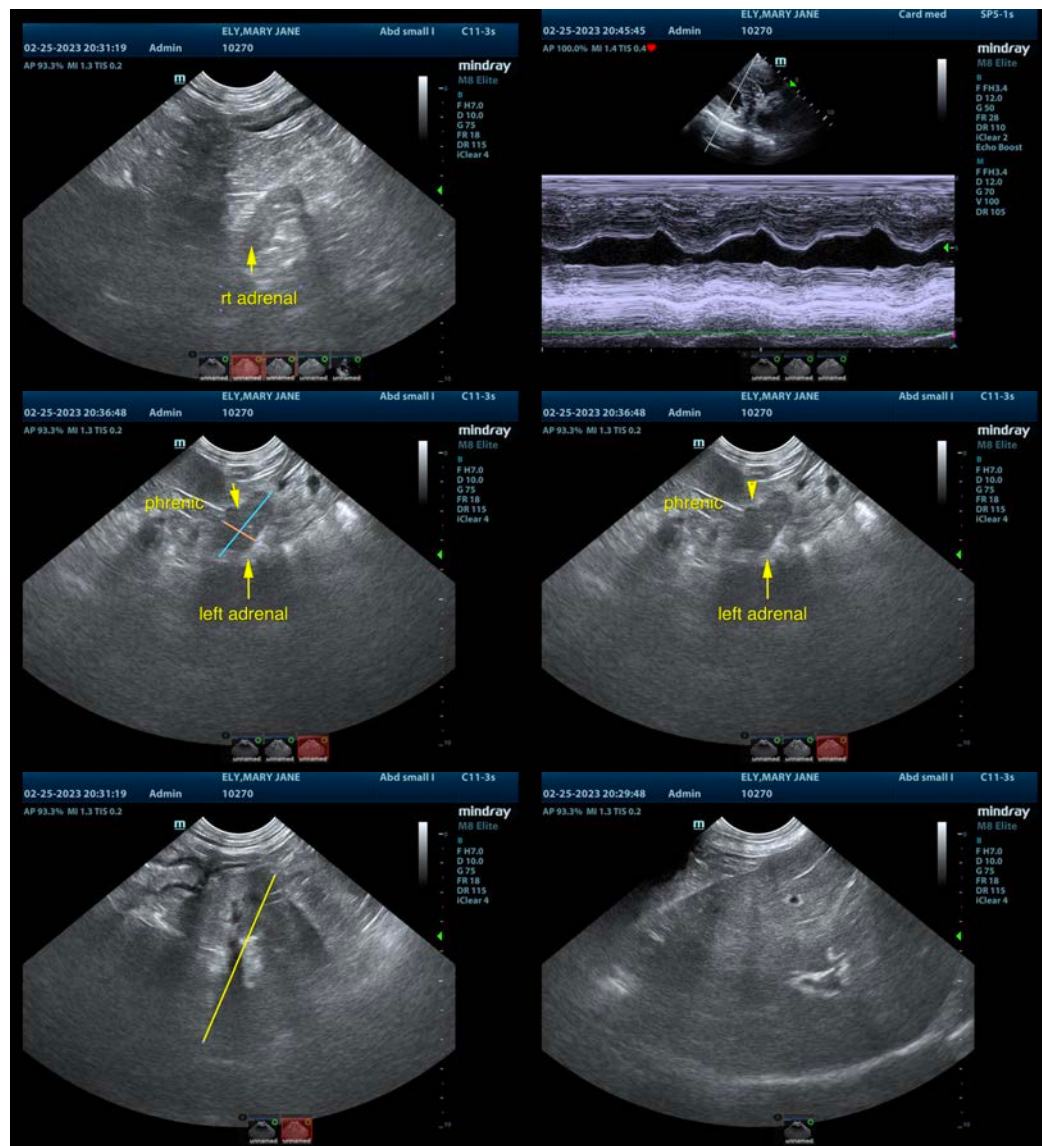
Dr. Sarah Green

INVOICE

45506

DATE

2/26/23





PATIENT

Mary Jane Ely

SPECIES

Canine

BREED

Lab Retriever

SEX

Spayed Female

AGE

13 Years

WEIGHT

71.3

INTERPRETED BY

Eric Lindquist, DMV
DABVP, Cert. IVUSS

IMAGING PERFORMED BY

Dr. Sarah Green

HOSPITAL NAME

Healing Spirit

REFERRING VET

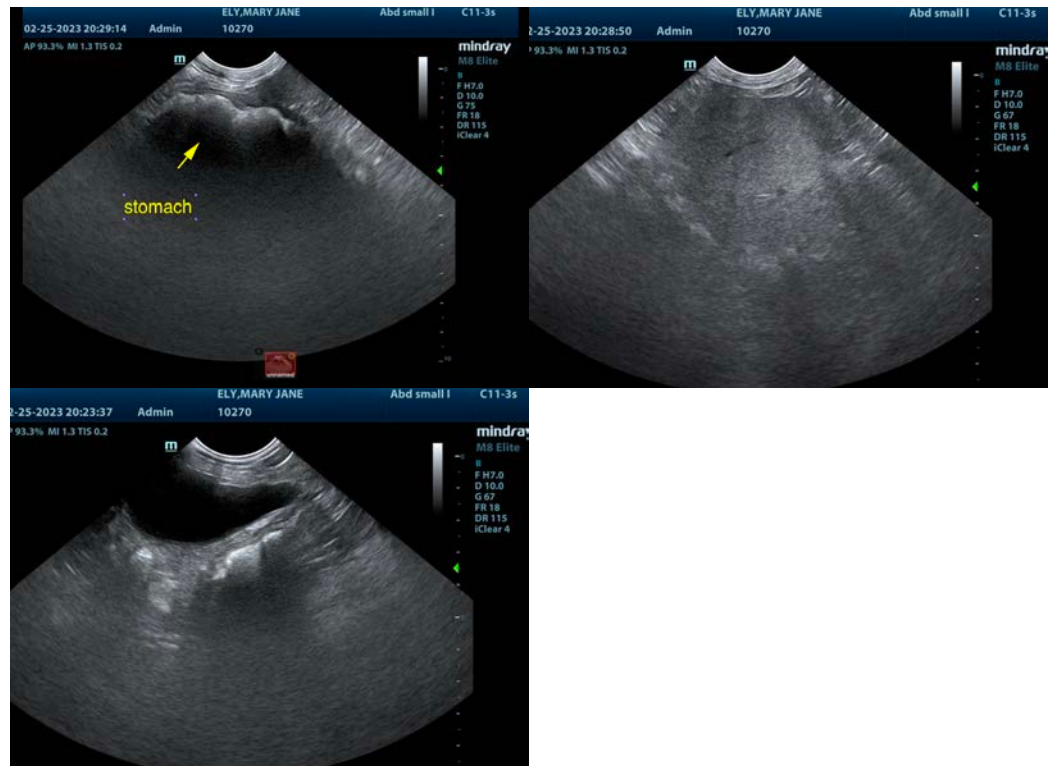
Dr. Sarah Green

INVOICE

45506

DATE

2/26/23



The information and recommendations provided are based on the images presented by the referring veterinarian/sonographer. No evaluation can be communicated regarding pathology that was not visible in the image/video clips provided.

Thank you for this referral. If the clinical or image interpretation does not parallel your findings or if I can be of any further assistance please contact me.

Eric Lindquist, DMV, DABVP, Cert. IVUSS, CEO of SonoPath.com

info@SonoPath.com