



PATIENT

Garfield Muenger

SPECIES

Feline

BREED

DSH

SEX

Neutered Male

AGE

3.5 Years

WEIGHT

20.5 Pounds

INTERPRETED BY

Eric Lindquist, DMV

DABVP, Cert. IVUSS

IMAGING PERFORMED BY

Dr. Kitz

HOSPITAL NAME

Woodlands AH

REFERRING VET

Dr. Danielle Kitz

INVOICE

35929

DATE

2/26/22

PRESENTING CLINICAL SIGNS

Patient presented after an episode of acute collapse that was deemed to be either a primary neurologic or a syncopal episode based on history; on exam the patient was QAR, tachycardic, with Grade III sternal systolic murmur detected on exam. He was previously examined within the past year and did not have any appreciable murmur at any past visit. ECG showed a sinus tachycardia; BP was 140 with Doppler; chest radiographs were performed and the report is attached below. Administered 6.25 mg of Atenolol and recommended that cat return for echo the following day.
Abnormal PE/Chem/CBC/UA Results: Labwork performed the day of presentation - all normal - includes CBC, Superchem, T4 and UA cardiac BNP to IDEXX was 100

ULTRASONOGRAPHIC EXAMINATION OF THE HEART

FELINE CARDIAC PARAMETERS	BODY WEIGHT (kg)	HR (BPM)	IVSd (cm)	LVIDd (cm)	LVWd (cm)	FS (%)	EF (%)
NORMAL PARAMETER	-----	150-240	0.3-0.6	1.0-2.1	0.25-0.6	35-67	80-100
PATIENT		NM	0.6	1.55	0.7	50	--
FELINE CARDIAC PARAMETERS	LA/AO (Boon)	LA/AO HEART BASE (Sisson)	LA 2D 4-chamber long axis AS to FW (Sisson) (cm)	LVOT VEL. (m/s)	RVOT VEL. (m/s)	IVRT (m/)	
NORMAL PARAMETER	<1.5	0.88-1.79	0.7-1.7	<1.6	<1.3	40-60	
PATIENT	1.4	1.4	1.2	--	0.6	NM	

Adapted from June Boon, Veterinary Echocardiography, 1998
Sisson D et al. JVIM 1991; 5: 232, Jacobs et al. Am J Vet Res 1985; 46:1705

Cardiac Presentation

The echocardiogram in this patient demonstrated normal **left atrial** size based on 3 separate LA measurements. The cranial and caudal **mitral** valve leaflets presented normal linear structure and kinetics. The **left ventricle** presented slight concentric hypertrophy, yet not clinically significant. The **myocardium** presented normal echogenicity without subjective evidence of significant fibrotic or ischemic disease. **Contractility** of the ventricular walls was adequate and in normal range for this patient evidenced by the fractional shortening measurement and subjective evaluation of the different regions and angles of the myocardium. The **left ventricular outflow** tract demonstrated minor turbulence. The **right atrium** and auricle revealed normal size, structure and content. No evidence of masses was noted or chamber overload. **Tricuspid** valvular assessment demonstrated adequate linear morphology and kinetics. The **right ventricle** was of normal size (1/3 diameter of LV), chordae structure, myocardial echogenicity and thickness. **Pulmonic** tract assessment revealed normal valve structure, laminar flow, and diameter (approx. 1:1 pa/ao ratio). No visible **pericardial** or free pleura fluid was noted or extra cardiac pathology in the visible planes. The cranial **mediastinum and pericardial regions** were free of masses in the visible window.

ULTRASONOGRAPHIC FINDINGS

- Slight left ventricular hypertrophy
- Normal function and volumes of the heart



PATIENT

Garfield Muenger

SPECIES

Feline

BREED

DSH

SEX

Neutered Male

AGE

3.5 Years

WEIGHT

20.5 Pounds

INTERPRETED BY

Eric Lindquist, DMV

DABVP, Cert. IVUSS

IMAGING PERFORMED BY

Dr. Kitz

HOSPITAL NAME

Woodlands AH

REFERRING VET

Dr. Danielle Kitz

INVOICE

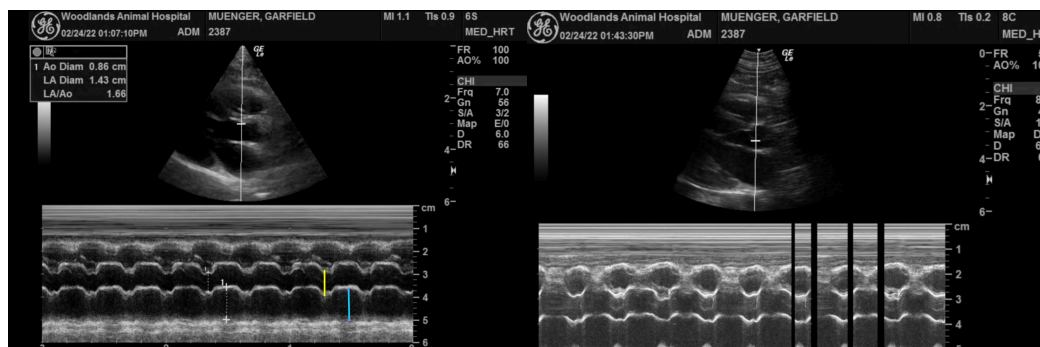
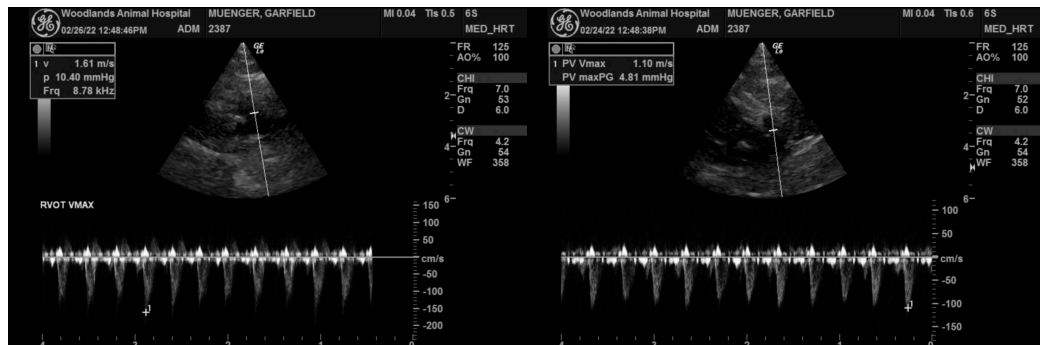
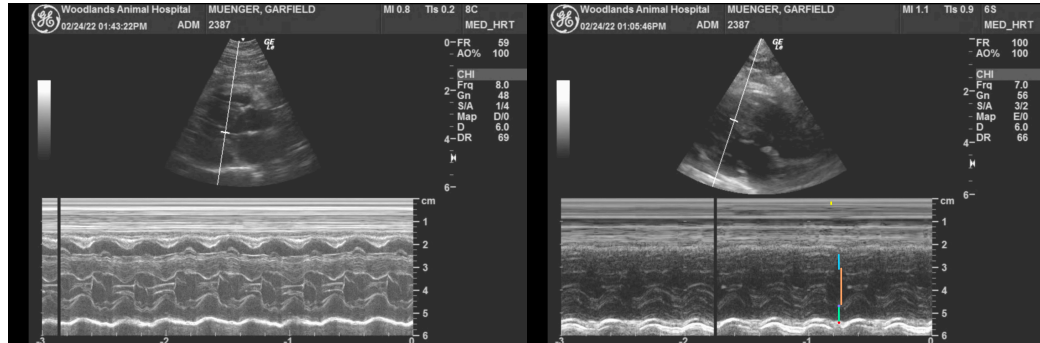
35929

DATE

2/26/22

INTERPRETATION OF THE FINDINGS & FURTHER RECOMMENDATIONS

Unless paroxysmal arrhythmia is an issue, I do not believe that the syncope is primary cardiac, as the changes are very minor. This may be a very minor form of hypertrophic cardiomyopathy, yet not clinically significant at this time. Recheck echo in 6-12 months. Blood pressures and thyroid evaluation warranted if not already performed.



The information and recommendations provided are based on the images presented by the referring veterinarian/sonographer. No evaluation can be communicated regarding pathology that was not visible in the image/video clips provided.

Thank you for this referral. If the clinical or image interpretation does not parallel your findings or if I can be of any further assistance please contact me.

Eric Lindquist, DMV, DABVP, Cert. IVUSS, CEO of SonoPath.com

info@SonoPath.com