



PATIENT

Raven Darienzo

PRESENTING CLINICAL SIGNS

Elevated ALP, extreme weight loss.

SPECIES

Canine

ULTRASONOGRAPHIC EXAMINATION OF THE ABDOMEN

Urinary System

The **urinary bladder**, trigone, and pelvic urethra presented normal thicknesses and normal tone. The ureters were not visible which is normal. No uroliths or sediment were visualized and anechoic urine was present. No evidence of inflammatory or neoplastic changes were noted. Ureteral papillae were normal.

BREED

Lab Retriever

The **kidneys** revealed normal size and structure, corticomedullary definition and ratio for this age. The cortices presented largely uniform texture with normal echogenic relationship to liver and spleen. Medullary structure differed distinctly from the cortex and no evidence of pelvic dilation was present. The capsules were acceptably uniform without significant irregularities. The left kidney measured 6.69 cm. The right kidney measured 6.28 cm.

SEX

Spayed Female

AGE

7 Years

Adrenal Glands

The **left adrenal gland** presented normal size and contour, measuring 2.1 cm x 0.64 cm. The **right adrenal gland** presented a mass of approximately 5.0 cm x 3.0 cm without vena cava invasion. The vena cava was free of evident pathology.

WEIGHT

74 Pounds

Spleen

The **spleen** presented a smooth homogeneous parenchyma hyperechoic to liver and renal cortical parenchyma. The capsule was smooth without noticeable expansion or deviation from within the spleen or adjacent pathology. The splenic vasculature demonstrated normal volume without signs of congestion or thrombosis. No sonographic evidence of acute or chronic inflammatory, neoplastic, or infarctual changes were noted.

INTERPRETED BY

Eric Lindquist, DMV

DABVP, Cert. IVUSS

Liver

The **liver** images submitted revealed subjectively normal liver size, contour, and structure. Parenchymal echogenicity was naturally coarse and hypoechoic to the spleen. Vascular and biliary tracts were of normal volume with no evidence of congestion. The gallbladder presented acceptably thin walls with primarily anechoic content. The cystic and common bile ducts were normal. No pathological hepatic lymphadenopathy was evident. No overt structural evidence of inflammatory, infiltrative or regenerative pathology was evident.

IMAGING PERFORMED BY

Eric Lindquist, DMV

DABVP, Cert. IVUSS

HOSPITAL NAME

Butler Vet Hospital

Gastrointestinal

Examination of the **gastrointestinal tract** revealed a stomach and intestine free of stasis, of normal wall thickness, acceptable curvilinear mural detail, and peristaltic activity. Small and large intestine demonstrated normal luminal chyme and stool consistency respectively. No obstructive or overt infiltrative disease was noted. No associated abnormal lymphatic activity was noted.

REFERRING VET

Dr. Garro

Pancreas

INVOICE

35906

The base and limbs of the **pancreas** were observed to be largely isoechoic to surrounding omental fat. Pancreatic duct and capsular contour were acceptably normal and parenchyma respected normal curvilinear patterns. No overt evidence of active inflammatory or neoplastic disease was noted.

DATE

2/25/22



PATIENT

Raven Darienzo

SPECIES

Canine

BREED

Lab Retriever

SEX

Spayed Female

AGE

7 Years

WEIGHT

74 Pounds

INTERPRETED BY

Eric Lindquist, DMV
DABVP, Cert. IVUSS

IMAGING PERFORMED BY

Eric Lindquist, DMV
DABVP, Cert. IVUSS

HOSPITAL NAME

Butler Vet Hospital

REFERRING VET

Dr. Garro

INVOICE

35906

DATE

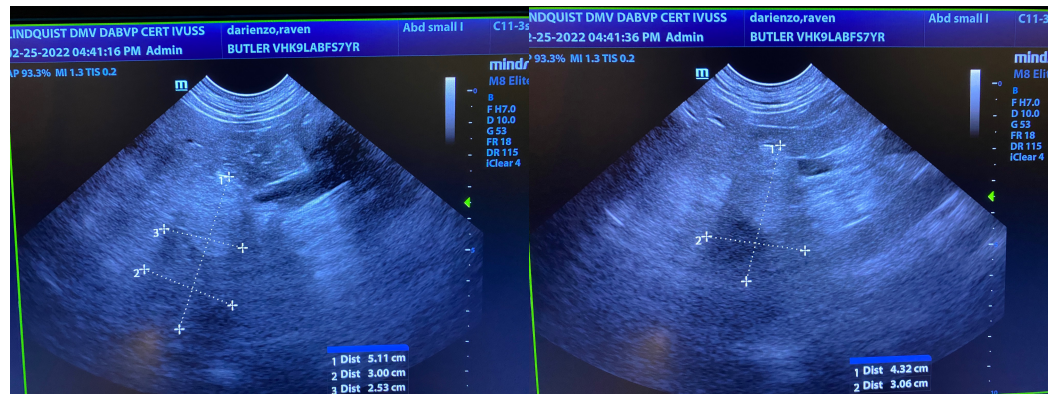
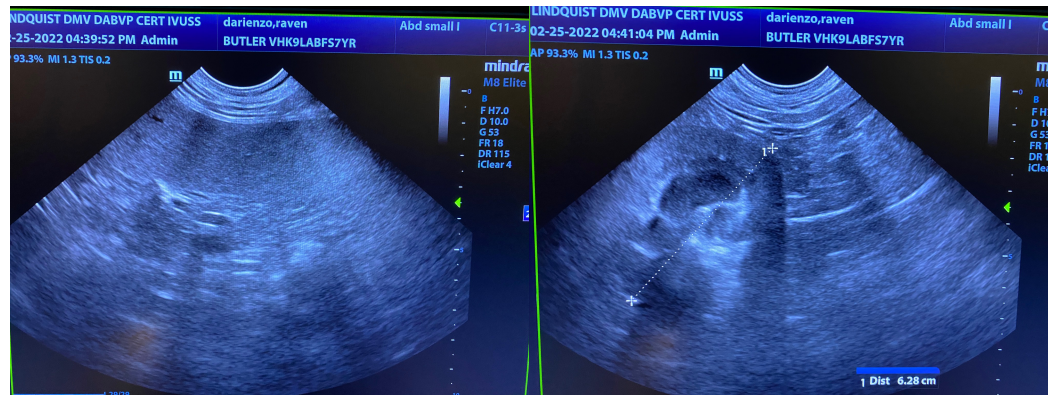
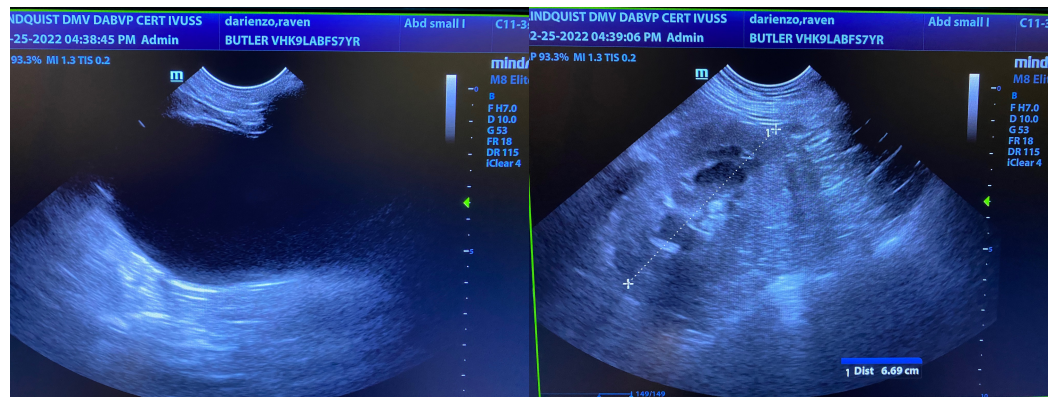
2/25/22

ULTRASONOGRAPHIC FINDINGS

- Right adrenal mass – Strong concern for pheochromocytoma, appears resectable. No evidence of vascular invasion.
- Normal abdomen otherwise

INTERPRETATION OF THE FINDINGS & FURTHER RECOMMENDATIONS

3-view chest radiographs, full CNS examination, blood pressure measurement, and urine catecholamine assessment recommended. Surgical consult indicated.





PATIENT

Raven Darienzo

SPECIES

Canine

BREED

Lab Retriever

SEX

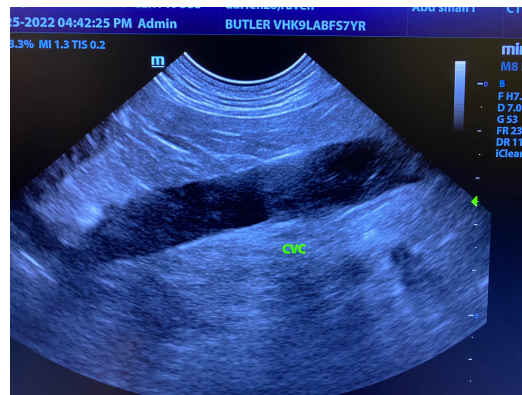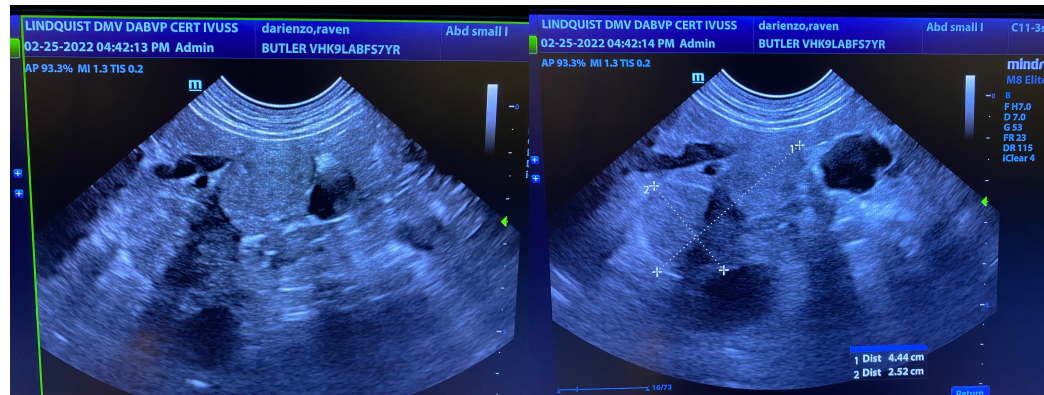
Spayed Female

AGE

7 Years

WEIGHT

74 Pounds



INTERPRETED BY

Eric Lindquist, DMV
DABVP, Cert. IVUSS

IMAGING PERFORMED BY

Eric Lindquist, DMV
DABVP, Cert. IVUSS

HOSPITAL NAME

Butler Vet Hospital

REFERRING VET

Dr. Garro

INVOICE

35906

DATE

2/25/22

The information and recommendations provided are based on the images presented by the referring veterinarian/sonographer. No evaluation can be communicated regarding pathology that was not visible in the image/video clips provided.

Thank you for this referral. If the clinical or image interpretation does not parallel your findings or if I can be of any further assistance please contact me.

Eric Lindquist, DMV, DABVP, Cert. IVUSS, CEO of SonoPath.com

info@SonoPath.com