



## PATIENT

Sam Keilback

## SPECIES

Canine

## BREED

Golden Retriever

## SEX

Neutered male

## AGE

8 years

## WEIGHT

37.3 kg

## INTERPRETED BY

Eric Lindquist, DMV  
DABVP, Cert. IVUSS

## IMAGING PERFORMED BY

Dr. Mariusz  
Chmielinski

## HOSPITAL NAME

Apex VS

## REFERRING VET

Alpine 24/7/ ER Doctor

## INVOICE

71883

## DATE

2/24/26

## PRESENTING CLINICAL SIGNS

- Suspected ingestion of two ankle socks ~4 days prior to presentation. History of prior intestinal foreign body surgery (2018). Began vomiting 2 days ago; last vomiting episode reported 4 days ago (per updated history). Currently eating small frequent meals and passing stool. Activity level normal. No lethargy.
- HR 120 bpm; panting; abdomen non-painful; no palpable distension; bright and responsive. Serial abdominal radiographs show gastric emptying and progression of intestinal contents. Mild intestinal gas present but no significant dilation. Material appears primarily within large intestine. No definitive radiographic evidence of obstruction; partial obstruction cannot be fully ruled out.

## ULTRASONOGRAPHIC EXAMINATION OF THE ABDOMEN

### Urinary System

The **urinary bladder**, trigone, and pelvic urethra presented normal thicknesses and normal tone. The pelvic urethra was imaged 2.0 cm beyond the cystourethral junction and appeared normal. The ureters were not visible which is normal. No uroliths or sediment were visualized and anechoic urine was present. No evidence of inflammatory or neoplastic changes was noted. Ureteral papillae were normal.

The **kidneys** revealed normal size and structure, corticomedullary definition and ratio for this age. The cortices presented largely uniform texture with normal echogenic relationship to liver and spleen. Medullary structure differed distinctly from the cortex and no evidence of pelvic dilation was present. The capsules were acceptably uniform without significant irregularities. The right kidney measured 7.2 cm. The left kidney measured 6.16 cm.

The residual prostate measured 1.3 cm.

### Adrenal Glands

Both **adrenal glands** were visualized and recognized as having normal shape, size, position and echogenicity for this breed. The phrenic vasculature, glandular echogenicity and detail were unremarkable. Capsule, cortex, and medullary definition were normal for this age patient. The left adrenal gland measured 0.41 cm at the cranial pole and 0.58 cm at the caudal pole. The right adrenal gland measured 0.88 cm.

### Spleen

The **spleen** was slightly enlarged and mildly heterogenous.

### Liver

The **liver** images submitted revealed subjectively normal liver size, contour, and structure. Parenchymal echogenicity was naturally coarse and hypoechoic to the spleen. Vascular and biliary tracts were of normal volume with no evidence of congestion. The gallbladder presented acceptably thin walls with



## PATIENT

Sam Keilback

## SPECIES

Canine

## BREED

Golden Retriever

## SEX

Neutered male

## AGE

8 years

## WEIGHT

37.3 kg

## INTERPRETED BY

Eric Lindquist, DMV  
DABVP, Cert. IVUSS

## IMAGING PERFORMED BY

Dr. Mariusz  
Chmielinski

## HOSPITAL NAME

Apex VS

## REFERRING VET

Alpine 24/7/ ER Doctor

## INVOICE

71883

## DATE

2/24/26

primarily anechoic content. The cystic and common bile ducts were normal. No pathological hepatic lymphadenopathy was evident. No overt structural evidence of inflammatory, infiltrative or regenerative pathology was evident.

### ***Gastrointestinal***

The **stomach** in this patient revealed shadowing luminal structure measuring 1.6 cm with acoustic shadowing. This was non-obstructive at the time of the sonogram. A moderate amount of echogenic fluid was noted. Minor, increased submucosal echogenicity and thickness on the gastric wall. The small intestines and colon were unremarkable with normal curvilinear mural patterns and content.

### ***Pancreas***

The base and limbs of the **pancreas** were observed to be largely isoechoic to surrounding omental fat. Pancreatic duct and capsular contour were acceptably normal and parenchyma respected normal curvilinear patterns. No overt evidence of active inflammatory or neoplastic disease was noted.

### **ULTRASONOGRAPHIC FINDINGS**

Gastric fluid with a 1.6 cm shadowing structure. This may represent oral medication such as pill pockets or similar.

Hyperplastic spleen, mild potential for emerging round cell neoplasia.

### **INTERPRETATION OF THE FINDINGS & FURTHER RECOMMENDATIONS**

If any weight loss is an issue then 25-gauge FNA is indicated. There is a mild potential for emerging round cell neoplasia. Endoscopy is likely in this patient's best interest given the global sonographic presentation and clinical history to obtain GI biopsies and investigate the luminal structure. The remainder of the abdomen is largely unremarkable other than minor splenic enlargement.



### PATIENT

Sam Keilback

### SPECIES

Canine

### BREED

Golden Retriever

### SEX

Neutered male

### AGE

8 years

### WEIGHT

37.3 kg

### INTERPRETED BY

Eric Lindquist, DMV  
DABVP, Cert. IVUSS

### IMAGING PERFORMED BY

Dr. Mariusz  
Chmielinski

### HOSPITAL NAME

Apex VS

### REFERRING VET

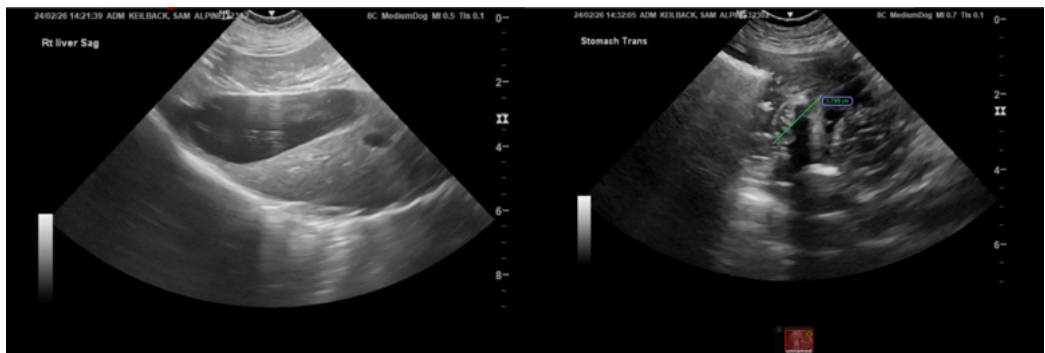
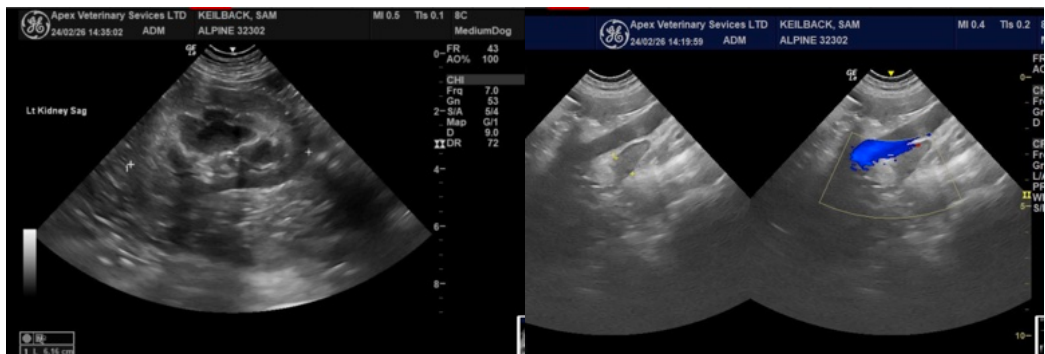
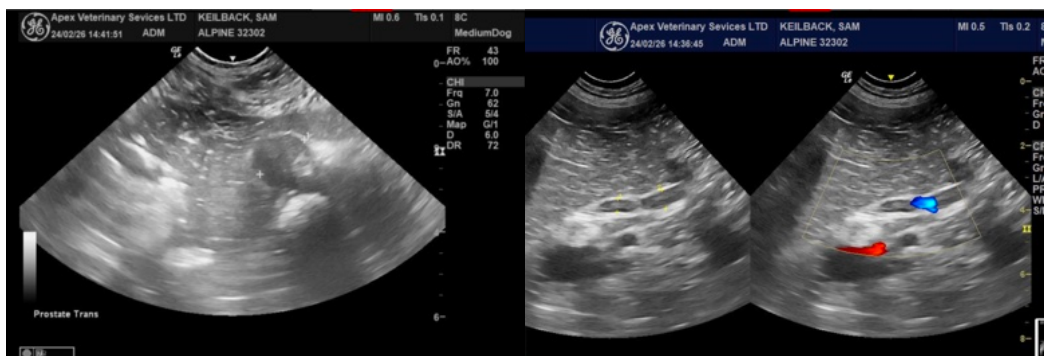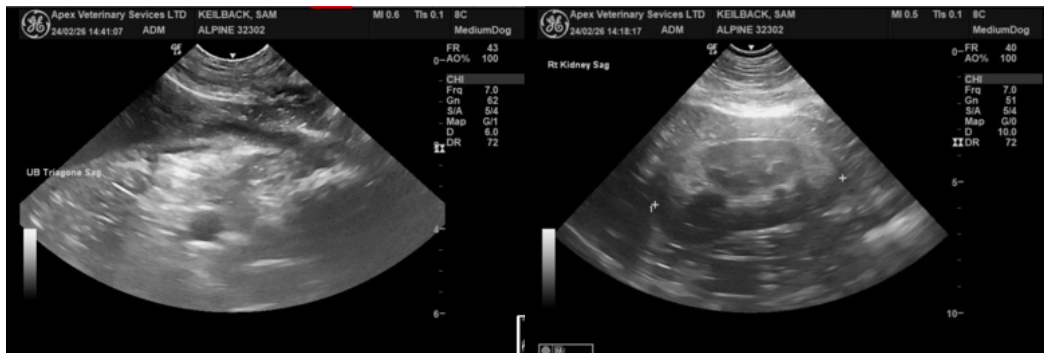
Alpine 24/7/ ER Doctor

### INVOICE

71883

### DATE

2/24/26





## PATIENT

Sam Keilback

## SPECIES

Canine

## BREED

Golden Retriever

## SEX

Neutered male

## AGE

8 years

## WEIGHT

37.3 kg

## INTERPRETED BY

Eric Lindquist, DMV  
DABVP, Cert. IVUSS

## IMAGING PERFORMED BY

Dr. Mariusz  
Chmielinski

## HOSPITAL NAME

Apex VS

## REFERRING VET

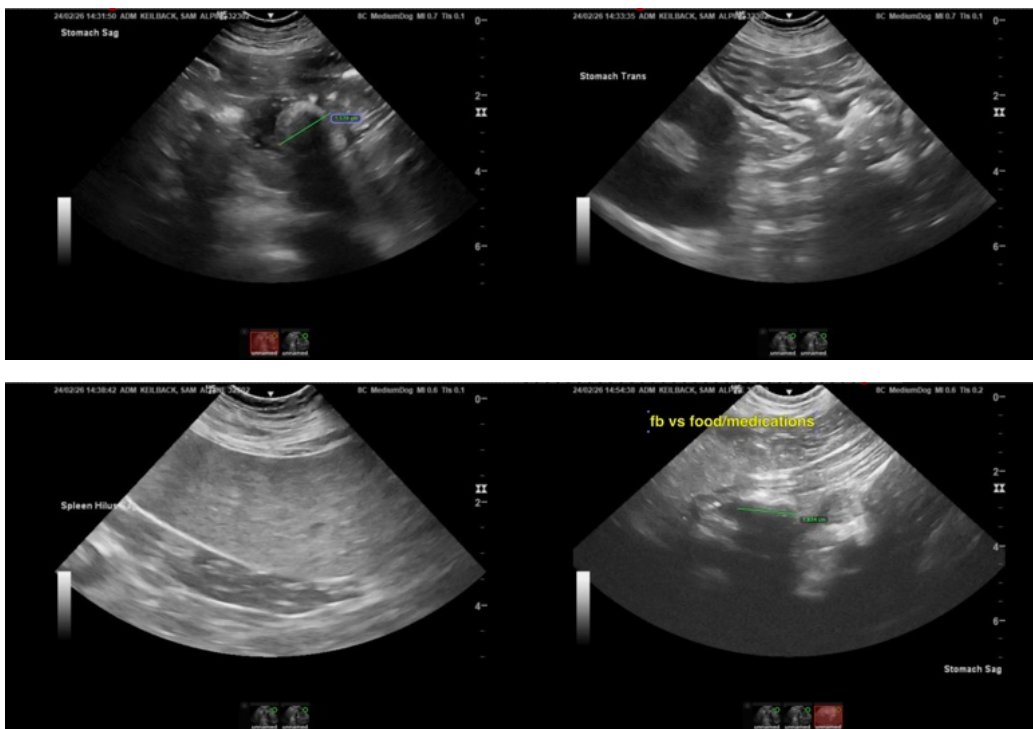
Alpine 24/7/ ER Doctor

## INVOICE

71883

## DATE

2/24/26



The information and recommendations provided are based on the images presented by the referring veterinarian/sonographer. No evaluation can be communicated regarding pathology that was not visible in the image/video clips provided.

Thank you for this referral. If the clinical or image interpretation does not parallel your findings or if I can be of any further assistance please contact me.

Eric Lindquist, DMV, DABVP (CFM), Cert. IVUSS, CEO of SonoPath.com

[info@SonoPath.com](mailto:info@SonoPath.com)