



PATIENT

Izzy Haugsdal

SPECIES

Canine

BREED

Pug

SEX

Spayed female

AGE

5 years

WEIGHT

27 lbs

INTERPRETED BY

Eric Lindquist, DMV
DABVP, Cert. IVUSS

IMAGING PERFORMED BY

Dr. Raul Casas

HOSPITAL NAME

State Ave VC

REFERRING VET

Dr. Casas

INVOICE

71828

DATE

2/24/26

PRESENTING CLINICAL SIGNS

- Referral from Dakota Prairie Veterinary Service
- Presents for CT of head, neck, and thorax to evaluate palpable masses.
- Occasional vomiting (a few episodes, not recent). Occasional coughing/sneezing; described as "talking a lot" or clearing throat. No dysphagia; swallowing normal.
- Pending Thyroid Panel 4-Canine, CT of head, neck and chest, FNA and Pocket Path reports
- 2 firm masses on neck:
 - one is craniocaudally, longitudinally oriented on the R side of the proximal neck; seems attached; no pain on palpation; homogeneous on US
 - one is horizontally oriented on the ventral aspect of the proximal neck; more mobile than the one on the R side but potentially attached as well; homogeneous on US

ULTRASONOGRAPHIC EXAMINATION

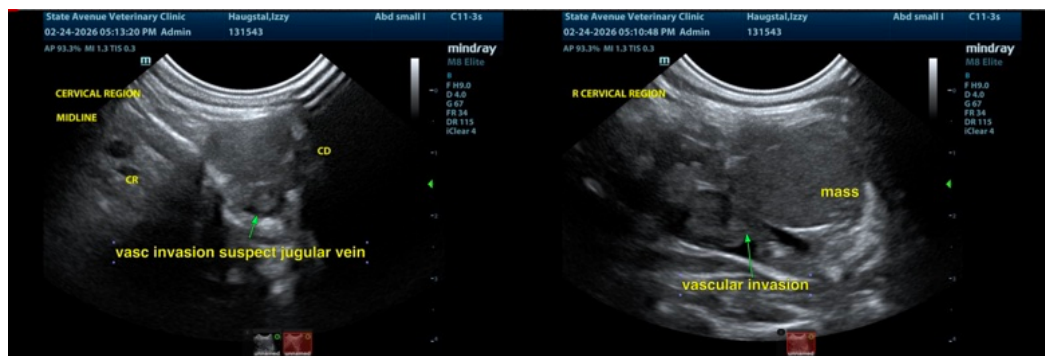
Five still images and 13 videos were submitted in this patient. The right cervical region revealed a 2.8 x 1.8 cm mass that extended medially into a nodular change that measured 1.3 cm and appears to have vascular invasion of a region of 1.0 cm that appears to be the jugular vein. This mass is non-resectable. Given the extension into the regional tissues and blood vessels that mass is significantly undifferentiated and vascular. The pattern would suggest carcinoma and the position would suggest thyroid origin.

ULTRASONOGRAPHIC FINDINGS

Irregular, non-resectable invasive mass in the right cervical midline region. Suspect thyroid carcinoma.

INTERPRETATION OF THE FINDINGS & FURTHER RECOMMENDATIONS

25-gauge FNA of the mass as well as evaluation of the extent of the mass through CT would be appropriate.





PATIENT

Izzy Haugsdal

SPECIES

Canine

BREED

Pug

SEX

Spayed female

AGE

5 years

WEIGHT

27 lbs

INTERPRETED BY

Eric Lindquist, DMV
DABVP, Cert. IVUSS

IMAGING PERFORMED BY

Dr. Raul Casas

HOSPITAL NAME

State Ave VC

REFERRING VET

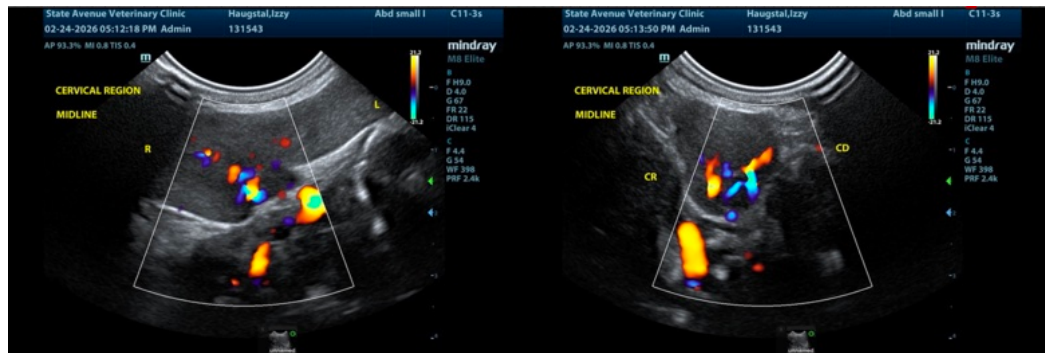
Dr. Casas

INVOICE

71828

DATE

2/24/26



The information and recommendations provided are based on the images presented by the referring veterinarian/sonographer. No evaluation can be communicated regarding pathology that was not visible in the image/video clips provided.

Thank you for this referral. If the clinical or image interpretation does not parallel your findings or if I can be of any further assistance please contact me.

Eric Lindquist, DMV, DABVP (CFM), Cert. IVUSS, CEO of SonoPath.com

info@SonoPath.com