

PATIENT

Murphy McCambridge

SPECIES

Canine

BREED

Labrador Retriever

SEX

Intact Male

AGE

11 Months

WEIGHT

78.7 Pounds

PRESENTING CLINICAL SIGNS

History: Soft large fluctuant swelling in region of left salivary gland. Patient was lunging heavily on Martingale collar. Investigate case of swelling. Suspect sialoceles secondary to trauma.

LIMITED ULTRASONOGRAPHIC EXAMINATION

The left cervical region was imaged in this patient. An approximately 5.0 cm x 3.0 cm cystic structure was noted in the region of the left submandibular salivary gland. Areas of mineralization were noted with tissue proliferation, measuring 2.0 cm x 1.0 cm. This is likely dystrophic mineralization owing to a chronic inflammatory component, however, underlying foreign matter cannot be completely ruled out. Other regional tissues were unremarkable. The pathology appears to be well encapsulated. Ultrasound guided FNA of the mineralizing parenchyma would be warranted to ensure an aberrant carcinoma is not present. Multiple other calculi were noted in the parenchyma.

ULTRASONOGRAPHIC FINDINGS

- Salivary mineralization and sialoceles, sialolithiasis

INTERPRETATION OF THE FINDINGS & FURTHER RECOMMENDATIONS

Surgical intervention with removal of the salivary gland or drainage and curettage would be appropriate. Surgical consult is recommended. Drainage of the cystic portion, as well as FNA of the parenchymal portion of the pathology may also be appropriate. The mineralization would suggest chronic inflammation with possible acute on chronic presentation or underlying sialolithiasis as a primary cause of the sialoceles.

INTERPRETED BY

Eric Lindquist, DMV, DABVP, Cert. IVUS

HOSPITAL NAME

West Hills AH

REFERRING VET

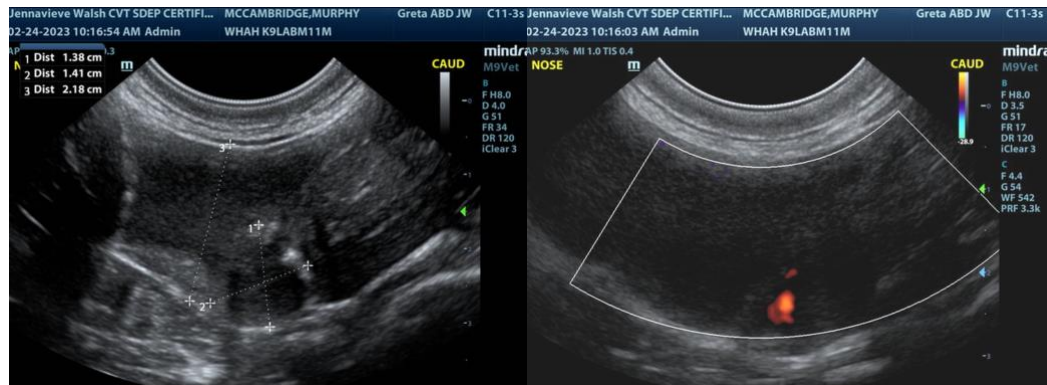
Dr. Glaze

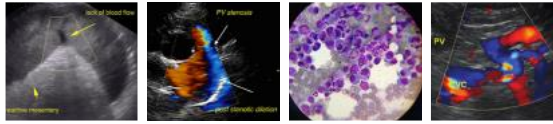
INVOICE NUMBER

21259

DATE

2/24/23





PATIENT

Murphy McCambridge

SPECIES

Canine

BREED

Labrador Retriever

SEX

Intact Male

AGE

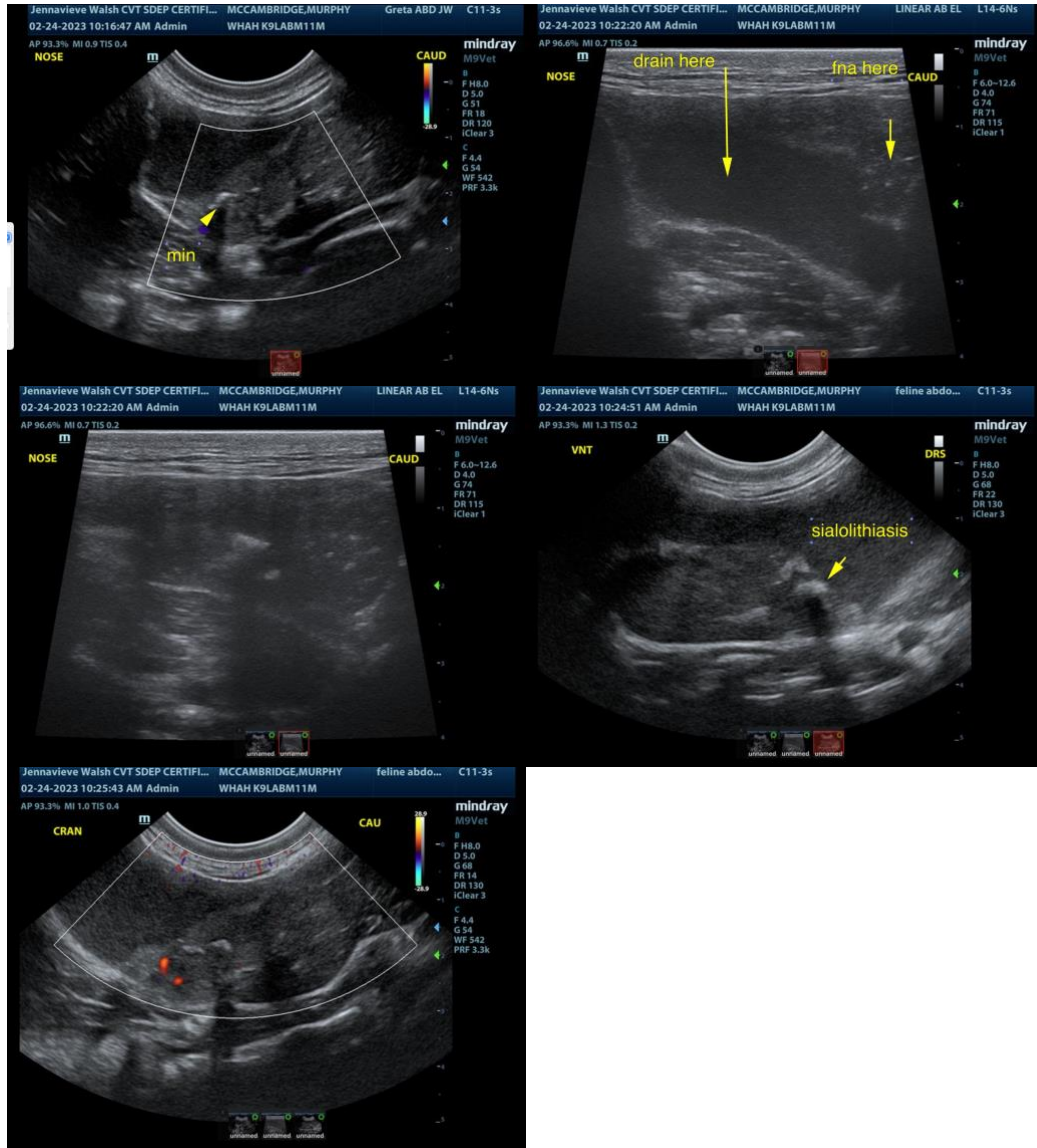
11 Months

WEIGHT

78.7 Pounds

INTERPRETED BY

Eric Lindquist, DMV,
DABVP, Cert. IVUSS



HOSPITAL NAME

West Hills AH

The information and recommendations provided are based on the images presented by the referring veterinarian. No evaluation can be communicated regarding pathology that was not visible in the image/video clips provided.

REFERRING VET

Dr. Glaze

Thank you for this referral. If the clinical or image interpretation does not parallel your findings or if I can be of any further assistance please contact me.

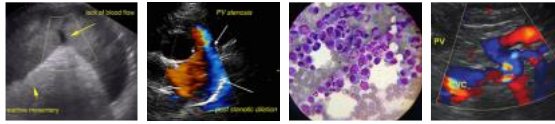
Eric Lindquist, DMV, DABVP, Cert. IVUSS, CEO of SonoPath.com
Eric.Lindquist@SonoPath.com

INVOICE NUMBER

21259

DATE

2/24/23



PATIENT

Murphy McCambridge

SPECIES

Canine

BREED

Labrador Retriever

SEX

Intact Male

AGE

11 Months

WEIGHT

78.7 Pounds

INTERPRETED BY

Eric Lindquist, DMV,
DABVP, Cert. IVUSS

HOSPITAL NAME

West Hills AH

REFERRING VET

Dr. Glaze

INVOICE NUMBER

21259

DATE

2/24/23