



PATIENT

Mackenzie Domsky

SPECIES

Canine

BREED

Mix

SEX

Spayed Female

AGE

2 years

WEIGHT

46 lbs

INTERPRETED BY

Eric Lindquist, DMV, DABVP, Cert. IVUSS, CEO of SonoPath.com

IMAGING PERFORMED BY

Kelly Vazquez, CVT

HOSPITAL NAME

Well Pet AH

REFERRING VET

Dr. Wellington

INVOICE

96312

DATE

2/24/22

PRESENTING CLINICAL SIGNS

Newly auscultated heart murmur.

ULTRASONOGRAPHIC EXAMINATION OF THE HEART

The echocardiogram in this patient demonstrated normal **left atrial** size based on 3 separate methods of LA evaluation. The cranial and caudal **mitral** valve leaflets presented normal linear structure, extension in systole, and union in diastole with normal kinesis. The **left ventricle** presented thicknesses with linear contour and was not dilated nor restricted. The **myocardium** presented normal echogenicity without subjective evidence of significant fibrotic or ischemic disease. **Contractility** of the ventricular walls was adequate and in normal range for this patient evidenced by the fractional shortening measurement and subjective evaluation of the different regions of the myocardium. The **left ventricular outflow** tract demonstrated normal laminar flow and subjective structural integrity. The **right atrium** and auricle revealed normal size, structure and content. No evidence of masses was noted. Trivial **tricuspid** insufficiency was noted at 1.2 m/sec. The **right ventricle** was of normal size (1/3 diameter of LV), chordae structure, myocardial echogenicity and thickness. **Pulmonary outflow** tract assessment revealed normal valve structure, laminar flow, and diameter (approx.1:1 pa/ao ratio). No visible **pericardial** or free pleura fluid was noted. The cranial **mediastinum** and **pericardial and extra-cardiac** regions were free of masses in the visible window.

CANINE CARDIAC PARAMETERS	MR VMAX (m/s)	TR VMAX (m/s)	LA/AO (Boon method)	LA/AO (Heart Base; Swe)	FS (%)	EF (%)	EPSS (cm)
NORMAL PARAMETER	4.5-5.5	<2.7	1.3	<1.6	28-40	40-100	<0.6
PATIENT			NM	1.3	30	58	NM
CANINE CARDIAC PARAMETERS	HR (BPM)	AV VMAX (m/s)	PV MAX (m/s)	BODY WEIGHT	LA (2D short axis Base view) (cm)	LVIDd (Avg; 2D and m-mode short axis) (cm)	LVIDs (Avg; 2D and m-mode short axis) (cm)
NORMAL PARAMETER	50-100	0.7-1.7	0.7-1.6				
PATIENT	114	1.74	1.25	46 lbs	2.8 max	3.54	

ULTRASONOGRAPHIC FINDINGS

Normal echocardiogram.

INTERPRETATION OF THE FINDINGS & FURTHER RECOMMENDATIONS

There is no perceivable flow turbulence. Laminar flow was normal throughout the heart. There is no evidence of congenital disease. Idiopathic flow murmur is likely. If the murmur grade increases or is



PATIENT

persistent a recheck echocardiogram is recommended in a year. Idiopathic flow murmurs can occur with volume shifts and excitement.

Mackenzie Domsky

SPECIES

Canine

BREED

Mix

SEX

Spayed Female

AGE

2 years

WEIGHT

46 lbs

INTERPRETED BY

Eric Lindquist, DMV,
DABVP, Cert. IVUSS,
CEO of SonoPath.com

IMAGING PERFORMED BY

Kelly Vazquez, CVT

HOSPITAL NAME

Well Pet AH

REFERRING VET

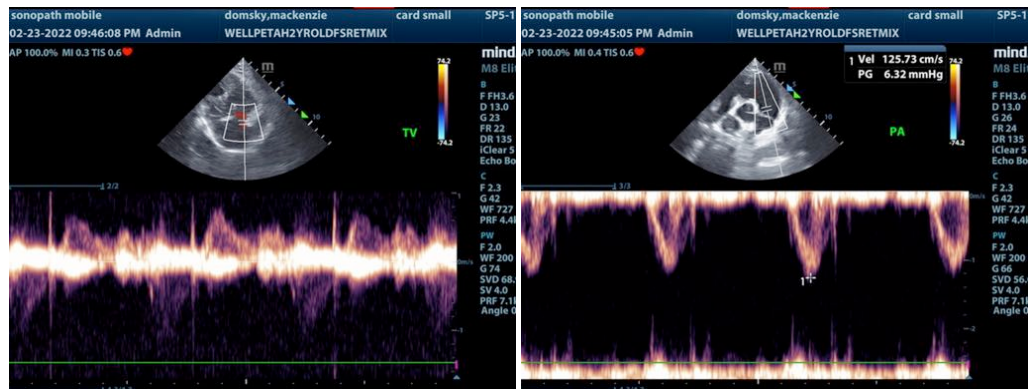
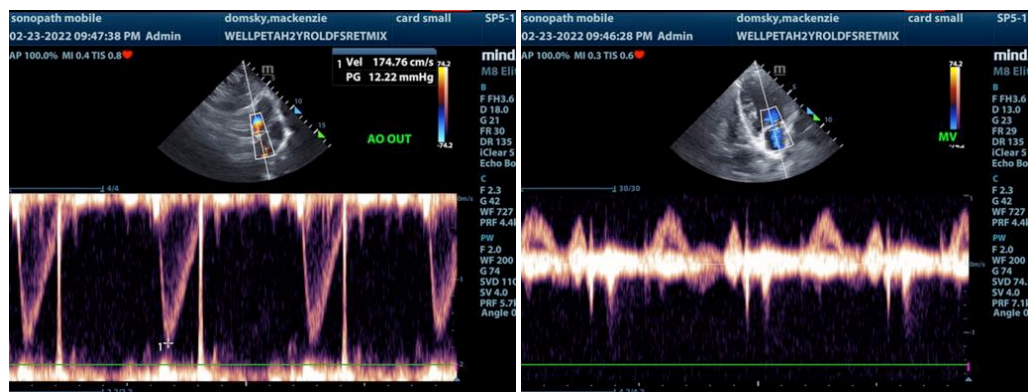
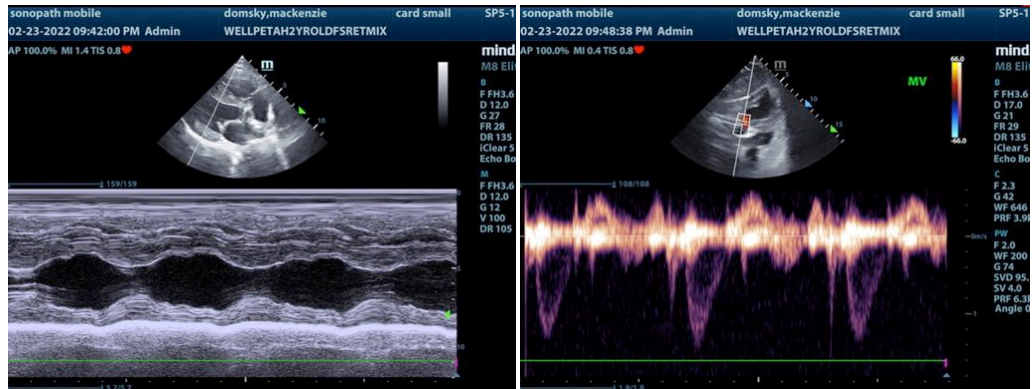
Dr. Wellington

INVOICE

96312

DATE

2/24/22





PATIENT

Mackenzie Domsky

SPECIES

Canine

BREED

Mix

SEX

Spayed Female

AGE

2 years

WEIGHT

46 lbs

INTERPRETED BY

Eric Lindquist, DMV, DABVP, Cert. IVUSS, CEO of SonoPath.com

IMAGING PERFORMED BY

Kelly Vazquez, CVT

HOSPITAL NAME

Well Pet AH

REFERRING VET

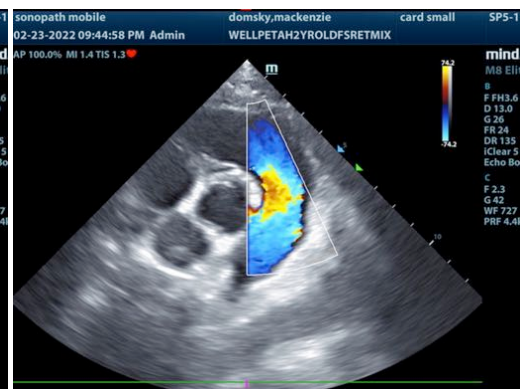
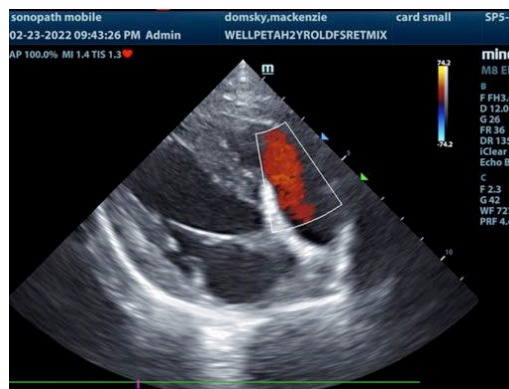
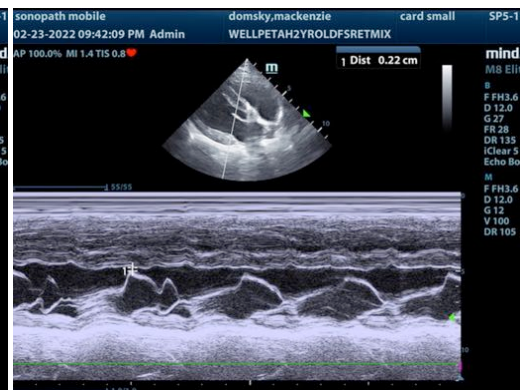
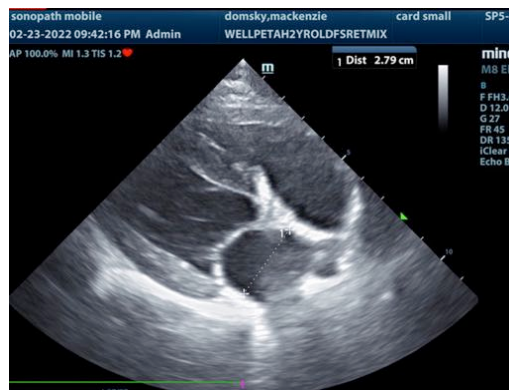
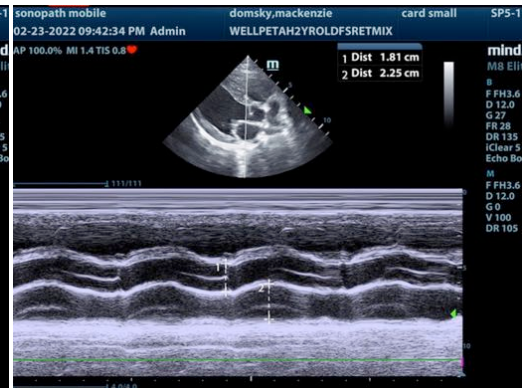
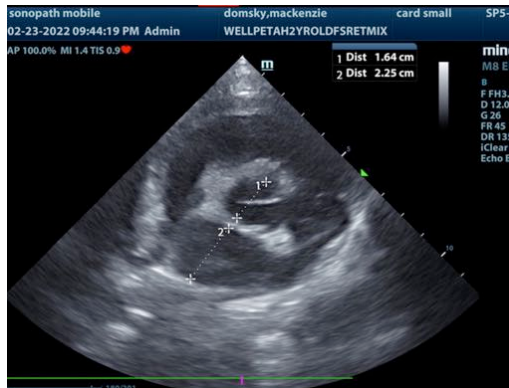
Dr. Wellington

INVOICE

96312

DATE

2/24/22



The information and recommendations provided are based on the images presented by the referring veterinarian/sonographer. No evaluation can be communicated regarding pathology that was not visible in the image/video clips provided.

Thank you for this referral. If the clinical or image interpretation does not parallel your findings or if I can be of any further assistance please contact me.

Eric Lindquist, DMV, DABVP, Cert. IVUSS, CEO of SonoPath.com

Info@SonoPath.com



PATIENT

Mackenzie Domsky

SPECIES

Canine

BREED

Mix

SEX

Spayed Female

AGE

2 years

WEIGHT

46 lbs

INTERPRETED BY

Eric Lindquist, DMV,
DABVP, Cert. IVUSS,
CEO of SonoPath.com

**IMAGING
PERFORMED BY**

Kelly Vazquez, CVT

HOSPITAL NAME

Well Pet AH

REFERRING VET

Dr. Wellington

INVOICE

96312

DATE

2/24/22