



PATIENT

Blue VanVlear

SPECIES

Feline

BREED

Domestic Shorthair

SEX

Neutered male

AGE

18 years

WEIGHT

10.4 lbs

PRESENTING CLINICAL SIGNS

pre anesthesia evaluation in anticipation of COHAT. No clinical signs of heart disease. Abnormal PE/Chem/CBC/UA Results: Grade iii/vi left parasternal systolic murmur. Thoracic radiographs show moderate cardiomegaly, no pulmonary parenchymal abnormalities. No significant abnormalities on CBC, chemistry, T4

ULTRASONOGRAPHIC EXAMINATION OF THE HEART

The echocardiogram in this patient demonstrated normal **left atrial** size based on 3 separate LA measurements. The **mitral** valve revealed minor insufficiency, not clinically significant at this time. The **left ventricle** presented normal thicknesses with linear contour and was not dilated nor restricted. The **myocardium** presented normal echogenicity without subjective evidence of significant fibrotic or ischemic disease. **Contractility** of the ventricular walls was adequate and in normal range for this patient evidenced by the fractional shortening measurement and subjective evaluation of the different regions and angles of the myocardium. The **left ventricular outflow** tract demonstrated normal laminar flow and subjective structural integrity. The **right atrium** and auricle revealed normal size, structure and content. No evidence of masses was noted or chamber overload. **Tricuspid** valvular assessment demonstrated adequate linear morphology and kinetics. The **right ventricle** was of normal size (1/3 diameter of LV), chordae structure, myocardial echogenicity and thickness. **Pulmonic** tract assessment revealed normal valve structure, laminar flow, and diameter (approx.1:1 pa/ao ratio). No visible **pericardial** or free pleura fluid was noted or extra cardiac pathology in the visible planes. The cranial **mediastinum** and **pericardial regions** were free of masses in the visible window.

INTERPRETED BY

Eric Lindquist, DMV
DABVP, Cert. IVUSS

IMAGING PERFORMED BY

Dr. Green

HOSPITAL NAME

Healing Spirit AW

REFERRING VET

Dr. Green

INVOICE

96332

DATE

2/24/22

| FELINE CARDIAC PARAMETERS | BODY WEIGHT (kg) | HR (BPM) | IVSd (cm) | LVIDd (cm) | LVWd (cm) | FS (%) | EF (%) |
|--|------------------|---------------------------|--|-----------------|-----------------|----------|--------|
| NORMAL PARAMETER | ----- | 150-240 | 0.3-0.6 | 1.0-2.1 | 0.25-0.6 | 35-67 | 80-100 |
| PATIENT | | NM | 0.55 | 1.2 | 0.55 | 55 | |
| FELINE CARDIAC PARAMETERS | LA/AO (Boon) | LA/AO HEART BASE (Sisson) | LA 2D 4-chamber long axis AS to FW (Sisson) (cm) | LVOT VEL. (m/s) | RVOT VEL. (m/s) | IVRT (m) | |
| NORMAL PARAMETER | <1.5 | 0.88-1.79 | 0.7-1.7 | <1.6 | <1.3 | 40-60 | |
| PATIENT | 1.1 | 1.3 | 1.3 | | | | NM |
| Adapted from June Boon, Veterinary Echocardiography, 1998 Sisson D et al. JVIM 1991; 5: 232, Jacobs et al. Am J Vet Res 1985; 46:1705 | | | | | | | |



PATIENT

Blue VanVlear

SPECIES

Feline

BREED

Domestic Shorthair

SEX

Neutered male

AGE

18 years

WEIGHT

10.4 lbs

INTERPRETED BY

Eric Lindquist, DMV
DABVP, Cert. IVUSS

IMAGING PERFORMED BY

Dr. Green

HOSPITAL NAME

Healing Spirit AW

REFERRING VET

Dr. Green

INVOICE

96332

DATE

2/24/22

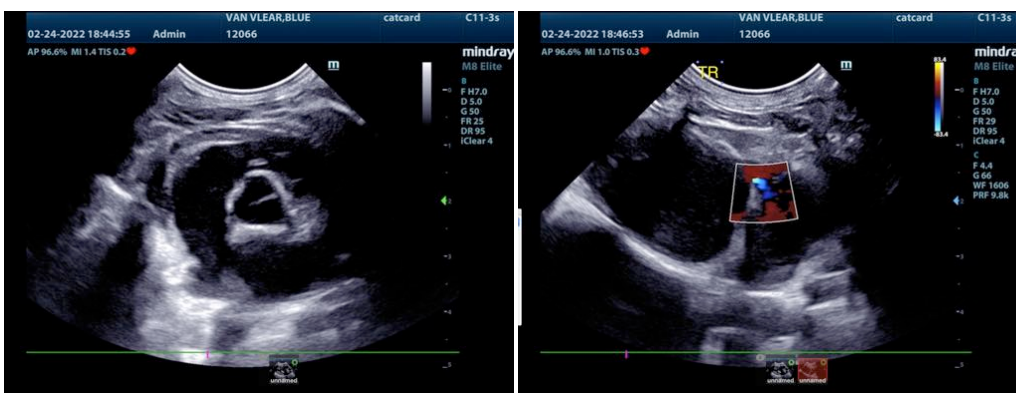
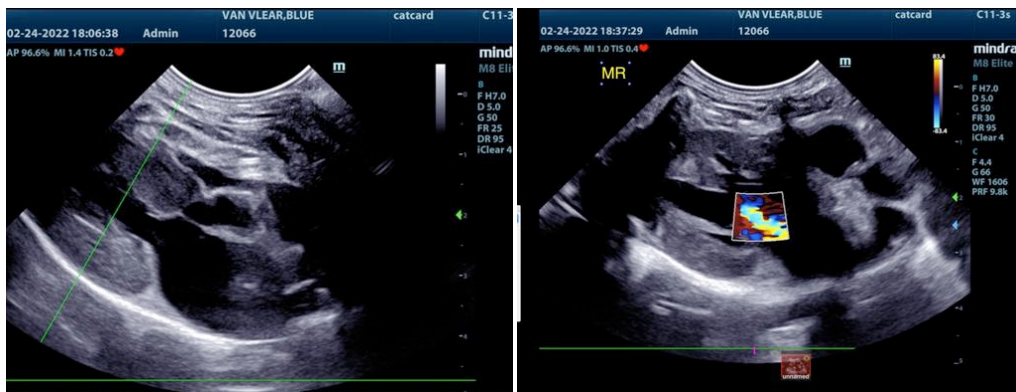
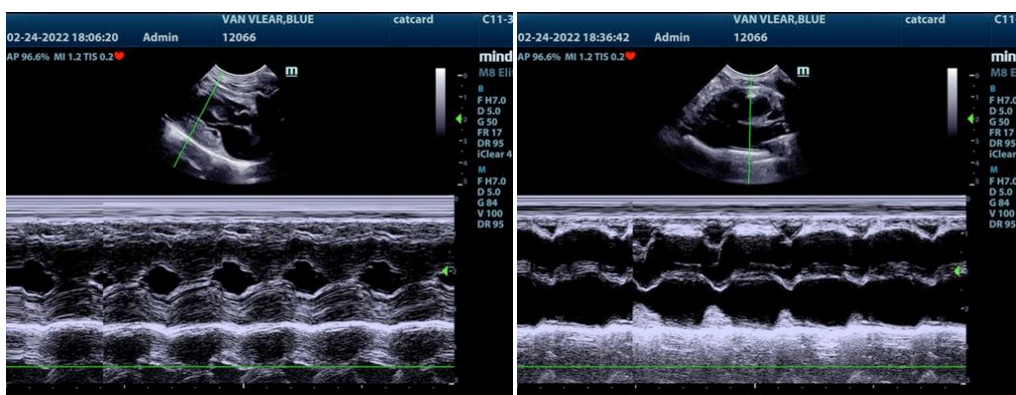
ULTRASONOGRAPHIC FINDINGS

Minor mitral and tricuspid insufficiency, not clinically significant.

Otherwise, normal heart.

INTERPRETATION OF THE FINDINGS & FURTHER RECOMMENDATIONS

No therapy is recommended.





PATIENT

Blue VanVlear

SPECIES

Feline

BREED

Domestic Shorthair

SEX

Neutered male

AGE

18 years

WEIGHT

10.4 lbs

INTERPRETED BY

Eric Lindquist, DMV
DABVP, Cert. IVUSS

IMAGING PERFORMED BY

Dr. Green

HOSPITAL NAME

Healing Spirit AW

REFERRING VET

Dr. Green

INVOICE

96332

DATE

2/24/22

The information and recommendations provided are based on the images presented by the referring veterinarian/sonographer. No evaluation can be communicated regarding pathology that was not visible in the image/video clips provided.

Thank you for this referral. If the clinical or image interpretation does not parallel your findings or if I can be of any further assistance please contact me.

Eric Lindquist, DMV, DABVP, Cert. IVUSS, CEO of SonoPath.com
info@SonoPath.com