



PATIENT

Bowie Paassante

SPECIES

Feline

BREED

Domestic Shorthair

SEX

Neutered male

AGE

2 years

WEIGHT

12 lbs

INTERPRETED BY

Eric Lindquist, DMV
DABVP, Cert. IVUSS

IMAGING PERFORMED BY

Kathleen Laux

HOSPITAL NAME

Rondout Valley VA

REFERRING VET

Dr. Laux

INVOICE

71797

DATE

2/23/26

PRESENTING CLINICAL SIGNS

- Has not been eating or drinking since Saturday. Has another cat so cannot comment on urinating and defecating behavior. Difficult to find bladder on exam so had initial concern about a ruptured bladder
- mild temp elevation 102.8
- Gluc 228 K 3.3

ULTRASONOGRAPHIC EXAMINATION OF THE ABDOMEN

Urinary System

The **urinary bladder**, trigone, and pelvic urethra presented normal thicknesses and normal tone. The ureters were not visible which is normal. A mild amount of debris was noted. No evidence of inflammatory or neoplastic changes was noted. Ureteral papillae were normal.

The **kidneys** revealed normal size and structure, corticomedullary definition and ratio for this age. The cortices presented largely uniform texture with normal echogenic relationship to liver and spleen. Medullary structure differed distinctly from the cortex and no evidence of pelvic dilation was present. The capsules were acceptably uniform without significant irregularities. The right kidney measured 4.3 cm. The left kidney measured 4.4 cm.

Adrenal Glands

Both **adrenal glands** were visualized and recognized as having normal shape, size, position and echogenicity for this breed. The phrenic vasculature, glandular echogenicity and detail were unremarkable. Capsule, cortex, and medullary definition were normal for this age patient. The right adrenal gland measured 0.28 cm. The left adrenal gland measured 0.28 cm.

Spleen

The **spleen** presented a smooth homogeneous parenchyma hyperechoic to liver and renal cortical parenchyma. The capsule was smooth without noticeable expansion or deviation from within the spleen or adjacent pathology. The splenic vasculature demonstrated normal volume without signs of congestion or thrombosis. No sonographic evidence of acute or chronic inflammatory, neoplastic, or infarctual changes was noted.

Liver

The **liver** images submitted revealed subjectively normal liver size, contour, and structure. Parenchymal echogenicity was naturally coarse and hypoechoic to the spleen. Vascular and biliary tracts were of normal volume with no evidence of congestion. The gallbladder presented acceptably thin walls with primarily anechoic content. The cystic and common bile ducts were normal. No pathological hepatic lymphadenopathy was evident. No overt structural evidence of inflammatory, infiltrative or regenerative pathology was evident.



PATIENT

Bowie Paassante

SPECIES

Feline

BREED

Domestic Shorthair

SEX

Neutered male

AGE

2 years

WEIGHT

12 lbs

INTERPRETED BY

Eric Lindquist, DMV
DABVP, Cert. IVUSS

IMAGING PERFORMED BY

Kathleen Laux

HOSPITAL NAME

Rondout Valley VA

REFERRING VET

Dr. Laux

INVOICE

71797

DATE

2/23/26

Gastrointestinal

Examination of the **gastrointestinal tract** revealed a stomach and intestine free of stasis, of normal wall thickness, acceptable curvilinear mural detail, and peristaltic activity. Minor fluid gastric lumen was noted. Small and large intestine demonstrated normal luminal chyme and stool consistency respectively. No obstructive or overt infiltrative disease was noted. No associated abnormal lymphatic activity was noted.

Pancreas

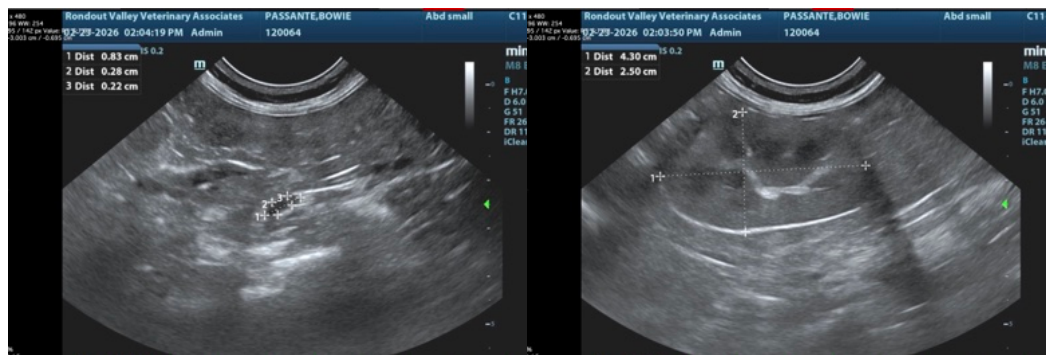
The base and limbs of the **pancreas** were observed to be largely isoechoic to surrounding omental fat. Pancreatic duct and capsular contour were acceptably normal and parenchyma respected normal curvilinear patterns. No overt evidence of active inflammatory or neoplastic disease was noted.

ULTRASONOGRAPHIC FINDINGS

Structurally unremarkable abdomen.

INTERPRETATION OF THE FINDINGS & FURTHER RECOMMENDATIONS

General urinalysis screening is indicated. I recommend monitoring urine production as the bladder was empty, yet there was no evidence of rupture or free fluid in the abdomen. GI protectant protocol is warranted for gastric irritation given the fluid filled lumen. There was no evidence of structural disease within the stomach and small intestine. Other cause of hyporexia or anorexia such as orthopedic pain, CNS or thoracic disease should all be considered.





PATIENT

Bowie Paassante

SPECIES

Feline

BREED

Domestic Shorthair

SEX

Neutered male

AGE

2 years

WEIGHT

12 lbs

INTERPRETED BY

Eric Lindquist, DMV
DABVP, Cert. IVUSS

IMAGING PERFORMED BY

Kathleen Laux

HOSPITAL NAME

Rondout Valley VA

REFERRING VET

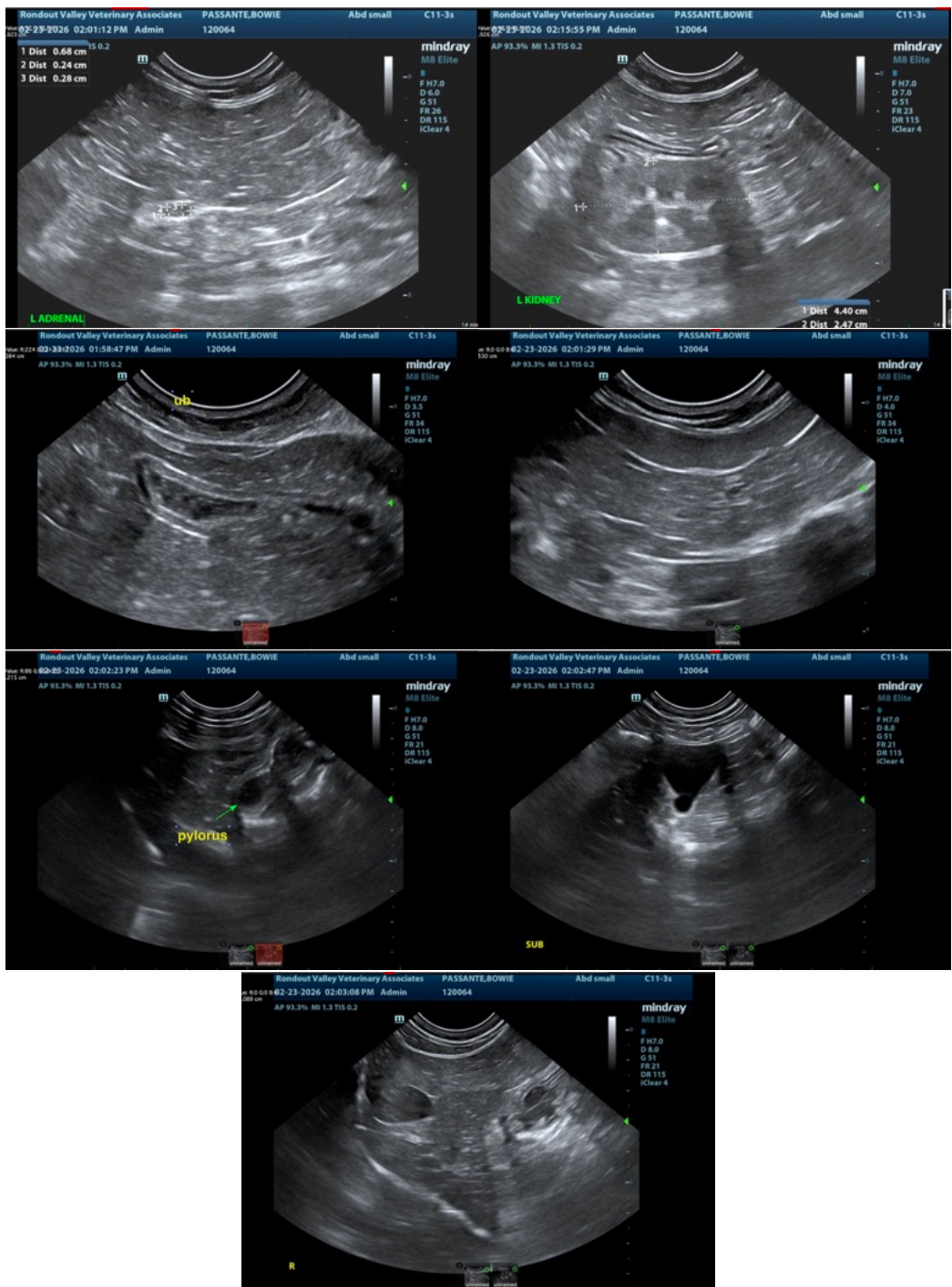
Dr. Laux

INVOICE

71797

DATE

2/23/26



The information and recommendations provided are based on the images presented by the referring veterinarian/sonographer. No evaluation can be communicated regarding pathology that was not visible in the image/video clips provided.

Thank you for this referral. If the clinical or image interpretation does not parallel your findings or if I



PATIENT

Bowie Paassante

SPECIES

Feline

BREED

Domestic Shorthair

SEX

Neutered male

AGE

2 years

WEIGHT

12 lbs

INTERPRETED BY

Eric Lindquist, DMV
DABVP, Cert. IVUSS

**IMAGING
PERFORMED BY**

Kathleen Laux

HOSPITAL NAME

Rondout Valley VA

REFERRING VET

Dr. Laux

INVOICE

71797

DATE

2/23/26

can be of any further assistance please contact me.

Eric Lindquist, DMV, DABVP (CFM), Cert. IVUSS, CEO of SonoPath.com

info@SonoPath.com