



PATIENT

Ryder Powers

SPECIES

Canine

BREED

Labrador Retriever

SEX

Neutered male

AGE

11 years

WEIGHT

91.3 lbs

INTERPRETED BY

Eric Lindquist, DMV
DABVP, Cert. IVUSS

IMAGING PERFORMED BY

Dr. Striano-Kaplan

HOSPITAL NAME

Ramsey VH

REFERRING VET

Dr. Striano-Kaplan

INVOICE

42941

DATE

2/23/23

PRESENTING CLINICAL SIGNS

History: Pt presented as new patient second opinion. O has had pet for about 3 years. growth on LH and growth behind AS, have been there for months, both increased in size and and growth behind the left ear has ulcerated and broken open new growth on LH, O noted a few days ago e & d fine, sleeps a lot, no c/s/v per O pet's stool has always been soft and yellow mobility is okay, no overt lameness, generalized stiffness with suspected OA of coxofemoral joints

Abnormal PE/Chem/CBC/UA Results: Large ulcerated growth behind left ear ~3cm, ~1.5cm cutaneous mass over left tarsi; tense abdomen, very deep chested difficult to palpate cranial abdominal organs 3view thorax, 3 view abdomen - 8.4cmx7.7cm mid to cranial abdominal mass Phosphorous: 2.2L

ULTRASONOGRAPHIC EXAMINATION OF THE ABDOMEN

Urinary System

The **urinary bladder** and visible pelvic urethra were unremarkable for the level of repletion presented. The urine, however, did present some mildly echogenic debris consistent with mucous, exfoliated cells from renal or bladder origin, and/or blood clots as these echogenic changes can all present similarly. This is often related to urinary tract infection but may represent simple evidence of exfoliated debris or sterile inflammation. Cystocentesis, urinalysis, +/- culture would be recommended to rule out and define any UTI.

The **kidneys** revealed normal size and structure, corticomedullary definition and ratio for this age. The cortices presented largely uniform texture with normal echogenic relationship to liver and spleen. Medullary structure differed distinctly from the cortex and no evidence of pelvic dilation was present. The capsules were acceptably uniform without significant irregularities. The left kidney measured 7.08 cm. The right kidney measured 8.85 cm.

Adrenal Glands

The left **adrenal gland** was uniform and measured 0.6 cm. The right adrenal gland was visualized and slightly heterogenous in the cranial pole.

Spleen

The **spleen** revealed a hyperechoic lipogranulomatous changes with a mass deriving from the cranial pole. Hyperechoic lipogranulomatous changes were noted. A mixed echogenic cavitated mass was noted deriving from the cranial body. There was no evidence of rupture; however, it is precarious and should be removed as soon as possible. The mass measured approximately 5.0 x 7.0 cm.

Liver

The right **liver** appeared unremarkable. However, the left liver revealed multiple, cystic changes and irregular swelling. Technically the left liver comprises a mass; however, this may be benign. This should be inspected and biopsied at the time of surgery.



PATIENT

Ryder Powers

SPECIES

Canine

BREED

Labrador Retriever

SEX

Neutered male

AGE

11 years

WEIGHT

91.3 lbs

Gastrointestinal

Examination of the **gastrointestinal tract** revealed a stomach and intestine free of stasis, of normal wall thickness, acceptable curvilinear mural detail, and peristaltic activity. Small and large intestine demonstrated normal luminal chyme and stool consistency respectively. No obstructive or overt infiltrative disease was noted. No associated abnormal lymphatic activity was noted.

Pancreas

The base and limbs of the **pancreas** were observed to be largely isoechoic to surrounding omental fat. Pancreatic duct and capsular contour were acceptably normal and parenchyma respected normal curvilinear patterns. No overt evidence of active inflammatory or neoplastic disease was noted.

Free Abdomen

A large amount of abdominal fat was noted in this patient.

ULTRASONOGRAPHIC FINDINGS

Splenic mass with concerning left-sided liver nodules/mass effect. Differentials for the spleen include hemangiosarcoma, hyperplasia or less likely round cell neoplasia. Differentials for the liver include benign cystic hyperplasia versus biliary carcinoma or metastatic disease from the spleen.

INTERPRETED BY

Eric Lindquist, DMV
DABVP, Cert. IVUSS

IMAGING PERFORMED BY

Dr. Striano-Kaplan

HOSPITAL NAME

Ramsey VH

REFERRING VET

Dr. Striano-Kaplan

INTERPRETATION OF THE FINDINGS & FURTHER RECOMMENDATIONS

Ultrasound-guided FNA can be considered; however, these are typically fruitful from an exfoliative cytological standpoint. The liver may be benign; however, the spleen is precarious and removed with inspection of the liver. Surgical biopsies are recommended or left liver lobectomy could be considered. The left-sided liver lesions appear resectable. CT evaluation for surgical planning of the abdomen and chest would be ideal to assess for metastatic disease regarding the thorax and surgical planning regarding the abdomen.

ABOUT SONOPATH CT SERVICES:

SonoPath CT Services are offered at the SonoPath Imaging and Veterinary Education Center, 141 Main St (rt 206), Andover, New Jersey, a 20-minute drive west on route 80/206 North from the route 80/287 interchange/Parsippany, New Jersey. More information can be found at <https://sonopath.com/resources/sonopaths-teleconsultation-services-and-sdep-certification/sonopath-ct-services>

INVOICE

42941

DATE

2/23/23



PATIENT

Ryder Powers

SPECIES

Canine

BREED

Labrador Retriever

SEX

Neutered male

AGE

11 years

WEIGHT

91.3 lbs

INTERPRETED BY

Eric Lindquist, DMV
DABVP, Cert. IVUSS

IMAGING PERFORMED BY

Dr. Striano-Kaplan

HOSPITAL NAME

Ramsey VH

REFERRING VET

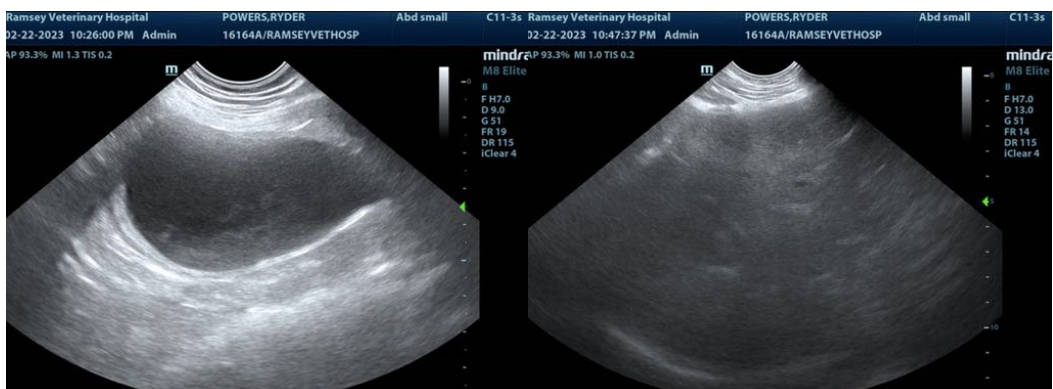
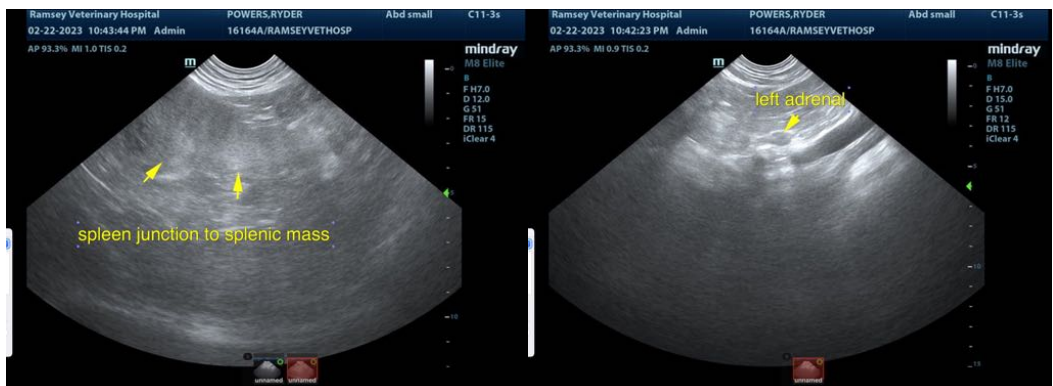
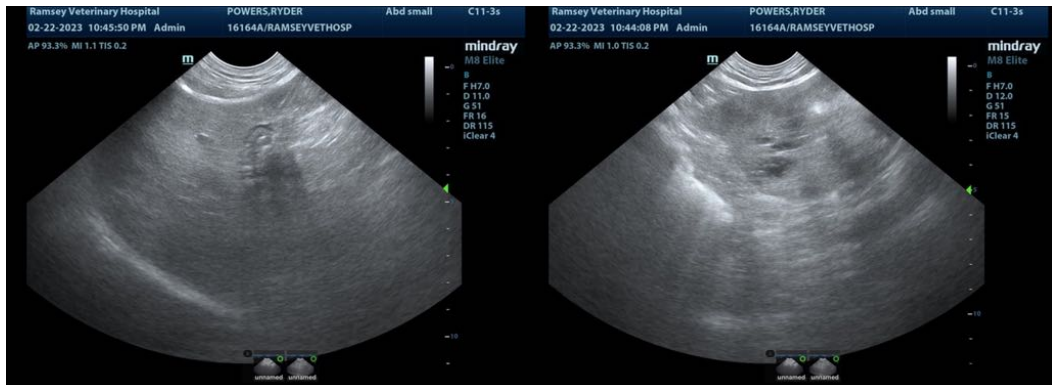
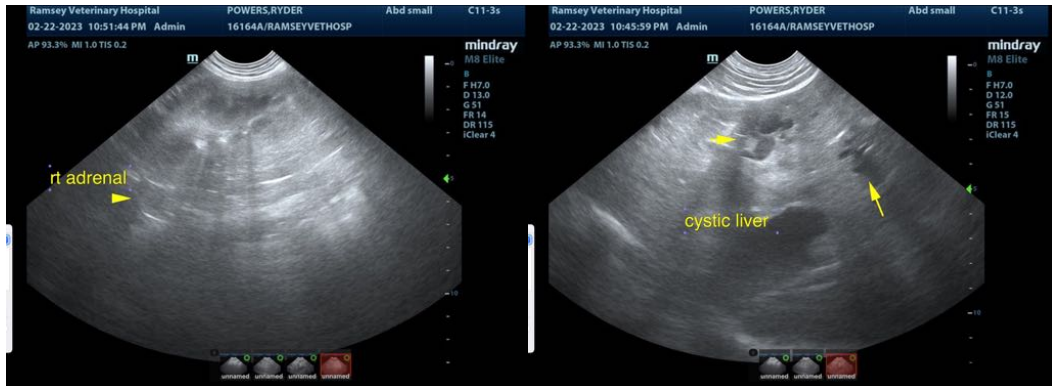
Dr. Striano-Kaplan

INVOICE

42941

DATE

2/23/23





PATIENT

Ryder Powers

SPECIES

Canine

BREED

Labrador Retriever

SEX

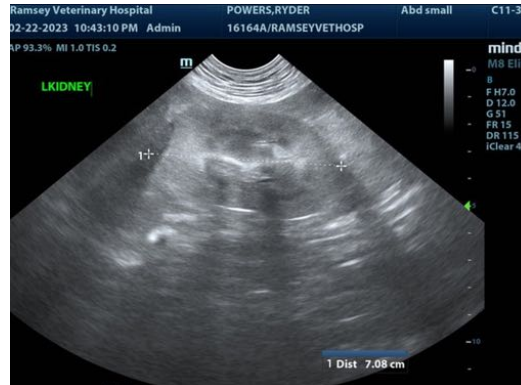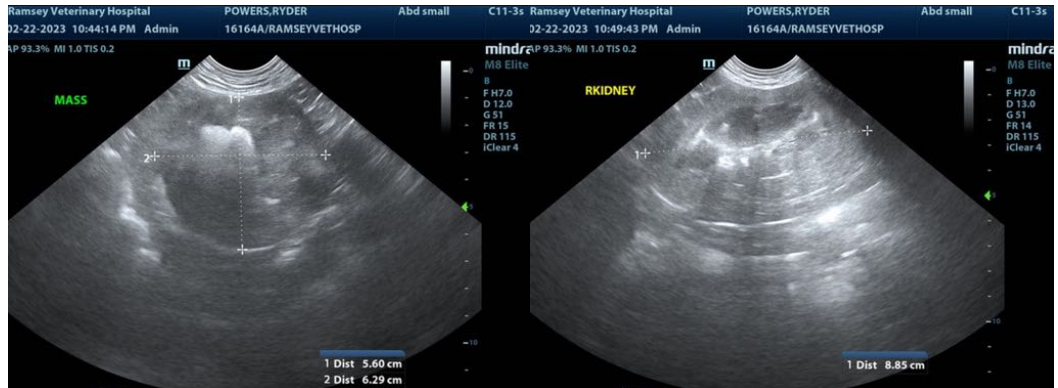
Neutered male

AGE

11 years

WEIGHT

91.3 lbs



INTERPRETED BY

Eric Lindquist, DMV
DABVP, Cert. IVUSS

IMAGING PERFORMED BY

Dr. Striano-Kaplan

HOSPITAL NAME

Ramsey VH

REFERRING VET

Dr. Striano-Kaplan

INVOICE

42941

DATE

2/23/23

The information and recommendations provided are based on the images presented by the referring veterinarian/sonographer. No evaluation can be communicated regarding pathology that was not visible in the image/video clips provided.

Thank you for this referral. If the clinical or image interpretation does not parallel your findings or if I can be of any further assistance please contact me.

Eric Lindquist, DMV, DABVP, Cert. IVUSS, CEO of SonoPath.com
info@SonoPath.com