



**PATIENT**

Bowser Soltys

**SPECIES**

Canine

**BREED**

Mix

**SEX**

Neutered male

**AGE**

12 years

**WEIGHT**

19.4 lbs

**INTERPRETED BY**

Eric Lindquist, DMV  
DABVP, Cert. IVUSS

**IMAGING PERFORMED BY**

Dr. Ammeraal

**HOSPITAL NAME**

Sova AH

**REFERRING VET**

Dr. Ammeraal

**INVOICE**

42939

**DATE**

2/23/23

**PRESENTING CLINICAL SIGNS**

History: Presented for wellness exam, No clinical concerns except a few dermal masses.  
Abnormal PE/Chem/CBC/UA Results: Multiple adenomas and follicular cysts, BCS 6/9 CHem 27: SDMA 10,4 BUN 34 mg/dl , Crea 2.0mg/dL , USG 1.019 obtained same time K+ 5.6 mEq/L rest NSF Urine sediment normal. 2nd recheck BUN/Crea in house today 23mg/dL, Crea 1.0 mg/dL - normal

**ULTRASONOGRAPHIC EXAMINATION OF THE ABDOMEN**

**Urinary System**

The **urinary bladder**, trigone, and pelvic urethra presented normal thicknesses and normal tone. The ureters were not visible which is normal. No uroliths or sediment were visualized and anechoic urine was present. No evidence of inflammatory or neoplastic changes was noted. Ureteral papillae were normal.

The residual prostate measured 0.5 cm.

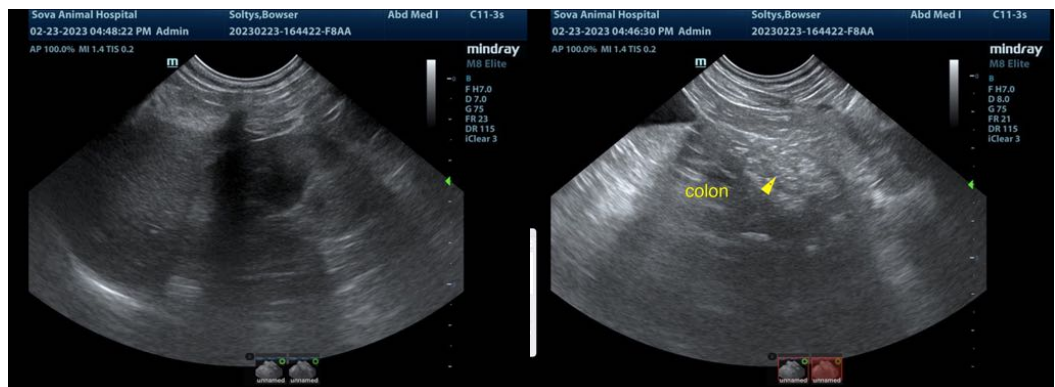
The **kidneys** revealed normal size and structure, corticomedullary definition and ratio for this age. The cortices presented largely uniform texture with normal echogenic relationship to liver and spleen. Medullary structure differed distinctly from the cortex and no evidence of pelvic dilation was present. The capsules were acceptably uniform without significant irregularities. The left kidney measured 4.94 cm. The right kidney measured 4.96 cm.

**ULTRASONOGRAPHIC FINDINGS**

Structurally normal upper and lower urinary tract, there was no evidence of pathology.

**INTERPRETATION OF THE FINDINGS & FURTHER RECOMMENDATIONS**

Screening for Addison's or other complicating factors should be considered if not already performed, yet structurally the urinary tract was unremarkable.





**PATIENT**

Bowser Soltys

**SPECIES**

Canine

**BREED**

Mix

**SEX**

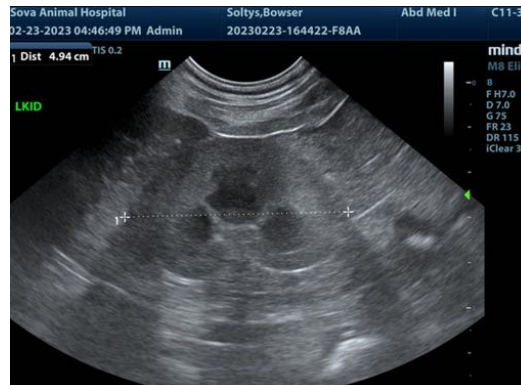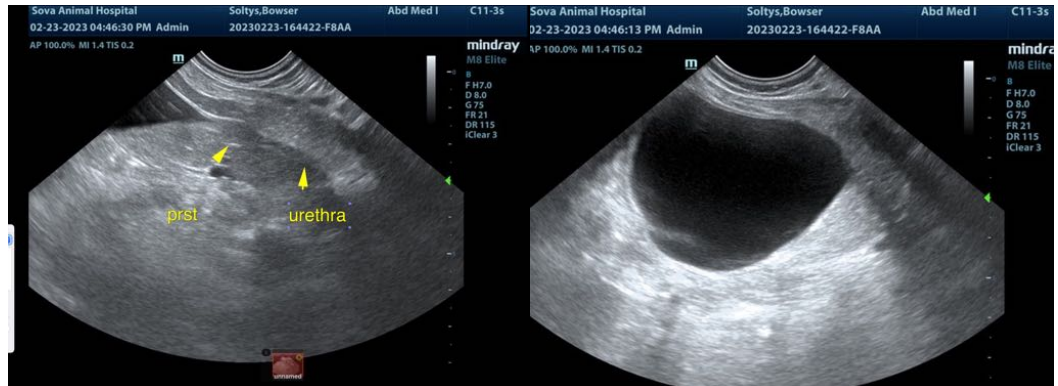
Neutered male

**AGE**

12 years

**WEIGHT**

19.4 lbs



**INTERPRETED BY**

Eric Lindquist, DMV  
DABVP, Cert. IVUSS

**IMAGING PERFORMED BY**

Dr. Ammeraal

**HOSPITAL NAME**

Sova AH

**REFERRING VET**

Dr. Ammeraal

**INVOICE**

42939

**DATE**

2/23/23

The information and recommendations provided are based on the images presented by the referring veterinarian/sonographer. No evaluation can be communicated regarding pathology that was not visible in the image/video clips provided.

Thank you for this referral. If the clinical or image interpretation does not parallel your findings or if I can be of any further assistance please contact me.

**Eric Lindquist**, DMV, DABVP, Cert. IVUSS, CEO of SonoPath.com  
info@SonoPath.com