



PATIENT

Revy Resch

SPECIES

Canine

BREED

Siberian Husky

SEX

Neutered Male

AGE

7 Years

WEIGHT

75 Lbs.

INTERPRETED BY

Eric Lindquist, DMV
DABVP, Cert. IVUSS

IMAGING PERFORMED BY

Tiffany Brady, DVM

HOSPITAL NAME

Shiloh VH

REFERRING VET

David Schneider, DVM

INVOICE

14054

DATE

2/23/22

PRESENTING CLINICAL SIGNS

History: Recent history of distended abdomen with an episode of weakness and pale MM after a walk

Abnormal PE/Chem/CBC/UA Results: Elevated WBC and ALT (191), otherwise unremarkable Fluid analysis pending

ULTRASONOGRAPHIC EXAMINATION OF THE ABDOMEN

Urinary System

The **urinary bladder**, trigone, and pelvic urethra presented normal thicknesses and normal tone. The ureters were not visible which is normal. No uroliths or sediment were visualized, and anechoic urine was present. No evidence of inflammatory or neoplastic changes were noted. Ureteral papillae were normal.

The **kidneys** revealed largely normal size and structure, corticomedullary definition and ratio (cortex 1/3 of medulla) were essentially maintained with some age-related loss of curvilinear patterns regarding the capsule and C/M junction. The cortices presented largely uniform texture with some increased echogenicity expected for his age patient. Medullary structure differed distinctly from that of the cortex and no evidence of pelvic dilation was present. The left kidney measured 6.48 cm. The right kidney measured 6.9 cm.

Adrenal Glands

The **adrenal glands** were not visualized.

Spleen

The visible **spleen** revealed minor heterogeneous changes. No overt masses were noted. Hyperechoic mesentery obscured some visibility.

Liver

The **liver** revealed minor enlargement and heterogeneous parenchymal changes. The gallbladder and common bile duct were unremarkable.

Gastrointestinal

Examination of the **gastrointestinal tract** revealed a stomach and intestine free of stasis, of normal wall thickness, acceptable curvilinear mural detail, and peristaltic activity. Small and large intestine demonstrated normal luminal chyme and stool consistency respectively. No obstructive or overt infiltrative disease was noted. No associated abnormal lymphatic activity was noted.

Pancreas

The base and limbs of the **pancreas** were observed to be largely isoechoic to surrounding omental fat. Pancreatic duct and capsular contour were acceptably normal and parenchyma respected normal curvilinear patterns. No overt evidence of active inflammatory or neoplastic disease was noted.

Free Abdomen

A moderate amount of echogenic free fluid was noted in the **abdomen**. An undefined mass was noted caudal to the right kidney, may be occupying the vena cava, possibly of adrenal origin.



PATIENT

Revy Resch

SPECIES

Canine

BREED

Siberian Husky

SEX

Neutered Male

AGE

7 Years

WEIGHT

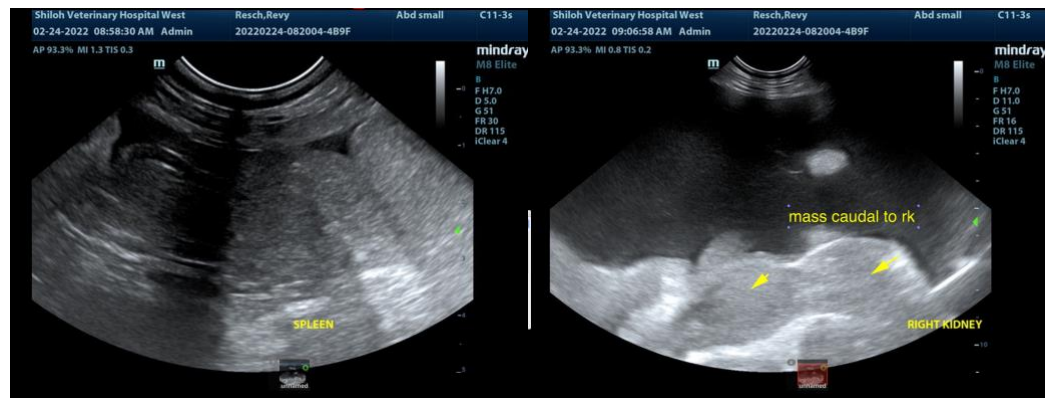
75 Lbs.

ULTRASONOGRAPHIC FINDINGS

- Free fluid
- Mass caudal to the right kidney
- Heterogeneous splenic and hepatic changes
- Age-related renal changes

INTERPRETATION OF THE FINDINGS & FURTHER RECOMMENDATIONS

Abdominocentesis and cytospin recommended, instead of simple fluid analysis, in order to conserve the integrity of the cells. CT evaluation would be ideal, however, the mass caudal to the right kidney is concerning and likely the underlying cause. Further imaging of the adrenal glands, especially SDEP 14 approach (under full sedation) would be appropriate.



INTERPRETED BY

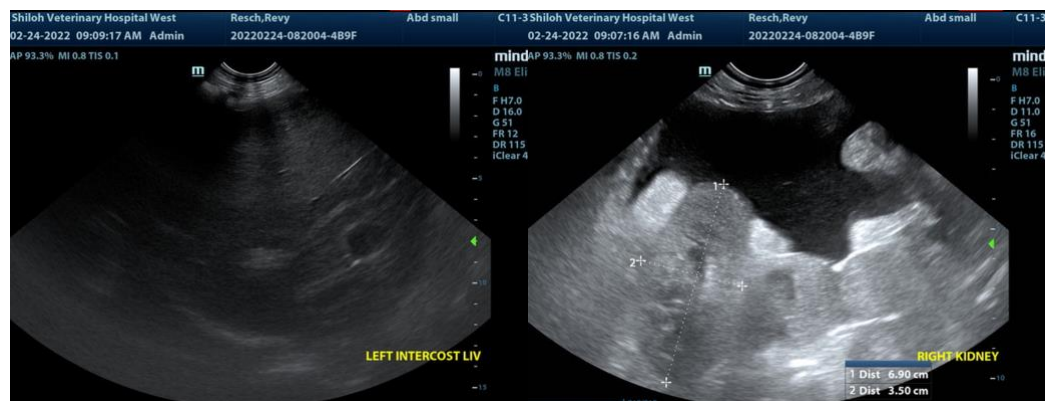
Eric Lindquist, DMV
DABVP, Cert. IVUSS

IMAGING PERFORMED BY

Tiffany Brady, DVM

HOSPITAL NAME

Shiloh VH



REFERRING VET

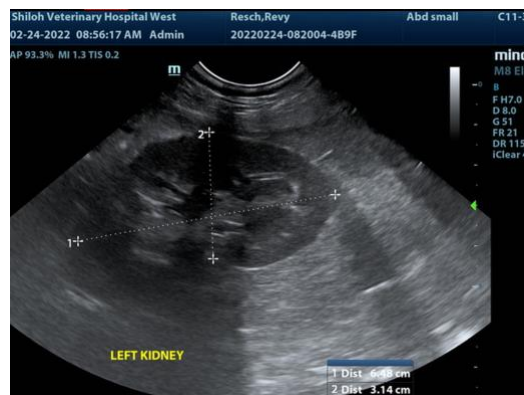David Schneider, DVM

INVOICE

14054

DATE

2/23/22





PATIENT

Revy Resch

The information and recommendations provided are based on the images presented by the referring veterinarian. No evaluation can be communicated regarding pathology that was not visible in the image/video clips provided.

SPECIES

Canine

Thank you for this referral. If the clinical or image interpretation does not parallel your findings or if I can be of any further assistance please contact me.

BREED

Siberian Husky

Eric Lindquist, DMV, DABVP, Cert. IVUSS, CEO of SonoPath.com
info@SonoPath.com

SEX

Neutered Male

AGE

7 Years

WEIGHT

75 Lbs.

INTERPRETED BY

Eric Lindquist, DMV
DABVP, Cert. IVUSS

**IMAGING
PERFORMED BY**

Tiffany Brady, DVM

HOSPITAL NAME

Shiloh VH

REFERRING VET

David Schneider, DVM

INVOICE

14054

DATE

2/23/22