



PATIENT

Pineapple PEIc

SPECIES

Feline

BREED

Domestic Shorthair

SEX

Spayed Female

AGE

8 years

WEIGHT

13.2 lbs

INTERPRETED BY

Eric Lindquist, DMV
DABVP, Cert. IVUSS

IMAGING PERFORMED BY

Adrienne Ligenza

HOSPITAL NAME

Rush VC

REFERRING VET

Dr. Urban

INVOICE

96282

DATE

2/23/22

PRESENTING CLINICAL SIGNS

recheck scan from January, acute renal insult resolved with fluid therapy
Abnormal PE/Chem/CBC/UA Results: see attached BW and previous
ultrasounds SG 1.051 today

ULTRASONOGRAPHIC EXAMINATION OF THE ABDOMEN

Urinary System

The **urinary bladder**, trigone, and pelvic urethra presented normal thicknesses and normal tone. The ureters were not visible which is normal. No uroliths or sediment were visualized and anechoic urine was present. No evidence of inflammatory or neoplastic changes was noted. Ureteral papillae were normal.

The **kidneys** presented a relatively uniform cortical hyperechogenicity when compared to the renal medulla, spleen and liver. No overt masses were noted. Corticomedullary definition was nebulous and the ratio favored the cortex slightly. The ureters were not visible and assumed to be normal. These changes are most consistent with chronic interstitial nephritis yet infiltrative disease could not be entirely ruled out without biopsy though neoplasia is not suspected. Mild cortical collapse was noted on the left kidney owing to infarct. The blood flow to the left kidney was subnormal on Power Doppler assessment. The left kidney measured 3.82 cm with slight pyelectasia. The right kidney measured 4.08 cm.

Adrenal Glands

Both **adrenal glands** were visualized and recognized as having normal shape, size, position and echogenicity for this breed. The phrenic vasculature, glandular echogenicity and detail were unremarkable. Capsule, cortex, and medullary definition were normal for this age patient. The left adrenal gland measured 0.32 cm.

Spleen

The **spleen** presented a smooth homogeneous parenchyma hyperechoic to liver and renal cortical parenchyma. The capsule was smooth without noticeable expansion or deviation from within the spleen or adjacent pathology. The splenic vasculature demonstrated normal volume without signs of congestion or thrombosis. No sonographic evidence of acute or chronic inflammatory, neoplastic, or infarctual changes was noted.

Liver

The **liver** images submitted revealed subjectively normal liver size, contour, and structure. Parenchymal echogenicity was naturally coarse and hypoechoic to the spleen. Vascular and biliary tracts were of normal volume with no evidence of congestion. The gallbladder presented acceptably thin walls with primarily anechoic content. The cystic and common bile ducts were normal. No pathological hepatic



PATIENT

lymphadenopathy was evident. No overt structural evidence of inflammatory, infiltrative or regenerative pathology was evident.

Pineapple PEIc

SPECIES

Gastrointestinal

Feline

Examination of the **gastrointestinal tract** revealed a stomach and intestine free of stasis, of normal wall thickness, acceptable curvilinear mural detail, and peristaltic activity. Small and large intestine demonstrated normal luminal chyme and stool consistency respectively. No obstructive or overt infiltrative disease was noted. No associated abnormal lymphatic activity was noted.

BREED

Domestic Shorthair

SEX

Spayed Female

Pancreas

The base and limbs of the **pancreas** were observed to be largely isoechoic to surrounding omental fat. Pancreatic duct and capsular contour were acceptably normal and parenchyma respected normal curvilinear patterns. No overt evidence of active inflammatory or neoplastic disease was noted.

AGE

8 years

ULTRASONOGRAPHIC FINDINGS

Mild to moderate degenerative renal disease with left renal infarct. The changes were mild on the right and moderate on the left.

WEIGHT

13.2 lbs

INTERPRETATION OF THE FINDINGS & FURTHER RECOMMENDATIONS

There was no other evidence of a disease process. The abdomen appears subjectively stable.

INTERPRETED BY

Eric Lindquist, DMV
DABVP, Cert. IVUSS

IMAGING PERFORMED BY

Adrienne Ligenza

HOSPITAL NAME

Rush VC

REFERRING VET

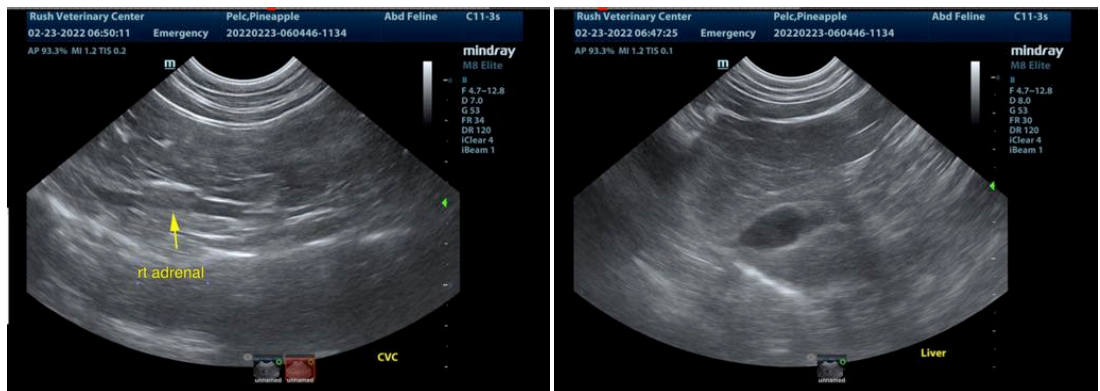
Dr. Urban

INVOICE

96282

DATE

2/23/22





PATIENT

Pineapple PELC

SPECIES

Feline

BREED

Domestic Shorthair

SEX

Spayed Female

AGE

8 years

WEIGHT

13.2 lbs

INTERPRETED BY

Eric Lindquist, DMV
DABVP, Cert. IVUS

IMAGING PERFORMED BY

Adrienne Ligenza

HOSPITAL NAME

Rush VC

REFERRING VET

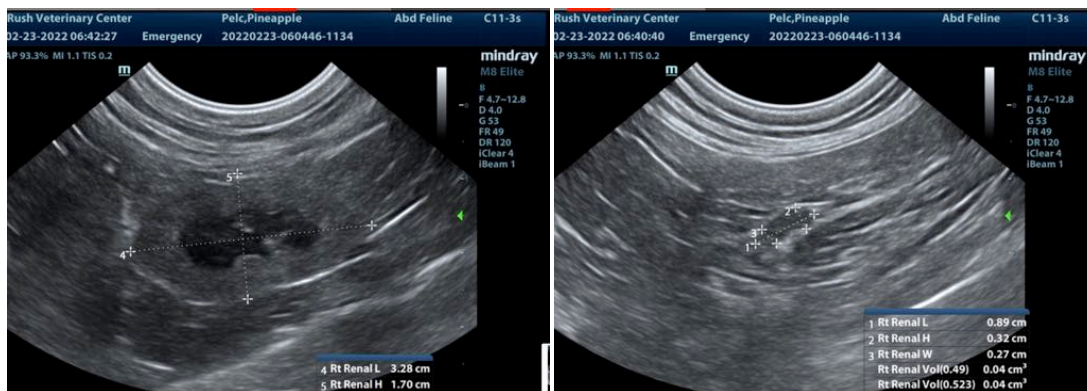
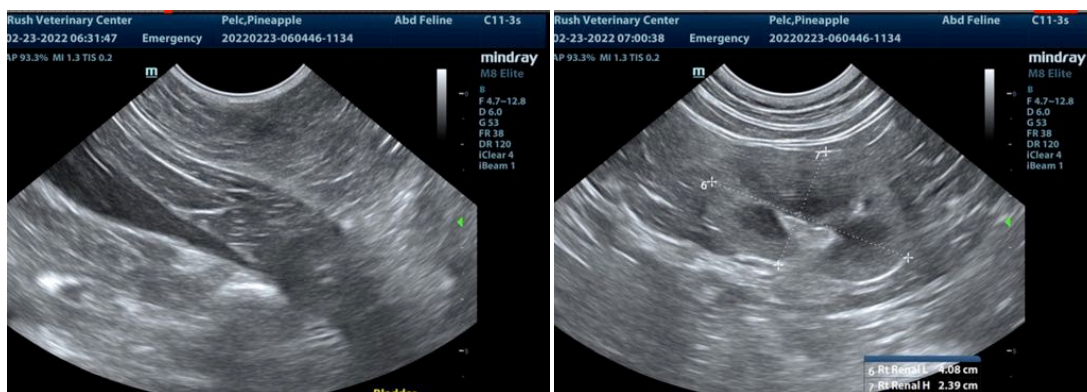
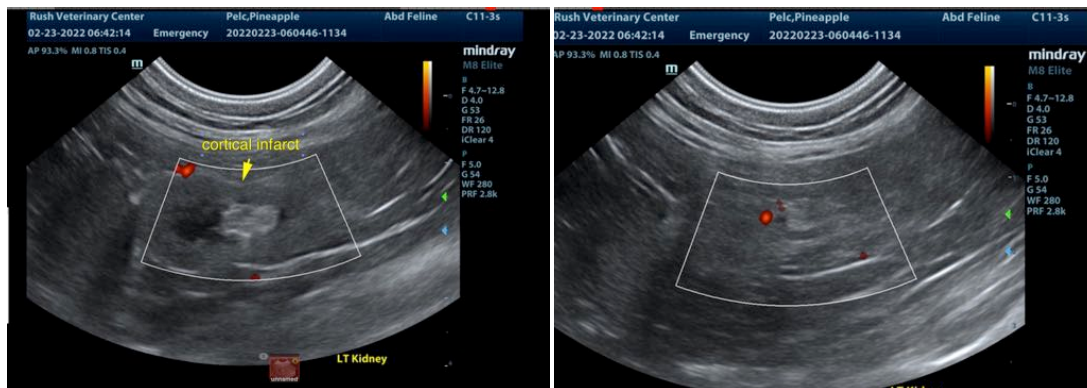
Dr. Urban

INVOICE

96282

DATE

2/23/22



The information and recommendations provided are based on the images presented by the referring veterinarian/sonographer. No evaluation can be communicated regarding pathology that was not visible in the image/video clips provided.

Thank you for this referral. If the clinical or image interpretation does not parallel your findings or if I can be of any further assistance please contact me.



PATIENT

Eric Lindquist, DMV, DABVP, Cert. IVUSS, CEO of SonoPath.com
info@SonoPath.com

Pineapple PEIc

SPECIES

Feline

BREED

Domestic Shorthair

SEX

Spayed Female

AGE

8 years

WEIGHT

13.2 lbs

INTERPRETED BY

Eric Lindquist, DMV
DABVP, Cert. IVUSS

**IMAGING
PERFORMED BY**

Adrienne Ligenza

HOSPITAL NAME

Rush VC

REFERRING VET

Dr. Urban

INVOICE

96282

DATE

2/23/22