



PATIENT

Maxwell Demers

SPECIES

Canine

BREED

Terrier Mix

SEX

Neutered male

AGE

15 years

WEIGHT

11.3 lbs

PRESENTING CLINICAL SIGNS

Recent onset cough. No radiographic evidence of CHF.
Grade iv/vi left apical systolic murmur, dental/ periodontal disease. Scheduled for COHAT next week.
Started on Pimobendan 1.25 mg BID

ULTRASONOGRAPHIC EXAMINATION OF THE HEART

The echocardiogram in this patient demonstrated enlarged **left atrial** size based on 3 different LA measurement methods. Chamber volumes and echogenicity were normal. The cranial and caudal **mitral** valve leaflets presented vegetative thickening consistent with endocardiosis. Prolapse of the anterior mitral valve leaflet was noted. Doppler indicated measurable insufficiency. The **left ventricle** presented thicknesses with linear contour and was not dilated nor restricted. The **myocardium** presented normal echogenicity without subjective evidence of significant fibrotic or ischemic disease. **Contractility** of the ventricular walls was adequate and in normal range for this patient evidenced by the fractional shortening measurement and subjective evaluation of the different regions of the myocardium. The **left ventricular outflow** tract demonstrated subjective structural integrity. The **right atrium** and auricle revealed normal size, structure and content. No evidence of masses was noted or chamber overload. **Tricuspid** valvular assessment demonstrated adequate linear morphology. The **right ventricle** was of normal size (1/3 diameter of LV), chordae structure, myocardial echogenicity and thickness. **Pulmonic** tract assessment revealed normal valve structure, and diameter (approx.1:1 pa/ao ratio). No visible **pericardial** or free pleura fluid was noted. No echographically detectable evidence of infiltrative disease was visible. The cranial **mediastinum and pericardial regions** were free of masses in the visible window. No hepatic vein dilation was noted.

INTERPRETED BY

Eric Lindquist, DMV
DABVP, Cert. IVUSS

IMAGING PERFORMED BY

Dr. Green

HOSPITAL NAME

Healing Spirit

REFERRING VET

Dr. Green

INVOICE

96283

DATE

2/23/22

CANINE	MR	TR	LA/AO	LA/AO	FS	EF	EPSS
CARDIAC PARAMETERS	VMAX (m/s)	VMAX (m/s)	(Boon method)	(Heart Base; Swe)	(%)	(%)	(cm)
NORMAL PARAMETER	4.5-5.5	<2.7	1.3	<1.6	28-40	40-100	<0.6
PATIENT	5.8		1.3		41	73	0.48
CANINE	HR	AV	PV	BODY WEIGHT	LA	LVIDd	LVIDs
CARDIAC PARAMETERS	(BPM)	VMAX (m/s)	MAX (m/s)		2D short axis Base view (cm)	Avg; 2D and m-mode short axis (cm)	Avg; 2D and m-mode short axis (cm)
NORMAL PARAMETER	50-100	0.7-1.7	0.7-1.6				
PATIENT	130	NM	NM	11.3 lbs	4.16 max	3.03	



PATIENT

Maxwell Demers

ULTRASONOGRAPHIC FINDINGS

Advanced stage B2 valvular disease to early C1.

SPECIES

Canine

INTERPRETATION OF THE FINDINGS & FURTHER RECOMMENDATIONS

I recommend continuing Pimobendan and adding ace inhibitor at 0.5 ,g/kg s.i.d. progressing to b.i.d., Spironolactone at 1-2 mg/kg b.i.d. and Lasix at 2-3 mg/kg b.i.d.

BREED

Terrier Mix

B2/C1: The heart is in a somewhat precarious state with volume overload and a heart that is working to compensate for the valvular insufficiency. Target respiratory rate is < 20 resp/minute after therapy.

SEX

Neutered male

After initiating therapy, I recommend recheck on the clinical exam, BUN, Creatinine, USG, Chest radiographs & Blood pressure in 5-7 days. Recheck echo in 1 month. Earlier if clinical decompensation is occurring. I do not recommend anesthesia at this time until stabilization has occurred on the recommended medications. Repeat pre-anesthetic echo is ideal if anesthesia is eventually necessary.

AGE

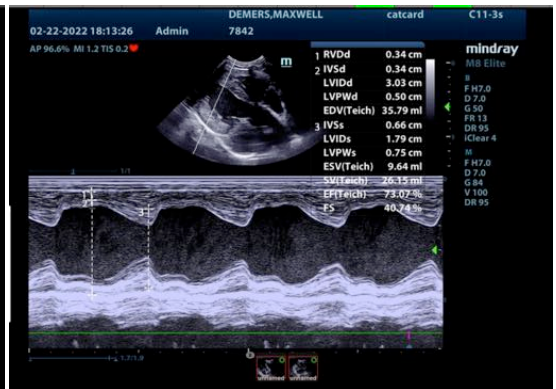
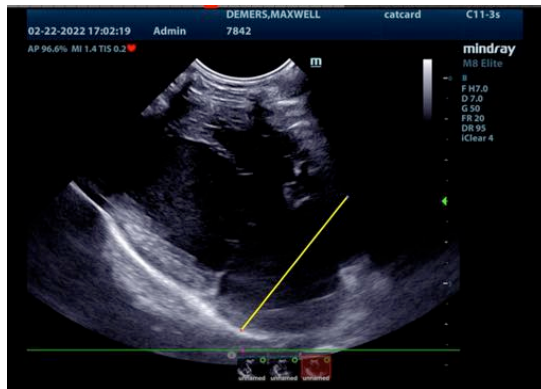
15 years

WEIGHT

11.3 lbs

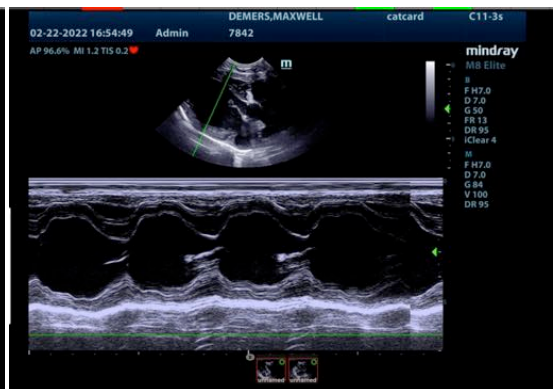
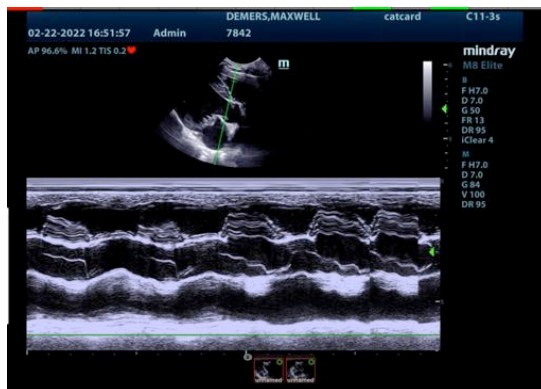
INTERPRETED BY

Eric Lindquist, DMV
DABVP, Cert. IVUS



IMAGING PERFORMED BY

Dr. Green



HOSPITAL NAME

Healing Spirit

REFERRING VET

Dr. Green

INVOICE

96283

DATE

2/23/22



PATIENT

Maxwell Demers

SPECIES

Canine

BREED

Terrier Mix

SEX

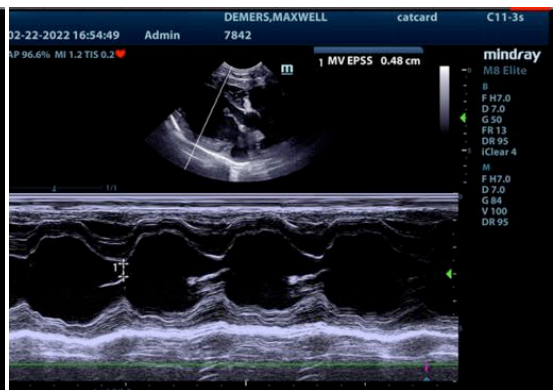
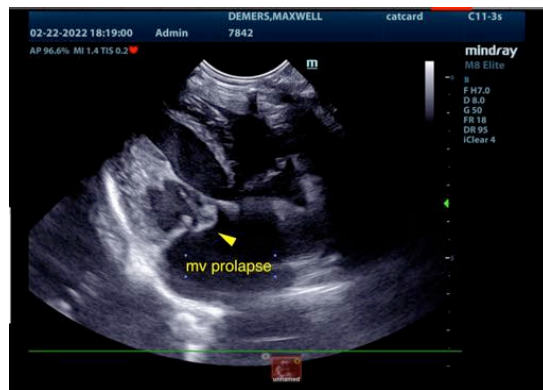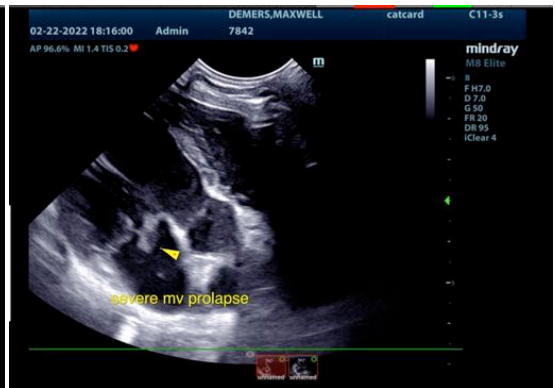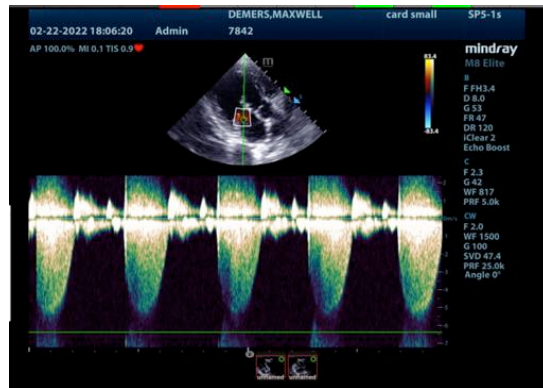
Neutered male

AGE

15 years

WEIGHT

11.3 lbs



INTERPRETED BY

Eric Lindquist, DMV
DABVP, Cert. IVUSS

IMAGING PERFORMED BY

Dr. Green

HOSPITAL NAME

Healing Spirit

REFERRING VET

Dr. Green

INVOICE

96283

DATE

2/23/22

The information and recommendations provided are based on the images presented by the referring veterinarian/sonographer. No evaluation can be communicated regarding pathology that was not visible in the image/video clips provided.

Thank you for this referral. If the clinical or image interpretation does not parallel your findings or if I can be of any further assistance please contact me.

Eric Lindquist, DMV, DABVP, Cert. IVUSS, CEO of SonoPath.com
info@SonoPath.com