



**PATIENT**

Coco Thomas

**PRESENTING CLINICAL SIGNS**

Patient presented for lethargy and not wanting to eat/drink  
Abnormal PE/Chem/CBC/UA Results: BNP and FPL were abnormal Grade 4 Heart Murmur Positive Murphy Sign in cranial abdomen

**SPECIES**

Feline

**ULTRASONOGRAPHIC EXAMINATION OF THE ABDOMEN**

**BREED**

Domestic Shorthair

**Urinary System**

The **urinary bladder**, trigone, and pelvic urethra presented normal thicknesses and normal tone. The ureters were not visible which is normal. No uroliths or sediment were visualized and anechoic urine was present. No evidence of inflammatory or neoplastic changes was noted. Ureteral papillae were normal.

**SEX**

Neutered male

**AGE**

5 years

The **kidneys** revealed normal size and structure, corticomedullary definition and ratio for this age. The cortices presented largely uniform texture with normal echogenic relationship to liver and spleen. Medullary structure differed distinctly from the cortex and no evidence of pelvic dilation was present. The capsules were acceptably uniform without significant irregularities. Both kidneys measured 3.5 cm.

**WEIGHT**

12.7 lbs

**Adrenal Glands**

Both **adrenal glands** were visualized and recognized as having normal shape, size, position and echogenicity for this breed. The phrenic vasculature, glandular echogenicity and detail were unremarkable. Capsule, cortex, and medullary definition were normal for this age patient.

**INTERPRETED BY**

Eric Lindquist, DMV  
DABVP, Cert. IVUSS

**Spleen**

**IMAGING PERFORMED BY**

Dr. Mack

The **spleen** presented a smooth homogeneous parenchyma hyperechoic to liver and renal cortical parenchyma. The capsule was smooth without noticeable expansion or deviation from within the spleen or adjacent pathology. The splenic vasculature demonstrated normal volume without signs of congestion or thrombosis. No sonographic evidence of acute or chronic inflammatory, neoplastic, or infarctual changes was noted.

**HOSPITAL NAME**

Northside VC

**Liver**

**REFERRING VET**

Dr. Mack

The **liver** images submitted revealed subjectively normal liver size, contour, and structure. Parenchymal echogenicity was naturally coarse and hypoechoic to the spleen. Vascular and biliary tracts were of normal volume with no evidence of congestion. The gallbladder presented acceptably thin walls with primarily anechoic content. The cystic and common bile ducts were normal. No pathological hepatic lymphadenopathy was evident. No overt structural evidence of inflammatory, infiltrative or regenerative pathology was evident.

**INVOICE**

96279

**DATE**

2/23/22



**PATIENT**

**Gastrointestinal**

Coco Thomas

Examination of the **gastrointestinal tract** revealed a stomach and intestine free of stasis, of normal wall thickness, acceptable curvilinear mural detail, and peristaltic activity. Small and large intestine demonstrated normal luminal chyme and stool consistency respectively. No obstructive or overt infiltrative disease was noted. No associated abnormal lymphatic activity was noted.

**SPECIES**

Feline

**BREED**

Domestic Shorthair

**Pancreas**

The base and limbs of the **pancreas** were observed to be largely isoechoic to surrounding omental fat. Pancreatic duct and capsular contour were acceptably normal and parenchyma respected normal curvilinear patterns. No overt evidence of active inflammatory or neoplastic disease was noted.

**SEX**

Neutered male

**ULTRASONOGRAPHIC FINDINGS**

Structurally unremarkable abdomen.

**AGE**

5 years

**INTERPRETATION OF THE FINDINGS & FURTHER RECOMMENDATIONS**

**WEIGHT**

12.7 lbs

There is no evidence of visceral disease that is overtly responsible for the clinical signs. Pain related anorexia, thoracic or CNS disease should be considered. Given the pain in the cranial abdomen there is a potential for low-grade pancreatitis without sonographic appearance; however, referred back pain should also be considered.

**INTERPRETED BY**

Eric Lindquist, DMV  
DABVP, Cert. IVUSS

**IMAGING PERFORMED BY**

Dr. Mack

**HOSPITAL NAME**

Northside VC

**REFERRING VET**

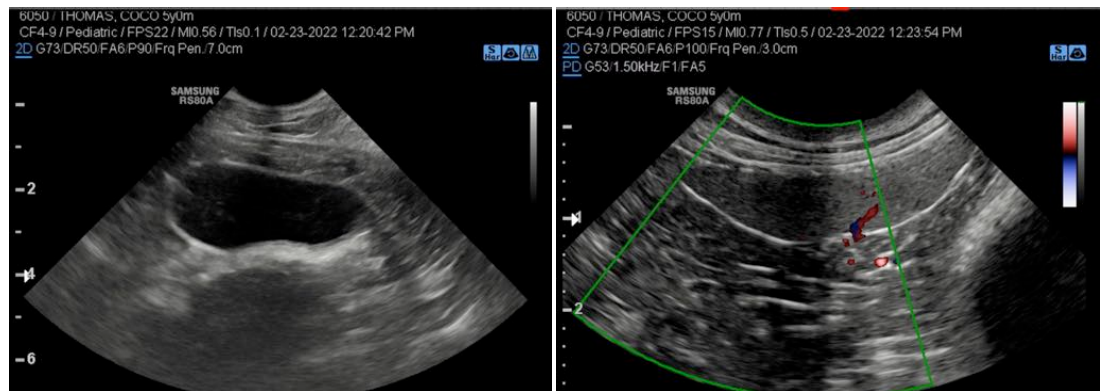
Dr. Mack

**INVOICE**

96279

**DATE**

2/23/22





**PATIENT**

Coco Thomas

**SPECIES**

Feline

**BREED**

Domestic Shorthair

**SEX**

Neutered male

**AGE**

5 years

**WEIGHT**

12.7 lbs

**INTERPRETED BY**

Eric Lindquist, DMV  
DABVP, Cert. IVUSS

**IMAGING PERFORMED BY**

Dr. Mack

**HOSPITAL NAME**

Northside VC

**REFERRING VET**

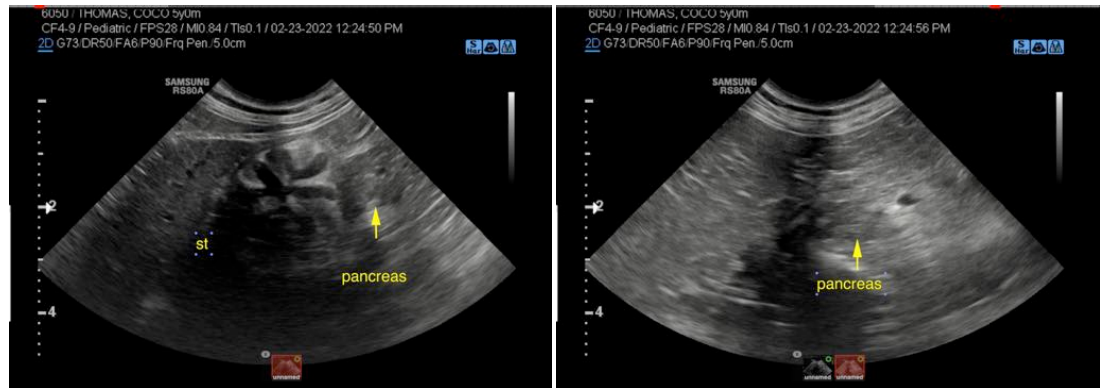
Dr. Mack

**INVOICE**

96279

**DATE**

2/23/22



The information and recommendations provided are based on the images presented by the referring veterinarian/sonographer. No evaluation can be communicated regarding pathology that was not visible in the image/video clips provided.

Thank you for this referral. If the clinical or image interpretation does not parallel your findings or if I can be of any further assistance please contact me.

**Eric Lindquist**, DMV, DABVP, Cert. IVUSS, CEO of SonoPath.com  
info@SonoPath.com