



**PATIENT PRESENTING CLINICAL SIGNS**

**PATIENT**  
Chami Oms

**SPECIES**  
Canine

**BREED**  
Bichon Frise

**SEX**  
Spayed Female

**AGE**  
16 years

**WEIGHT**  
8.9 lbs

**INTERPRETED BY**  
Eric Lindquist, DMV  
DABVP, Cert. IVUSS

**IMAGING PERFORMED BY**  
Dr. Cassel-Conway

**HOSPITAL NAME**  
Central Broward AH

**REFERRING VET**  
Dr. Oms

**INVOICE**  
96245

**DATE**  
2/22/22

Previous abd u/s done 8/17/21- Please compare images. Hx liver lesion hypoechoic, and heterogenous liver w/ numerous hypoechoic nodules.  
12/23/21- Polychromasia slight, Hct 45 %, Plt inc 555H, Alt-201h u/a- sp g 1022, prot 2+, urine c/s neg. Chest xrays wnl 11/12/21 bp - 140 mmhg

**ULTRASONOGRAPHIC EXAMINATION OF THE ABDOMEN**

**Urinary System**

The **urinary bladder**, trigone, and pelvic urethra presented normal thicknesses and normal tone. The ureters were not visible which is normal. No uroliths or sediment were visualized and anechoic urine was present. No evidence of inflammatory or neoplastic changes was noted. Ureteral papillae were normal.

The **kidneys** revealed largely normal size and structure, corticomedullary definition and ratio (cortex 1/3 of medulla) were essentially maintained with some age-related loss of curvilinear patterns regarding the capsule and C/M junction. The cortices presented largely uniform texture with some increased echogenicity expected for this age patient. Medullary structure differed distinctly from that of the cortex and no evidence of pelvic dilation was present. The left kidney measured 3.18 cm. The right kidney measured 3.73 cm.

**Adrenal Glands**

The right **adrenal gland** was uniform and measured 1.0 x 0.42 cm. The left adrenal gland was slightly enlarged and measured 1.18 x 0.59 cm.

**Spleen**

The **spleen** presented a smooth homogeneous parenchyma hyperechoic to liver and renal cortical parenchyma. The capsule was smooth without noticeable expansion or deviation from within the spleen or adjacent pathology. The splenic vasculature demonstrated normal volume without signs of congestion or thrombosis. No sonographic evidence of acute or chronic inflammatory, neoplastic, or infarctual changes was noted.

**Liver**

The **liver** in this patient revealed persistent, mixed hypoechoic nodular changes. The largest of which measured 3.5 x 3.04 cm. The nodular changes are persistent, yet not progressive. The gallbladder was mildly over distended with suspended and dependent debris, yet not to the level of emerging mucocele. However, the sludge appears to be mildly excessive. No adjunctive inflammation was noted.



**PATIENT**

**Gastrointestinal**

Chami Oms

Examination of the **gastrointestinal tract** revealed a stomach and intestine free of stasis, of normal wall thickness, acceptable curvilinear mural detail, and peristaltic activity. Small and large intestine demonstrated normal luminal chyme and stool consistency respectively. No obstructive or overt infiltrative disease was noted. No associated abnormal lymphatic activity was noted.

**SPECIES**

Canine

**BREED**

Bichon Frise

**Pancreas**

The base and limbs of the **pancreas** were observed to be largely isoechoic to surrounding omental fat. Pancreatic duct and capsular contour were acceptably normal and parenchyma respected normal curvilinear patterns. No overt evidence of active inflammatory or neoplastic disease was noted.

**SEX**

Spayed Female

**ULTRASONOGRAPHIC FINDINGS**

**AGE**

16 years

Nodular hyperplasia liver pattern.

Minor gallbladder debris, stable.

Irregular left adrenal gland.

**WEIGHT**

8.9 lbs

Age related renal changes.

**INTERPRETATION OF THE FINDINGS & FURTHER RECOMMENDATIONS**

**INTERPRETED BY**

Eric Lindquist, DMV  
DABVP, Cert. IVUSS

The left adrenal gland has progressed from the prior sonogram on 8/17/21. The right adrenal gland is essentially similar to the prior sonogram. If the patient appears Cushingoid and urine specific gravity is less than 1.020 then work-up for Cushing's is indicated. I do not believe that the hepatic changes are a clinical issue.

**IMAGING PERFORMED BY**

Dr. Cassel-Conway

**Efficient & Accurate Cushing's Work up-Lindquist**

**HOSPITAL NAME**

Central Broward AH

**Notes regarding Cushing's Clinical Presentations:**

*Nearly all Cushing's dogs have SAP elevations and true PU/PD (USG < 1.025) and most are polyphagic. Cushing's dogs are > 6 years and usually > 9 years old, usually have poor skin coats, body scores > 3/5, and are usually sedentary animals.*

*Its important to remember that Cushing's dogs usually look and play the part and other diseases cause false + stress related cortisol spikes. On rare occasion a Cushing's dog will not follow the rules but this is truly an exception.*

**REFERRING VET**

Dr. Oms

*Potential Cushing's patient workups can be costly and frustrating if not definitive and, in my experience, the non-definitive patient usually has something else going on that may be contributing to some of the clinical signs a Cushing's dog will have, especially SAP elevations or PU/PD. Based on this prelude of information I came up with the following algorithm in the spirit of diagnostic efficiency.*

**INVOICE**

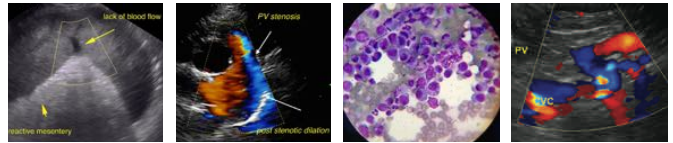
96245

*The following suggested protocol is based on current available literature on Cushing's disease and extensive clinical-sonographic experience evaluation + Cushing's and False + LDDST & ACTH stim. cases in order to maximize the efficiency of a Cushing's workup in practice.*

**DATE**

2/22/22

**Screen first, workup second**



**PATIENT**

Chami Oms

1) **UA:** Repeatable (2-3 urine samples) Urine specific gravity & urine cortisol/creatinine ratio (UCCR): If **repeatable USG < 10.20 and + UCCR** move to next step 2.

*Note: UA is inexpensive and easy to obtain and if UA criteria is not met for Cushing's then resources can be spent into other more pertinent diagnostics or left on hold until the UA criteria is met in emerging Cushing's cases.*

**SPECIES**

Canine

2) **Sonogram:** Does the patient **have concurrent disease** clinically or sonographically as non-Cushing's illness will influence the potential false + LDDST or even ACTH stim. The sonogram gives a global perspective of the internal health of the patient to be considered in the Cushing's workup as an assessment of concurrent disease. Is there a concurrent neoplastic process, UTI pancreatitis, mucocele...? Are the adrenals enlarged (Cushing's-PDH, stress, age related or breed variant), or atrophied (iatrogenic Cushing's or adrenal burnout), have asymmetric enlargement (Adrenal tumor, hyperplasia, adenoma, age related variant), or is there vascular invasion (Invasive pheo with false + UA criteria or adenocarcinoma or phrenic thrombosis)? The sonogram answers these questions proactively.

**BREED**

Bichon Frise

**SEX**

Spayed Female

3) **LDDST** (0.01 D-Sodium phosphate mg/kg IV) (Better screening test but plagued with false +) Use if there is potential early Cushing's or if adrenal asymmetry present on sonogram suspecting tumor. Use LDDST in cats at a higher dose (0.1 mg/kg IV).

**AGE**

16 years

**OR**

4) **ACTH stim.** (Better confirming test but can have false +) Use if the patient "looks" Cushingoid or if bilateral adrenal enlargement is present, or high normal width on sonogram, or if iatrogenic Cushing's suspected (Cortisone Tx in past).

**WEIGHT**

8.9 lbs

5) If **diabetic** then run both LDDST & ACTH stim.

**INTERPRETED BY**

Eric Lindquist, DMV  
DABVP, Cert. IVUSS

5) Run a **serial blood pressure** in a BP friendly non "white coat effect" atmosphere. Run at least 3 at different times over a few hours or when eating as the patient tends to be calm when eating or give Torbutrol when entering the facility.

**IMAGING PERFORMED BY**

Dr. Cassel-Conway

6) **Perform CT** of the pituitary to identify macro adenoma expansion if any lethargy or dullness or other central clinical CNS signs are minimally present.

**HOSPITAL NAME**

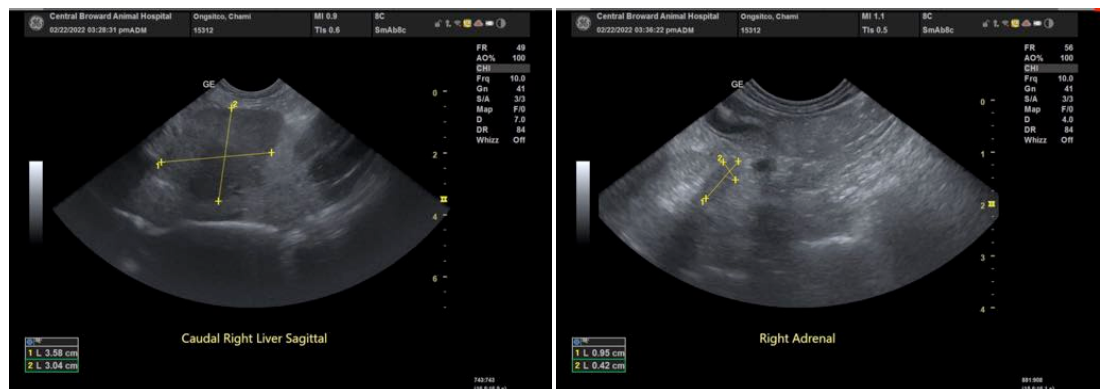
Central Broward AH

Suggested reading:

Behrend EN, Kooistra HS, Nelson R, et al. Diagnosis of Spontaneous Canine Hyperadrenocorticism: 2012 ACVIM Consensus Statement (Small Animal). J Vet Intern Med 2013;27:1292-1304.

**REFERRING VET**

Dr. Oms



**INVOICE**

96245

**DATE**

2/22/22



**PATIENT**

Chami Oms

**SPECIES**

Canine

**BREED**

Bichon Frise

**SEX**

Spayed Female

**AGE**

16 years

**WEIGHT**

8.9 lbs

**INTERPRETED BY**

Eric Lindquist, DMV  
DABVP, Cert. IVUSS

**IMAGING PERFORMED BY**

Dr. Cassel-Conway

**HOSPITAL NAME**

Central Broward AH

**REFERRING VET**

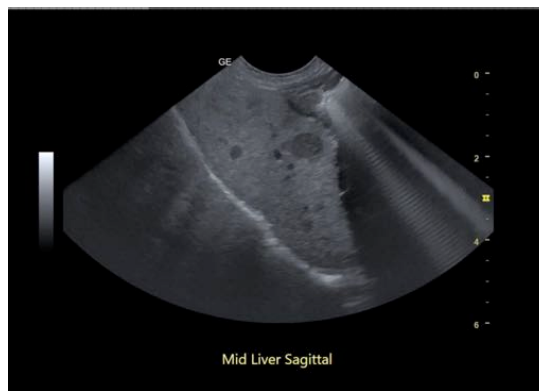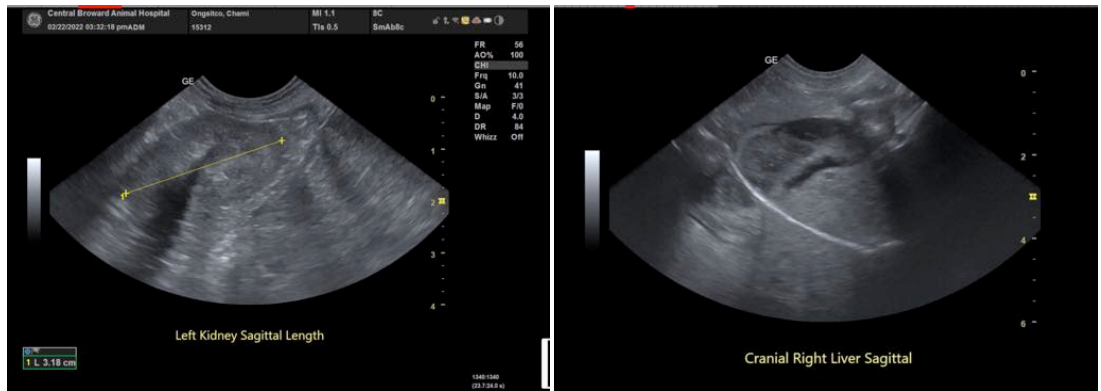
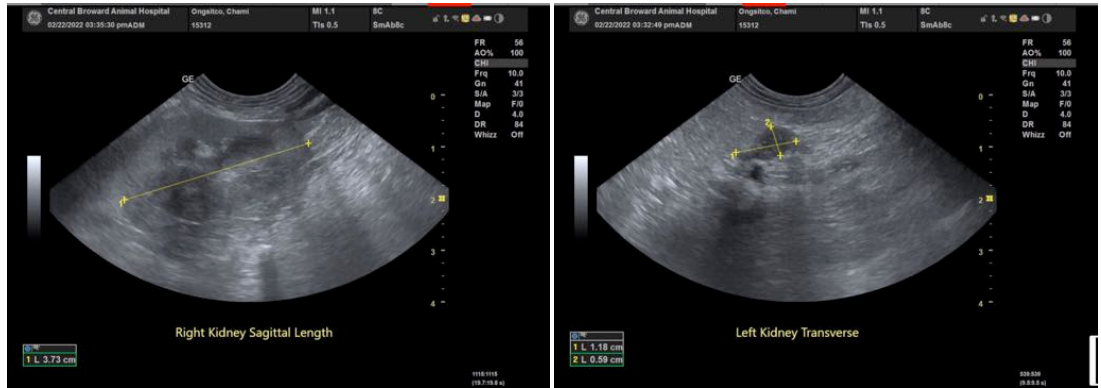
Dr. Oms

**INVOICE**

96245

**DATE**

2/22/22



The information and recommendations provided are based on the images presented by the referring veterinarian/sonographer. No evaluation can be communicated regarding pathology that was not visible in the image/video clips provided.

Thank you for this referral. If the clinical or image interpretation does not parallel your findings or if I can be of any further assistance please contact me.

Eric Lindquist, DMV, DABVP, Cert. IVUSS, CEO of SonoPath.com  
info@SonoPath.com