

**DATE PRESENTING CLINICAL SIGNS**

2/22/22

Referral for Continued Care

History: Date: 02-22-2022 Notes: On 10 days ago he ate an entire 16 oz bag (did not eat the plastic) of frozen onion rings. No symptoms until 6 days later, he became very lethargic. Lethargy has continued; still no vomiting. Not defecated for past 3 days also had small amount orange soft stool on rectal exam at rDVM this morning. History of bladder stones and cystostomy 3 years ago. Bloodwork results at rDVM this morning-- abnormalities: RBC 4; HGB 8.5; HCT 28%; ALKP 498; Urinalysis 10+ blood; 300+ protein; USG >1.050

**PATIENT**

Blade Hughlett

**SPECIES**

Canine

**BREED**

Schnauzer mix

**SEX**

Male, neutered

**AGE**

2014

**WEIGHT**

27.7 lbs.

Assessments: r/o onion toxicity (anemia); pancreatitis; gastroenteritis; IMHA.

Lab Results: Pending.

Date of Previous IntraPet Ultrasound: No previous.

Sedation: Not required to complete full diagnostic ultrasound.

Stat Report: Not requested.

Imaging Performed By: Rachel Brillhart, RDMS.

**ULTRASONOGRAPHIC EXAMINATION OF THE ABDOMEN****Urinary System**

The **urinary bladder**, trigone, and pelvic urethra presented normal thicknesses and normal tone. The ureters were not visible which is normal. A trace amount of sand accumulation was noted with minor bladder wall thickening and minor suspended debris. This should be medically dissolvable. No evidence of inflammatory or neoplastic changes was noted. Ureteral papillae were normal.

The **kidneys** revealed normal size and structure, corticomedullary definition and ratio for this age. The cortices presented largely uniform texture with normal echogenic relationship to liver and spleen. Medullary structure differed distinctly from the cortex. The capsules were acceptably uniform without significant irregularities. Slight pyelectasia of the right kidney was noted and measured 0.53 cm. The right kidney measured 5.91 cm.

**INTERPRETED BY**

Eric Lindquist, DMV,  
DABVP, Cert. IVUSS,  
CEO of SonoPath.com

**Adrenal Glands**

Both **adrenal glands** were visualized and recognized as having normal shape, size, position and echogenicity for this breed. The phrenic vasculature, glandular echogenicity and detail were unremarkable. Capsule, cortex, and medullary definition were normal for this age patient. The left adrenal gland measured 2.33 x 0.69 cm at the caudal pole and 0.62 cm at the cranial pole. The right adrenal gland measured 2.28 x 0.69 cm at the caudal pole and 0.71 cm at the cranial pole.

**HOSPITAL NAME**

Animal Emergency  
Hospital

**Spleen**

The **spleen** presented a smooth homogeneous parenchyma hyperechoic to liver and renal cortical parenchyma. The capsule was smooth without noticeable expansion or deviation from within the spleen or adjacent pathology. The splenic vasculature demonstrated normal volume without signs of congestion or thrombosis. No sonographic evidence of acute or chronic inflammatory, neoplastic, or infarctual changes was noted.

**REFERRING VET**

Dr. Martinoli

**INVOICE**

13018

**Liver**

Exam of the cranial abdomen demonstrated excessive **liver** size and swollen contour. Mild, coarse architecture was noted with increased portal markings and minor parenchymal remodeling is suggestive of an inflammatory component. Minor excessive GB debris was noted with the presence gall bladder dilation and precipitate without the overt formation of mucocele but this may be an issue in the future. This type of liver presentation typically is associated with slow and gradual SAP elevations with low-grade ALT rise. USG-FNA sampling is encouraged if more aggressive LE profiles are present such as ALT > 200 or rapid rise in SAP.

These presentations are usually reactive hepatopathies owing to other disease processes either endocrine (Diabetes, Hypothyroidism, Cushing's disease), "antigen surveillance" from the gut/pancreas, or idiopathic breed predisposed progressions.

### **Gastrointestinal**

Examination of the **gastrointestinal tract** revealed a stomach and intestine free of stasis, of normal wall thickness, acceptable curvilinear mural detail, and peristaltic activity. There is retention of ingesta noted in the stomach consistent with post prandial presentation. Small and large intestine demonstrated normal luminal chyme and stool consistency respectively. No obstructive or overt infiltrative disease was noted. No associated abnormal lymphatic activity was noted.

### **Pancreas**

The **pancreas** revealed minor, heterogenous, slight, irregular parenchymal changes were noted in the right and left limb. Subxiphoid palpation is recommended to assess for pain-solicited response. If pain is noted low grade pancreatitis is suspected.

### **ULTRASONOGRAPHIC FINDINGS**

Minor renal pyelectasia.

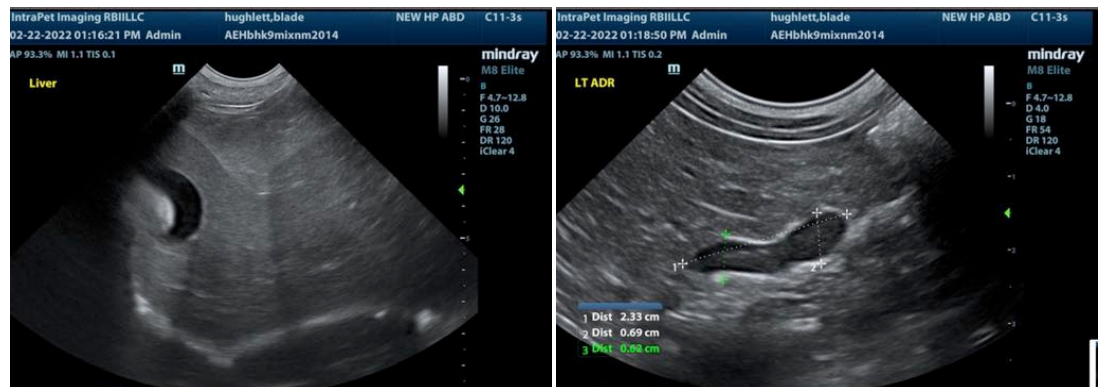
Benign hepatopathy.

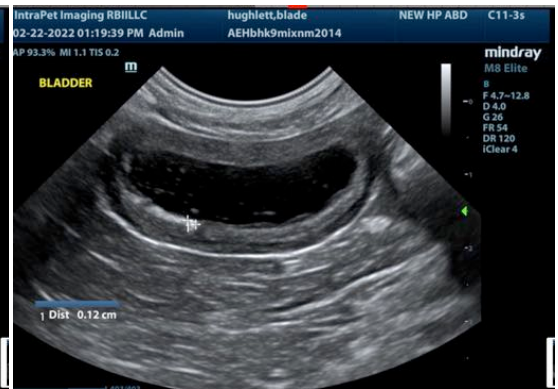
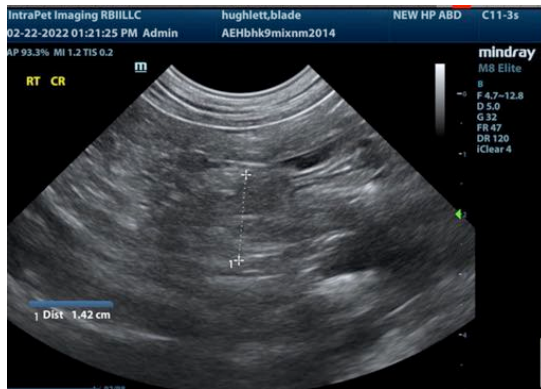
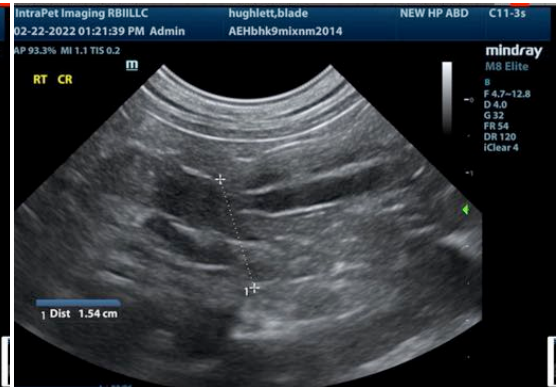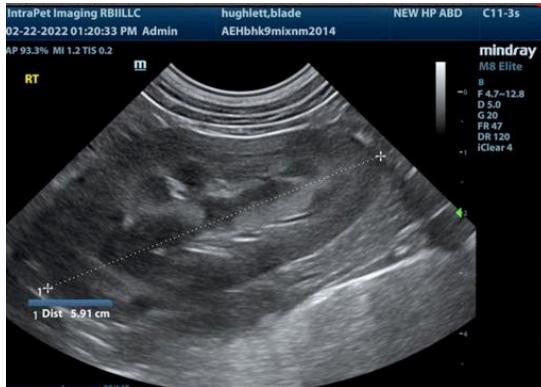
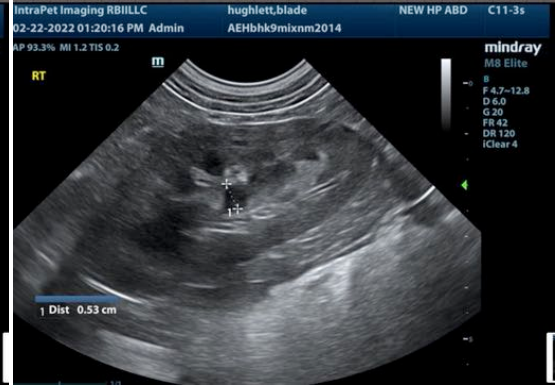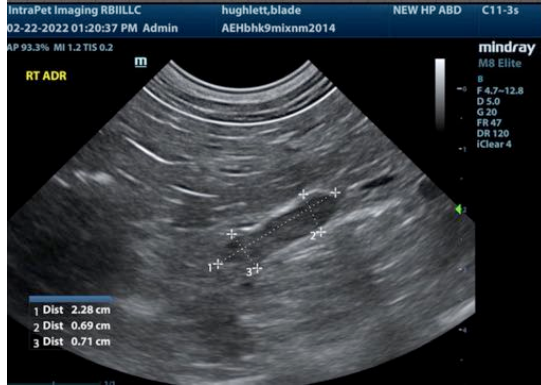
Minor heterogenous pancreas.

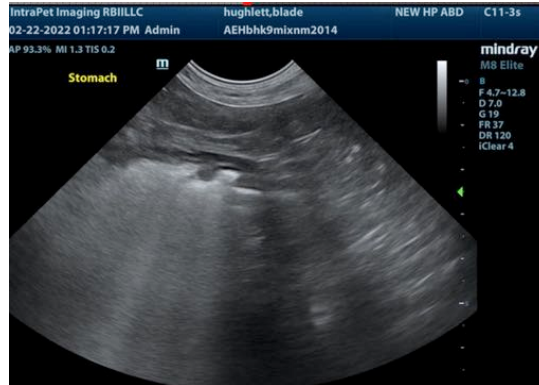Retention of ingesta noted in the stomach.

### **INTERPRETATION OF THE FINDINGS & FURTHER RECOMMENDATIONS**

I suspect low-grade pancreatitis in this patient. Diet change to a hydrolyzed diet may be in this patient's best interest. Pyelectasia in the left kidney may be owing to underlying occult infection or possible scarring from passage of sand and calculi, yet no obstructive disease is noted at this time.







The information and recommendations provided are based on the images presented by the referring veterinarian. No evaluation can be communicated regarding pathology that was not visible in the image/video clips provided.

Thank you for this referral. If the clinical or image interpretation does not parallel your findings or if I can be of any further assistance please contact me.

**Eric Lindquist**, DMV, DABVP, Cert. IVUSS, CEO of SonoPath.com  
Info@SonoPath.com