

**DATE PRESENTING CLINICAL SIGNS**

2/22/22

2-21-22: Patient got into a trash bin that was knocked over on Saturday. Has been anorexic since then. Started vomiting Sunday night and straining to poop but only passing mucus.

PATIENT

Ben Kraft

Current Medications: Amp/Sulb 1.2mL inj, Maropitant 10mg/mL 1.5mL Inj, Buprenorphine 0.6mg/mL 0.52mL.

Lab Results: Glob 4.8, ALT 164 (10-125), off scale high amylase and lipase, increased WBCs.

Radiographs: Very decreased serosal detail, concerning for peritonitis, single small linear metallic FB visible, possibly bread tie. No obvious masses. No signs of blockage but very hazy with peritonitis appearance. No obvious FF on fast scan but concerned about severe pancreatitis.

SPECIES

Canine

Date of Previous IntraPet Ultrasound: No previous.

Sedation: Not required to complete full diagnostic ultrasound.

Stat Report: Not requested.

BREED

Welsh Corgi

Imaging Performed By: Rachel Brillhart, RDMS.

SEX

Male, neutered

ULTRASONOGRAPHIC EXAMINATION OF THE ABDOMEN**Urinary System**

The **urinary bladder**, trigone, and pelvic urethra presented normal thicknesses and normal tone. The ureters were not visible which is normal. No uroliths or sediment were visualized and anechoic urine was present. No evidence of inflammatory or neoplastic changes was noted. Ureteral papillae were normal.

AGE

11/8/2010

The **kidneys** revealed largely normal size and structure, corticomedullary definition and ratio (cortex 1/3 of medulla) were essentially maintained with some age-related loss of curvilinear patterns regarding the capsule and C/M junction. The cortices presented largely uniform texture with some increased echogenicity expected for this age patient. Medullary structure differed distinctly from that of the cortex and no evidence of pelvic dilation was present. The left kidney measured 6.15 cm with slight pinpoint mineralization.

WEIGHT

34.9 lbs.

INTERPRETED BY

Eric Lindquist, DMV,
DABVP, Cert. IVUSS,
CEO of SonoPath.com

HOSPITAL NAME

Animal Emergency
Hospital

REFERRING VET

Dr. Goessling

Adrenal Glands

Both **adrenal glands** were visualized and recognized as having normal shape, size, position and echogenicity for this breed. The phrenic vasculature, glandular echogenicity and detail were unremarkable. Capsule, cortex, and medullary definition were normal for this age patient. The right adrenal gland measured 2.43 x 0.78 cm at the caudal pole and 0.58 cm at the cranial pole. The left adrenal gland measured 2.5 x 0.87 cm at the caudal pole and 0.8 cm at the cranial pole.

Spleen

The **spleen** revealed an expansive parenchymal mass that measured 4.34 cm and was deriving from the cranial pole. The remainder of the spleen was unremarkable.

Liver

The visible **liver** was unremarkable other than adhesions to the caudal aspect of the liver. Regional inflammation associated with the pancreas extended to the caudal aspect of the liver.

INVOICE

13019

Gastrointestinal

The **duodenum** and much of the cranial abdominal small intestine was enveloped by adhesions. The linear structure was noted in the patient's history was not overtly visible; however, given the degree of pancreatitis and regional peritonitis upper GI perforation is a strong potential. The epigastric lymph nodes are slightly enlarged. Regional peritonitis is noted.

Pancreas

The pancreas revealed an extensive, mixed, hypoechoic parenchymal changes with regional, hyperechoic fat. Adhesions were noted upon the upper gastrointestinal tract and regional areas of free fluid. The left pancreatic pathology extended for 8.5 x 3.8 cm.

Heart

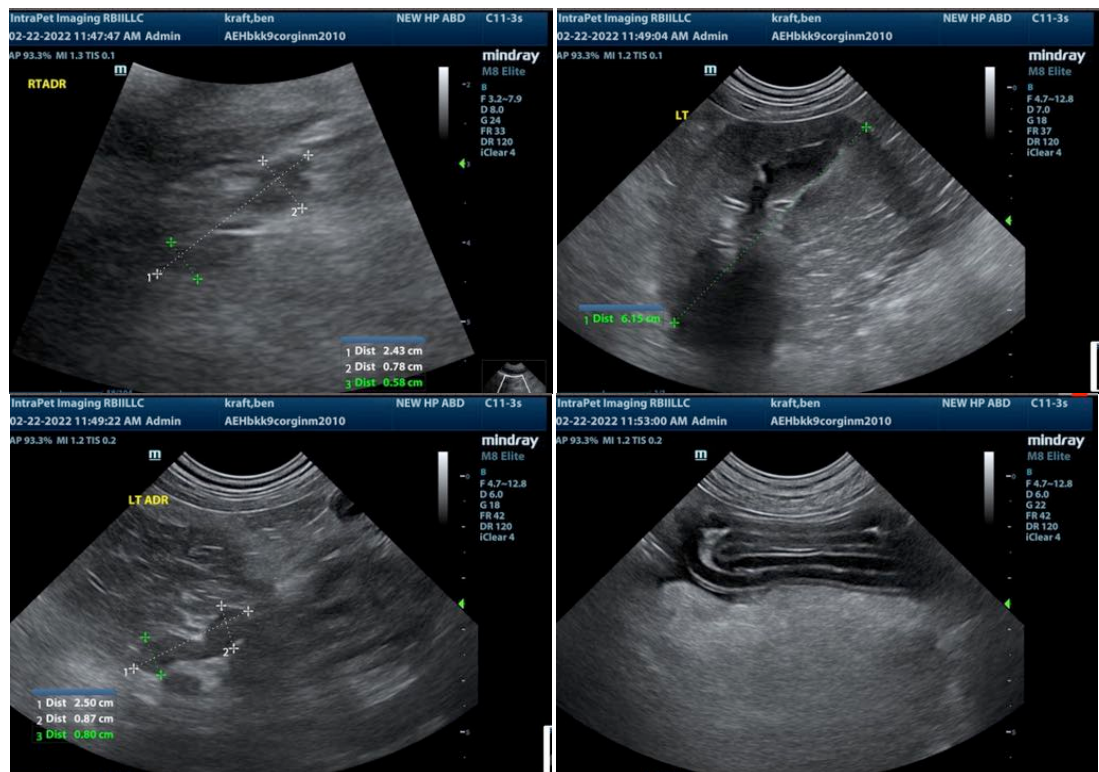
Rapid view of the heart revealed no evidence of pathology.

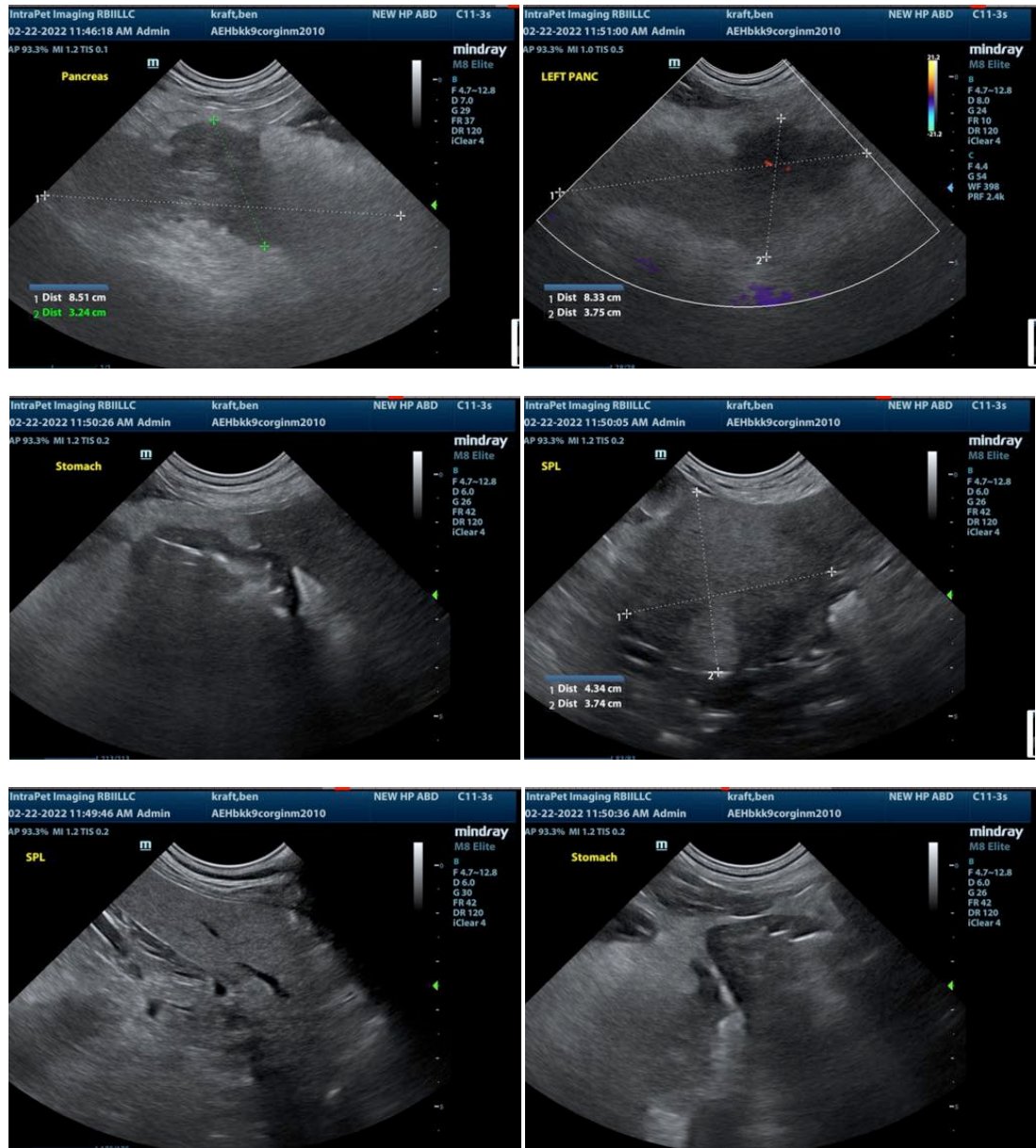
ULTRASONOGRAPHIC FINDINGS

- Extensive hypoechoic, parenchymal pancreatic changes with adhesion to the upper gastrointestinal tract.
- GI was enveloped by adhesions. Upper GI perforation is a strong potential.
- Splenic mass.

INTERPRETATION OF THE FINDINGS & FURTHER RECOMMENDATIONS

Given the splenic mass and extensive pancreatic pathology and potential for perforating foreign body I recommend exploratory surgery in this patient with expectations towards inspection of the GI tract, liberation of adhesions, debridement of presumed pancreatic necrosis and splenectomy. J tube placement may be optimal for post op management.





The information and recommendations provided are based on the images presented by the referring veterinarian. No evaluation can be communicated regarding pathology that was not visible in the image/video clips provided.

Thank you for this referral. If the clinical or image interpretation does not parallel your findings or if I can be of any further assistance please contact me.

Eric Lindquist, DMV, DABVP, Cert. IVUSS, CEO of SonoPath.com
 Info@SonoPath.com