

**PATIENT**

Hercules Ramsey  
(Derosa)

**SPECIES**

Canine

**BREED**

English Bulldog

**SEX**

Neutered Male

**AGE**

9 Years

**WEIGHT**

31.3 kg

**INTERPRETED BY**

Eric Lindquist, DMV,  
DABVP (CFM), Cert.  
IVUSS

**IMAGING PERFORMED BY**

Andrea Nicastro, DVM,  
DACVIM

**HOSPITAL NAME**

Blue Pearl Summerville

**REFERRING VET**

Dr. Natalie Wasiak

**INVOICE**

73163

**DATE**

2/21/26

**PRESENTING CLINICAL SIGNS**

No murmurs ausculted, tachycardic with irregular rhythm (HR 200s), femoral pulses not synchronous with beat. One episode of collapse recently. Went to RDVM today with urinary issues and arrhythmia ausculted; ECG sent out - ventricular tachycardia noted.

Abnormal PE/Chem/CBC/UA Results: ECG: Intermittent ventricular tachycardia, HR consistently >200

**ULTRASONOGRAPHIC EXAMINATION OF THE HEART**

CANINE CARDIAC PARAMETERS	MR VMAX (m/s)	TR VMAX (m/s)	LA/AO (M-Mode)	LA/AO (Heart Base; Swe)	FS (%)	EF (%)	EPSS (cm)
<b>NORMAL PARAMETER</b>	4.5-5.5	<2.7	1.3	Up to 1.6	28-40	40-100	<0.6
<b>PATIENT</b>	--	--	1.2	1.2	67	94	0.2
CANINE CARDIAC PARAMETERS	HR (BPM)	AV VMAX (m/s)	PV MAX (m/s)	BODY WEIGHT (kg)	LAD LA MAX 4 Chamber	LVIDd Avg; 2D and m-mode short axis (cm)	LVIDs Avg; 2D and m-mode short axis (cm)
<b>NORMAL PARAMETER</b>	50-100	0.7-1.7	0.7-1.6				
<b>PATIENT</b>	Variable	1.4	1.1	31.3	3.8	3.27	--

**Cardiac Presentation**

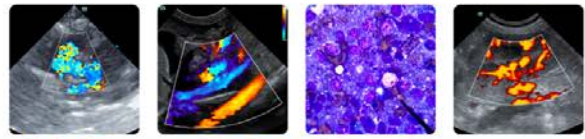
The cardiac presentation presented normal left-sided volume with persistent tachyarrhythmia. Minor tricuspid insufficiency and trivial mitral insufficiency noted, not clinically significant. No evidence of left-sided volume overload. Minor right-sided enlargement noted with prominent pulmonary artery, right atrium and right ventricle. However, no signs of right-sided heart failure present. Hepatic veins were not dilated. Outflow velocities were normal. No pericardial or pleural effusion.

**ULTRASONOGRAPHIC FINDINGS**

- Minor right-sided enlargement.
- Minor valvular disease with mild to moderate tricuspid insufficiency and trivial mitral insufficiency.
- Periodic tachyarrhythmia.

**INTERPRETATION OF THE FINDINGS & FURTHER RECOMMENDATIONS**

The right-sided enlargement may be conformational owing to the breed or may be exaggerated owing to the tachyarrhythmia. Recommend rate control in this patient based on EKG results. Holter monitor would be in this patient's best interest. Blood pressure measurements warranted if not already performed. The collapsing is likely owing to paroxysmal arrhythmogenic events. No primary cardiac medications recommended other than antiarrhythmics based on EKG results.



**PATIENT**

Hercules Ramsey  
 (Derosa)

**SPECIES**

Canine

**BREED**

English Bulldog

**SEX**

Neutered Male

**AGE**

9 Years

**WEIGHT**

31.3 kg

**INTERPRETED BY**

Eric Lindquist, DMV,  
 DABVP (CFM), Cert.  
 IVUSS

**IMAGING PERFORMED BY**

Andrea Nicastro, DVM,  
 DACVIM

**HOSPITAL NAME**

Blue Pearl Summerville

**REFERRING VET**

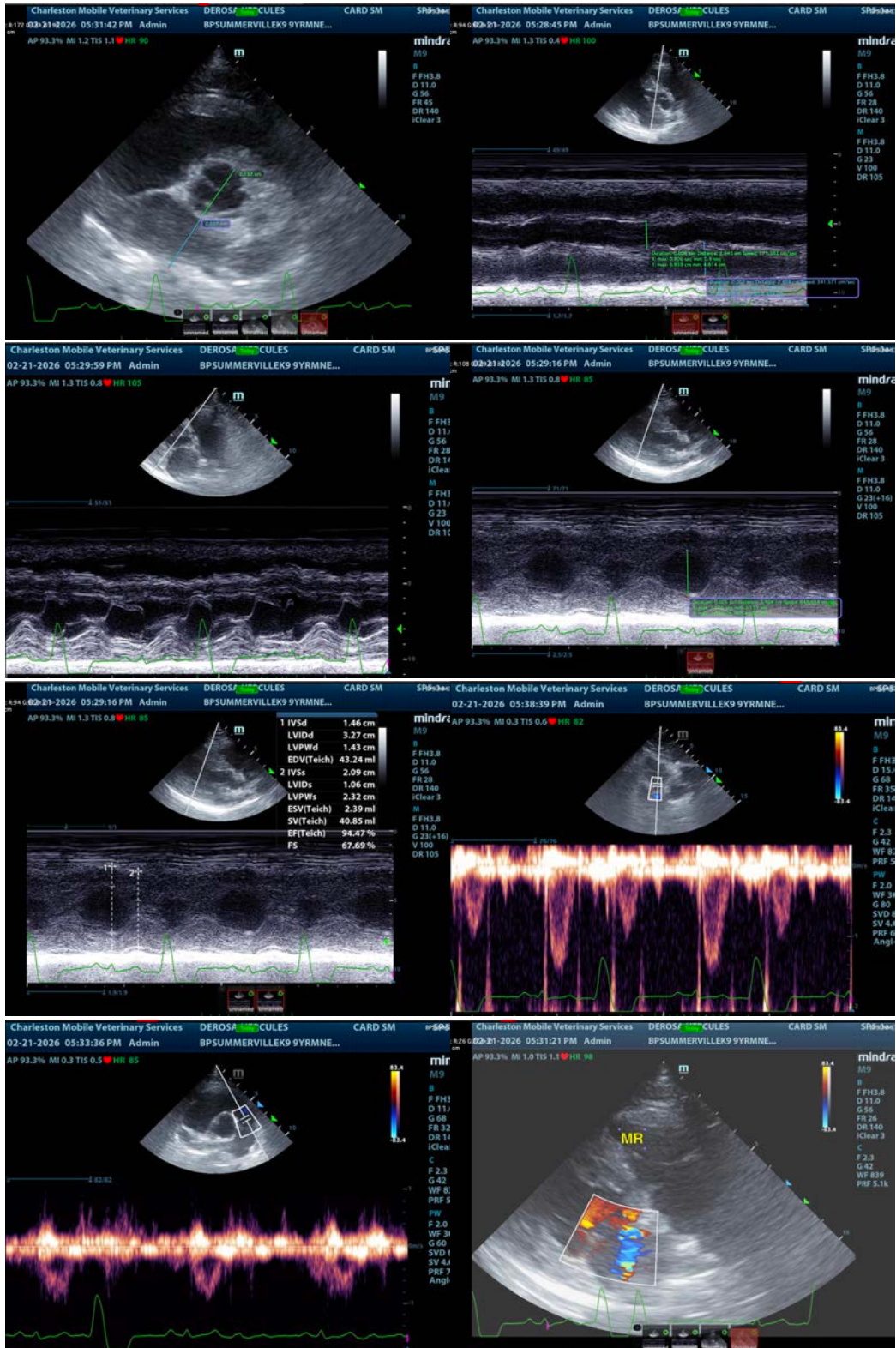
Dr. Natalie Wasiak

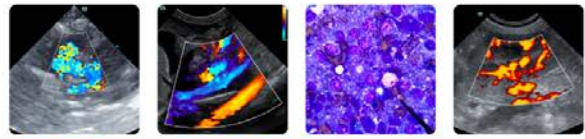
**INVOICE**

73163

**DATE**

2/21/26





**PATIENT**

Hercules Ramsey  
(Derosa)

**SPECIES**

Canine

**BREED**

English Bulldog

**SEX**

Neutered Male

**AGE**

9 Years

**WEIGHT**

31.3 kg

**INTERPRETED BY**

Eric Lindquist, DMV,  
DABVP (CFM), Cert.  
IVUSS

**IMAGING PERFORMED BY**

Andrea Nicastro, DVM,  
DACVIM

**HOSPITAL NAME**

Blue Pearl Summerville

**REFERRING VET**

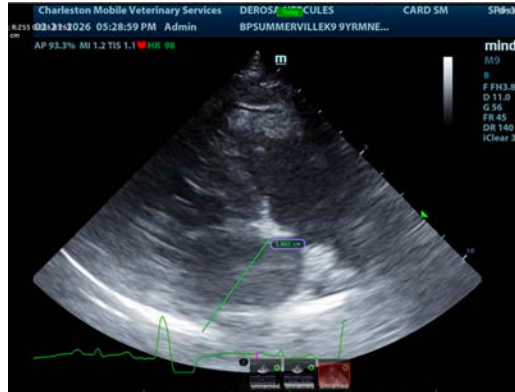
Dr. Natalie Wasiak

**INVOICE**

73163

**DATE**

2/21/26



The information and recommendations provided are based on the images presented by the referring veterinarian/sonographer. No evaluation can be communicated regarding pathology that was not visible in the image/video clips provided.

Thank you for this referral. If the clinical or image interpretation does not parallel your findings or if I can be of any further assistance please contact me.

**Eric Lindquist, DMV, DABVP(CFM), Cert. IVUSS,**  
CEO, Owner, Founder -- SonoPath.com  
[info@SonoPath.com](mailto:info@SonoPath.com)