**DATE**

2/21/22

PRESENTING CLINICAL SIGNS

Losing weight, elevated liver enzymes.

Current Medications: None listed.

Lab Results: Not provided.

PATIENT

Zooney Duckett

Date of Previous IntraPet Ultrasound: no previous.

Sedation: Not required to complete full diagnostic ultrasound.

Stat Report: Not requested.

Imaging Performed By: Rachel Brillhart, RDMS.

SPECIES

Canine

ULTRASONOGRAPHIC EXAMINATION OF THE ABDOMEN**Urinary System****BREED**

Goldendoodle

The **urinary bladder**, trigone, and pelvic urethra presented normal thicknesses and normal tone. The ureters were not visible which is normal. No uroliths or sediment were visualized and anechoic urine was present. No evidence of inflammatory or neoplastic changes was noted. Ureteral papillae were normal.

SEX

Spayed Female

The **kidneys** revealed normal size and structure, corticomedullary definition and ratio for this age. The cortices presented largely uniform texture with normal echogenic relationship to liver and spleen. Medullary structure differed distinctly from the cortex and no evidence of pelvic dilation was present. The capsules were acceptably uniform without significant irregularities. The left kidney measured 3.76 cm.

AGE

6/5/15

Adrenal Glands

Both **adrenal glands** were visualized and recognized as having normal shape, size, position and echogenicity for this breed. The phrenic vasculature, glandular echogenicity and detail were unremarkable. Capsule, cortex, and medullary definition were normal for this age patient. The right adrenal gland measured 1.47 x 0.51 cm at the caudal pole and 0.62 cm at the cranial pole. The left adrenal gland measured 1.43 x 0.48 cm at the cranial pole and 0.5 cm at the caudal pole.

WEIGHT

8 lbs

INTERPRETED BYEric Lindquist, DMV
DABVP, Cert. IVUSS**Spleen**

The **spleen** presented a smooth homogeneous parenchyma hyperechoic to liver and renal cortical parenchyma. The capsule was smooth without noticeable expansion or deviation from within the spleen or adjacent pathology. The splenic vasculature demonstrated normal volume without signs of congestion or thrombosis. No sonographic evidence of acute or chronic inflammatory, neoplastic, or infarctual changes was noted.

HOSPITAL NAME

Padonia VH

Liver**REFERRING VET**

Dr. Youssef

The **liver** presented heterogenous parenchyma with increased portal markings and coarse architecture. Slight undulating capsular contour was noted. The gallbladder and common bile duct were unremarkable. This is consistent with chronic inflammatory hepatopathy.

INVOICE

96199

Gastrointestinal

The **gastrointestinal tract** revealed an edematous wall and hyperperistalsis with no loss of mural detail. Minor enhanced surrounding fat was noted around the regions of the gastrointestinal serosa. There was no evidence of foreign body or neoplastic criteria. Intestinal wall thickness measured up to 0.3 cm. Mucosal speckling was noted through multiple areas of the GI tract. Images from the stomach, small intestine and colon were presented. Minor excessive GI gas was also noted. This is most consistent with gastroenteritis owing to viral, bacterial/endotoxin or possible parasitic disease. Reactive mesentery was present.

Pancreas

The base and limbs of the **pancreas** were observed to be largely isoechoic to surrounding omental fat. Pancreatic duct and capsular contour were acceptably normal and parenchyma respected normal curvilinear patterns. No overt evidence of active inflammatory or neoplastic disease was noted.

Free Abdomen

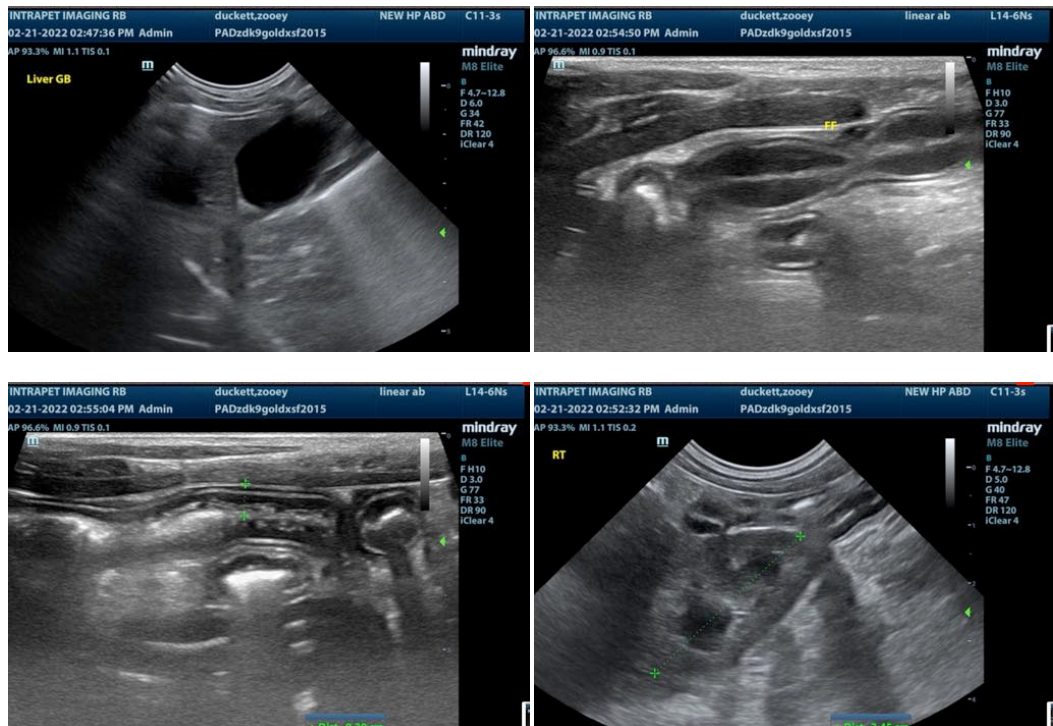
Slight free fluid was noted adjacent to the intestinal tract.

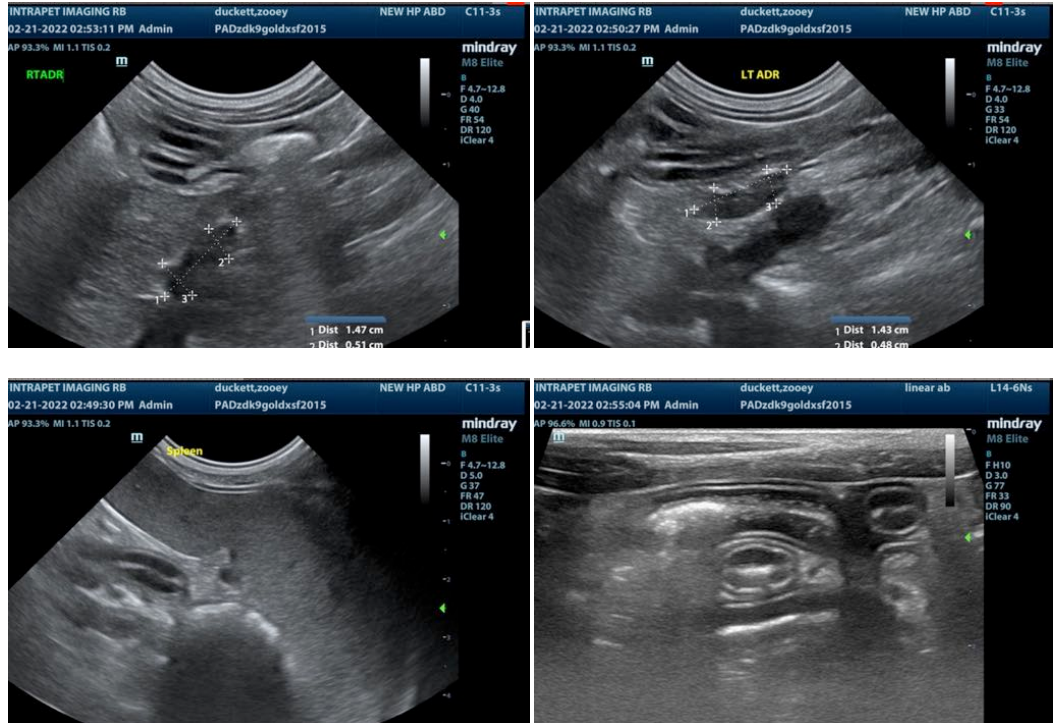
ULTRASONOGRAPHIC FINDINGS

Gastroenteritis pattern.
Mild hepatic remodeling.
Trace free fluid.

INTERPRETATION OF THE FINDINGS & FURTHER RECOMMENDATIONS

Albumin levels should be monitored in this patient given the potential for protein losing enteropathy. Dietary indiscretion, food intolerance/indiscretion, structurally insignificant inflammatory bowel or occult parasitism and occult Addison's are all potentials. Dietary indiscretion, food intolerance/indiscretion, structurally insignificant inflammatory bowel or occult parasitism and occult Addison's are all potentials. If the clinical signs persist over the next 1-2 weeks then a recheck sonogram is indicated. The albumin levels should be monitored carefully.





The information and recommendations provided are based on the images presented by the referring veterinarian. No evaluation can be communicated regarding pathology that was not visible in the image/video clips provided.

Thank you for this referral. If the clinical or image interpretation does not parallel your findings or if I can be of any further assistance please contact me.

Eric Lindquist, DMV, DABVP, Cert. IVUSS, CEO of SonoPath.com
Eric.Lindquist@SonoPath.com