



PATIENT PRESENTING CLINICAL SIGNS

Tyson Kim History: Chronic cough. R/O Cardiac Dz vs other. Current meds: Torb for u/s, was on Clavamox-no effect. Rads and rad report attached for reference.

SPECIES Abnormal PE/Chem/CBC/UA Results: Cardiopet Pro BNP 3418

Canine

ULTRASONOGRAPHIC EXAMINATION OF THE HEART

BREED

Maltese

SEX

Neutered Male

AGE

16 Years

WEIGHT

11.8 Lbs.

The echocardiogram in this patient demonstrated normal **left atrial** size based on 3 different LA measurement methods. Chamber volumes and echogenicity were normal. The cranial and caudal **mitral** valve leaflets presented vegetative thickening consistent with endocardiosis. Prolapse of the anterior mitral valve leaflet was noted. Doppler indicated measurable insufficiency. The **left ventricle** presented normal thicknesses with linear contour and was not dilated nor restricted. The **myocardium** presented normal echogenicity without subjective evidence of significant fibrotic or ischemic disease. **Contractility** of the ventricular walls was adequate and in normal range for this patient evidenced by the fractional shortening measurement and subjective evaluation of the different regions of the myocardium. The **left ventricular outflow** tract demonstrated normal laminar flow and subjective structural integrity. The **right atrium** and auricle revealed normal size, structure and content. No evidence of masses was noted or chamber overload. **Tricuspid** valvular assessment demonstrated adequate linear morphology. The **right ventricle** was of normal size (1/3 diameter of LV), chordae structure, myocardial echogenicity and thickness. **Pulmonic** tract assessment revealed normal valve structure, laminar flow, and diameter (approx. 1:1 pa/ao ratio). No visible **pericardial** or free pleura fluid was noted. No echographically detectable evidence of infiltrative disease was visible. The cranial **mediastinum and pericardial** regions were free of masses in the visible window.

INTERPRETED BY

Eric Lindquist, DMV
DABVP, Cert. IVUSS

IMAGING PERFORMED BY

Shari Reffi, CVT

HOSPITAL NAME

Morris Hills VC

REFERRING VET

Dr. Hirshenson

INVOICE

CANINE CARDIAC PARAMETERS	MR VMAX (m/s)	TR VMAX (m/s)	LA/AO (Boon method)	LA/AO (Heart Base; Swe)	FS (%)	EF (%)	EPSS (cm)
NORMAL PARAMETER	4.5-5.5	<2.7	1.3	<1.6	28-40	40-100	<0.6
PATIENT	5.11	3.8	1.91	1.75	42	75	0.1
CANINE CARDIAC PARAMETERS	HR (BPM)	AV VMAX (m/s)	PV MAX (m/s)	BODY WEIGHT	LA (2D short axis Base view) (cm)	LVIDd (Avg; 2D and m-mode short axis) (cm)	LVIDs (Avg; 2D and m-mode short axis) (cm)
NORMAL PARAMETER	50-100	0.7-1.7	0.7-1.6	BELOW	BELOW	BELOW	BELOW
PATIENT	123	1.16		11.8 lbs	3.56 max	3.01	

DATE

2/21/22



PATIENT

Tyson Kim

ULTRASONOGRAPHIC FINDINGS

- Advanced stage B2 valvular disease to early C1.
- Mitral valve prolapse.

SPECIES

Canine

INTERPRETATION OF THE FINDINGS & FURTHER RECOMMENDATIONS

I recommend Lasix at 2-3 mg/kg b.i.d., Spironolactone at 1-2 mg/kg b.i.d., Pimobendan at 0.3 mg/kg b.i.d. and ace inhibitor at 0.5 mg/kg s.i.d. progressing to b.i.d.

BREED

Maltese

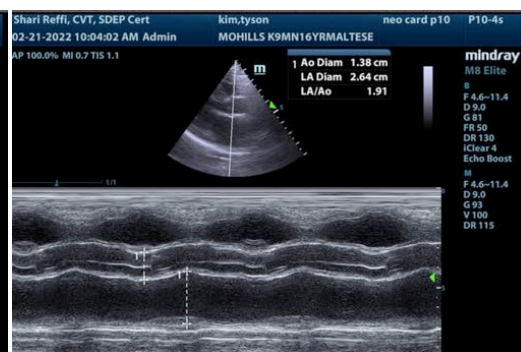
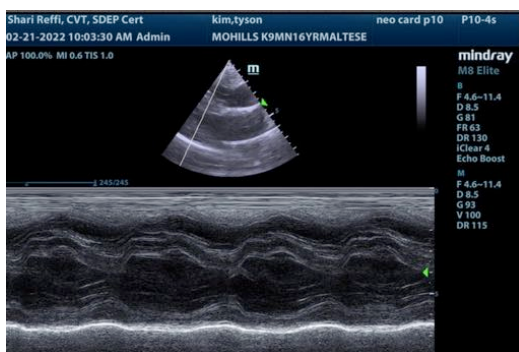
C1: The heart is in a somewhat precarious state with volume overload and a heart that is working to compensate for the valvular insufficiency. Target respiratory rate is < 20 resp/minute after therapy. After initiating therapy, I recommend recheck on the clinical exam, BUN, Creatinine, USG, Chest radiographs & Blood pressure in 5-7 days. Recheck echo in 1 month. Earlier if clinical decompensation is occurring. I do not recommend anesthesia at this time until stabilization has occurred on the recommended medications. Repeat pre-anesthetic echo is ideal if anesthesia is eventually necessary.

SEX

Neutered Male

AGE

16 Years

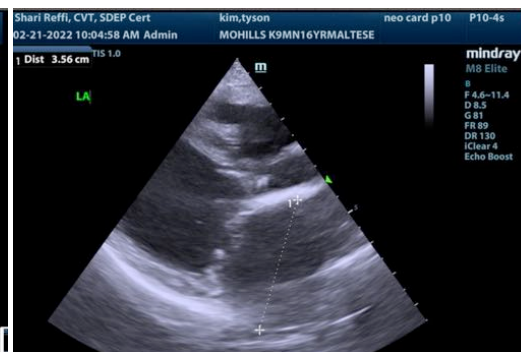
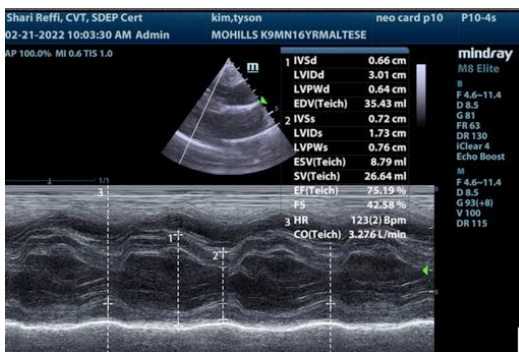


WEIGHT

11.8 Lbs.

INTERPRETED BY

Eric Lindquist, DMV DABVP, Cert. IVUSS

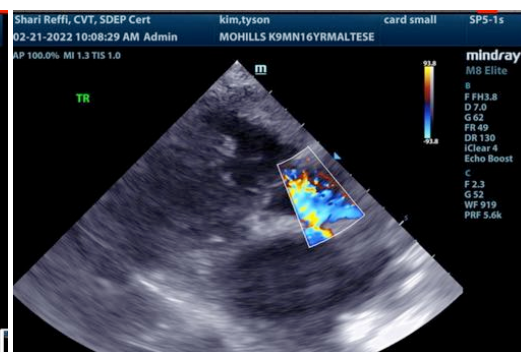
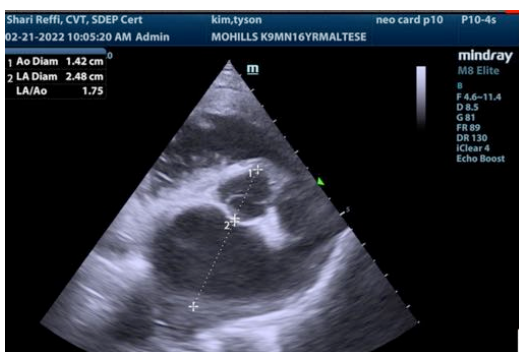


IMAGING PERFORMED BY

Shari Reffi, CVT

HOSPITAL NAME

Morris Hills VC



REFERRING VET

Dr. Hirshenson

INVOICE

DATE

2/21/22



PATIENT

Tyson Kim

SPECIES

Canine

BREED

Maltese

SEX

Neutered Male

AGE

16 Years

WEIGHT

11.8 Lbs.

INTERPRETED BY

Eric Lindquist, DMV
DABVP, Cert. IVUSS

IMAGING PERFORMED BY

Shari Reffi, CVT

HOSPITAL NAME

Morris Hills VC

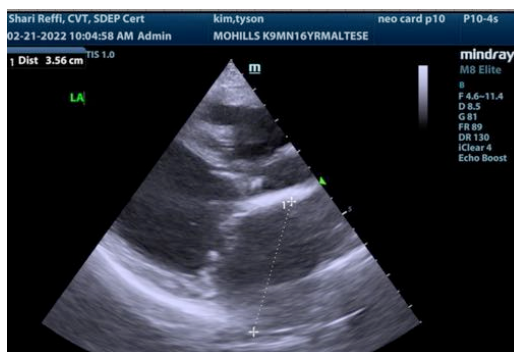
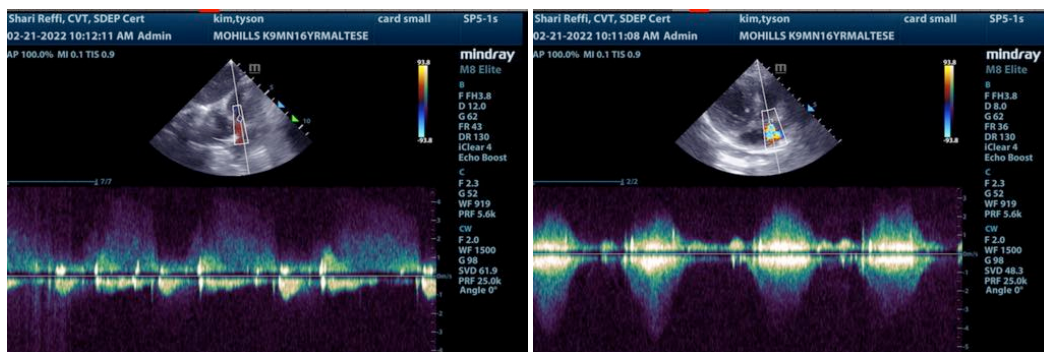
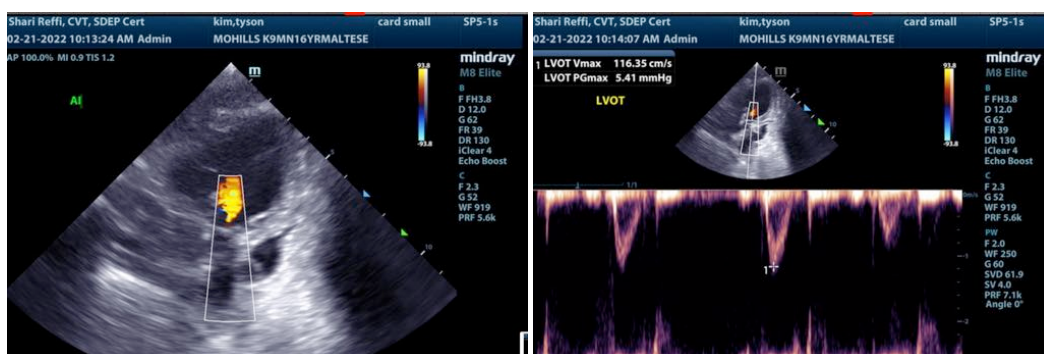
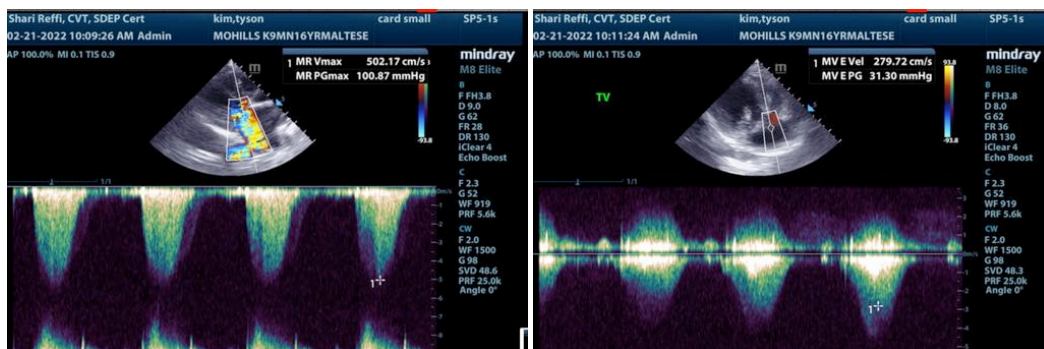
REFERRING VET

Dr. Hirshenson

INVOICE

DATE

2/21/22



The information and recommendations provided are based on the images presented by the referring veterinarian. No evaluation can be communicated regarding pathology that was not visible in the image/video clips provided.

Thank you for this referral. If the clinical or image interpretation does not parallel your findings or if I can be of any further assistance please contact me.



PATIENT

Tyson Kim

Eric Lindquist, DMV, DABVP, Cert. IVUSS, CEO of SonoPath.com
info@SonoPath.com

SPECIES

Canine

BREED

Maltese

SEX

Neutered Male

AGE

16 Years

WEIGHT

11.8 Lbs.

INTERPRETED BY

Eric Lindquist, DMV
DABVP, Cert. IVUSS

**IMAGING
PERFORMED BY**

Shari Reffi, CVT

HOSPITAL NAME

Morris Hills VC

REFERRING VET

Dr. Hirshenson

INVOICE

DATE

2/21/22