



PATIENT PRESENTING CLINICAL SIGNS

Kali Wilson History: heart murmur

ULTRASONOGRAPHIC EXAMINATION OF THE HEART

SPECIES

Canine

BREED

Mixed

SEX

Spayed Female

AGE

16 Years

The **left atrium** was excessive in the LA max position. Complete filling of the atrium was noted on color flow assessment of the mitral valve. The cranial and caudal **mitral valve** leaflets presented vegetative thickening consistent with endocardiosis. Mitral valve prolapse was present. Doppler indicated measurable insufficiency. The **left ventricle** presented thicknesses with linear contour and was not dilated nor restricted. The **myocardium** presented normal echogenicity without subjective evidence of significant fibrotic or ischemic disease. **Contractility** of the ventricular walls was adequate and in normal range for this patient evidenced by the fractional shortening measurement and subjective evaluation of the different regions of the myocardium. The **left ventricular outflow** tract demonstrated normal laminar flow and subjective structural integrity. The **right atrium** and auricle revealed normal size, structure and content. No evidence of masses was noted or chamber overload. **Tricuspid** valvular assessment demonstrated adequate linear morphology. The **right ventricle** was of normal size (1/3 diameter of LV), chordae structure, myocardial echogenicity and thickness. **Pulmonic** tract assessment revealed normal valve structure, laminar flow, and diameter (approx.1:1 pa/ao ratio). No visible **pericardial** or free pleura fluid was noted. No echographically detectable evidence of infiltrative disease was visible. The cranial **mediastinum** and **pericardial regions** were free of masses in the visible window.

WEIGHT

N/A

INTERPRETED BY

Eric Lindquist, DMV
DABVP, Cert. IVUSS

IMAGING PERFORMED BY

Diane McFadden

HOSPITAL NAME

Blairstown AH

CANINE	MR	TR	LA/AO	LA/AO	FS	EF	EPSS
CARDIAC PARAMETERS	VMAX (m/s)	VMAX (m/s)	(Boon method)	(Heart Base; Swe)	(%)	(%)	(cm)
NORMAL PARAMETER	4.5-5.5	<2.7	1.3	<1.6	28-40	40-100	<0.6
PATIENT	6.0		1.3	1.23	42	74	NM
CANINE	HR	AV	PV	BODY WEIGHT	LA	LVIDd	LVIDs
CARDIAC PARAMETERS	(BPM)	VMAX (m/s)	MAX (m/s)	(kg)	2D short axis Base view (cm)	Avg; 2D and m-mode short axis (cm)	Avg; 2D and m-mode short axis (cm)
NORMAL PARAMETER	50-100	0.7-1.7	0.7-1.6	BELOW	BELOW	BELOW	BELOW
PATIENT	164	1.3			4.4	3.64	

REFERRING VET

Dr. Lovell

INVOICE

ULTRASONOGRAPHIC FINDINGS

- Mitral insufficiency.
- Mild left atrial enlargement.
- Early Stage B2 valvular disease.

INTERPRETATION OF THE FINDINGS & FURTHER RECOMMENDATIONS

DATE

2/21/22

LA max is the most reliable position for left atrial enlargement in this particular patient. I recommend initiating Pimobendan at 0.3 mg/kg b.i.d. assuming vertebral heart score is excessive on radiographs.



PATIENT

Kali Wilson

B2: The heart is in a somewhat precarious state with volume overload and a heart that is working to compensate for the valvular insufficiency. Target respiratory rate is < 20 resp/minute after therapy. After initiating therapy, I recommend recheck on the clinical exam, BUN, Creatinine, USG, Chest radiographs & Blood pressure in 5-7 days. Recheck echo in 1 month. Earlier if clinical decompensation is occurring. I do not recommend anesthesia at this time until stabilization has occurred on the recommended medications. Repeat pre-anesthetic echo is ideal if anesthesia is eventually necessary.

SPECIES

Canine

BREED

Mixed

SEX

Spayed Female

AGE

16 Years

WEIGHT

N/A

INTERPRETED BY

Eric Lindquist, DMV
DABVP, Cert. IVUSS

IMAGING PERFORMED BY

Diane McFadden

HOSPITAL NAME

Blairstown AH

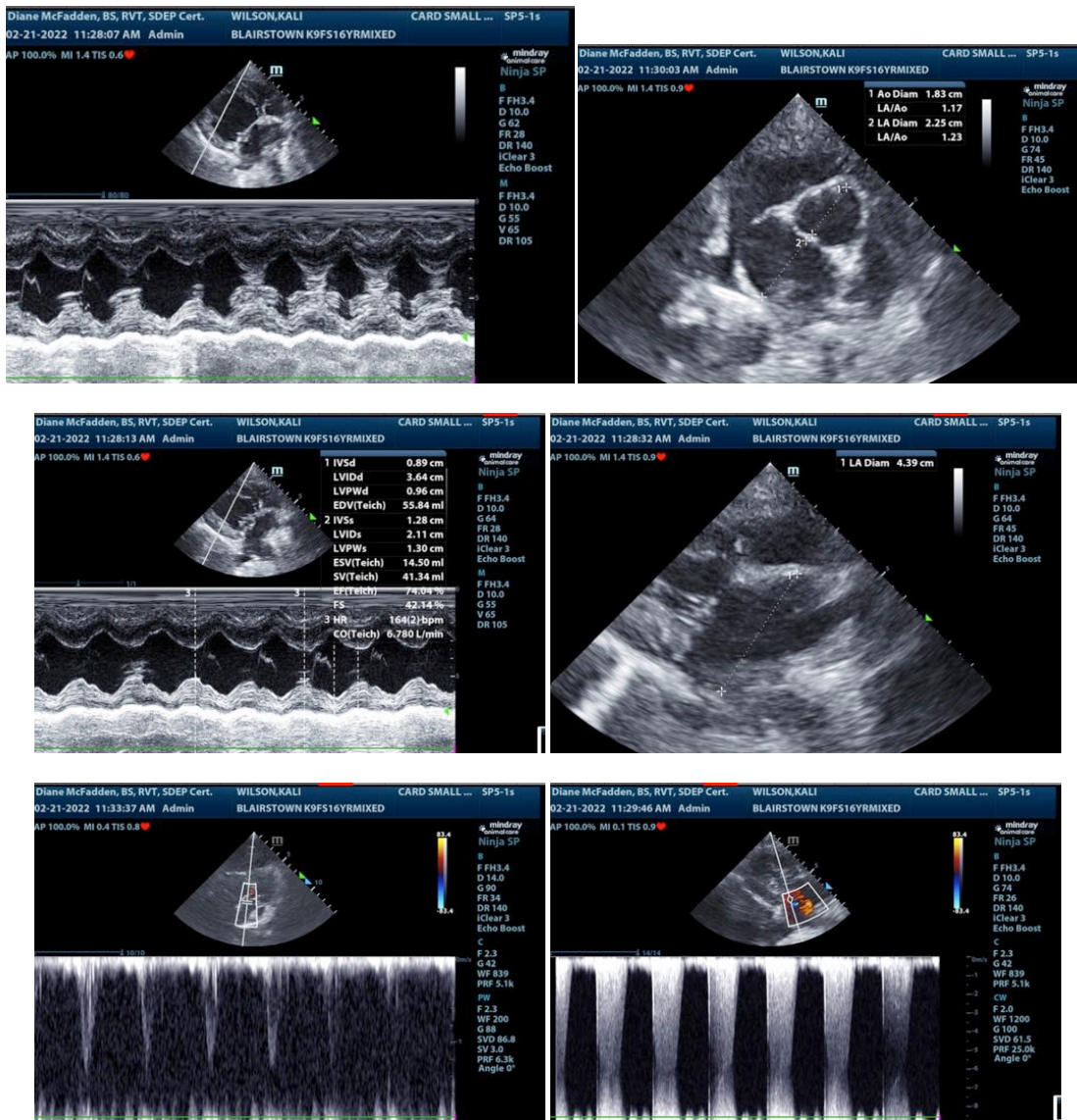
REFERRING VET

Dr. Lovell

INVOICE

DATE

2/21/22





PATIENT

Kali Wilson

SPECIES

Canine

BREED

Mixed

SEX

Spayed Female

AGE

16 Years

WEIGHT

N/A

INTERPRETED BY

Eric Lindquist, DMV
DABVP, Cert. IVUSS

IMAGING PERFORMED BY

Diane McFadden

HOSPITAL NAME

Blairstown AH

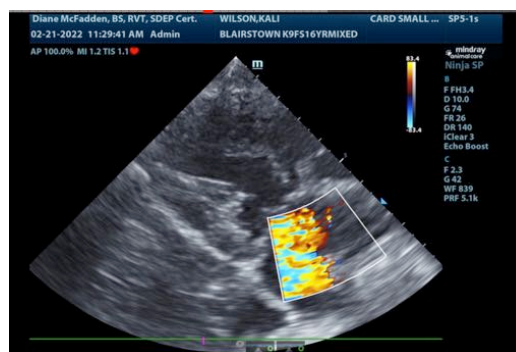
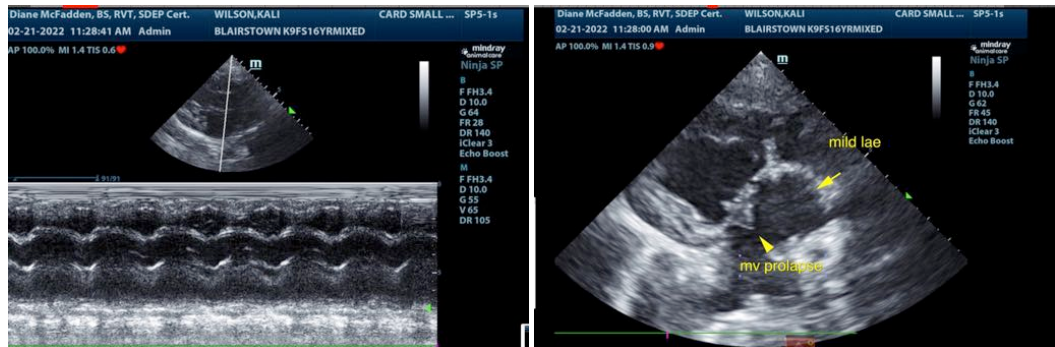
REFERRING VET

Dr. Lovell

INVOICE

DATE

2/21/22



The information and recommendations provided are based on the images presented by the referring veterinarian. No evaluation can be communicated regarding pathology that was not visible in the image/video clips provided.

Thank you for this referral. If the clinical or image interpretation does not parallel your findings or if I can be of any further assistance please contact me.

Eric Lindquist, DMV, DABVP, Cert. IVUSS, CEO of SonoPath.com
info@SonoPath.com