



## PATIENT

Tobi Arnold

## SPECIES

Feline

## BREED

Ragdoll

## SEX

Neutered Male

## AGE

6 Years

## WEIGHT

7.1 lbs

## INTERPRETED BY

Eric Lindquist, DMV,  
DABVP (CFM), Cert.  
IVUSS

## IMAGING PERFORMED BY

Dr. Renee Ziegler Post

## HOSPITAL NAME

For Cats Only  
Veterinary Clinic

## REFERRING VET

Dr. Renee Ziegler Post

## INVOICE

73138

## DATE

2/20/26

## PRESENTING CLINICAL SIGNS

LIMITED echo d/t patient condition. Feb 4 presented to previous vet for labored breathing. Radiographs read as unstructured alveolar and interstitial pattern, possible left sided cardiomegaly. T4 1.3 and chem, CBC unremarkable. This from owner history: Our cat was diagnosed with fluid around lungs but doctor not sure the cause or how to treat. He prescribed antibiotics and steroid. Tobi has some good days but more bad days.

Abnormal PE/Chem/CBC/UA Results: Unremarkable

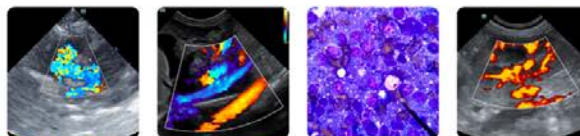
## ULTRASONOGRAPHIC EXAMINATION OF THE HEART

FELINE CARDIAC PARAMETERS	BODY WEIGHT (lbs)	HR (BPM)	IVSd (cm)	LVIDd (cm)	LVWd (cm)	FS (%)	EF (%)
NORMAL PARAMETER	-----	150-240	0.3-0.6	1.0-2.1	0.25-0.6	35-67	80-100
PATIENT	7.1	180	0.5	1.4	0.5	45	--
FELINE CARDIAC PARAMETERS	LA/AO (M-mode)	LA/AO HEART BASE (Sisson)	LAD LA MAX 4 Chamber	LVOT VEL. (m/s)	RVOT VEL. (m/s)	IVRT (m/)	
NORMAL PARAMETER	<1.5	1.6	0.7-1.7	<1.6	<1.3	40-60	
PATIENT	1.4	1.2	1.2	--	--	NM	
Adapted from June Boon, Veterinary Echocardiography, 1998 Sisson D et al. JVIM 1991; 5: 232, Jacobs et al. Am J Vet Res 1985; 46:1705							

EPSS = 0.1

## Cardiac Presentation

The echocardiogram in this patient demonstrated normal **left atrial** size based on 3 separate LA measurements. The cranial and caudal **mitral** valve leaflets presented normal linear structure and kinetics. The **left ventricle** presented normal thicknesses with linear contour and was not dilated nor restricted. The **myocardium** presented normal echogenicity without subjective evidence of significant fibrotic or ischemic disease. **Contractility** of the ventricular walls was adequate and in normal range for this patient evidenced by the fractional shortening measurement and subjective evaluation of the different regions and angles of the myocardium. The **left ventricular outflow** tract demonstrated normal laminar flow and subjective structural integrity. The **right atrium** and auricle revealed normal size, structure and content. No evidence of masses was noted or chamber overload. **Tricuspid** valvular assessment demonstrated adequate linear morphology and kinetics. The **right ventricle** was of normal size (1/3 diameter of LV), chordae structure, myocardial echogenicity and thickness. **Pulmonic** tract assessment revealed normal valve structure, laminar flow, and diameter (approx. 1:1 pa/ao ratio). No visible **pericardial** or free pleura fluid was noted or extra cardiac pathology in the visible planes. The cranial **mediastinum** and **pericardial** regions were free of masses in the visible window.



## PATIENT

Tobi Arnold

## SPECIES

Feline

## BREED

Ragdoll

## SEX

Neutered Male

## AGE

6 Years

## WEIGHT

7.1 lbs

## INTERPRETED BY

Eric Lindquist, DMV,  
DABVP (CFM), Cert.  
IVUSS

## IMAGING PERFORMED BY

Dr. Renee Ziegler Post

## HOSPITAL NAME

For Cats Only  
Veterinary Clinic

## REFERRING VET

Dr. Renee Ziegler Post

## INVOICE

73138

## DATE

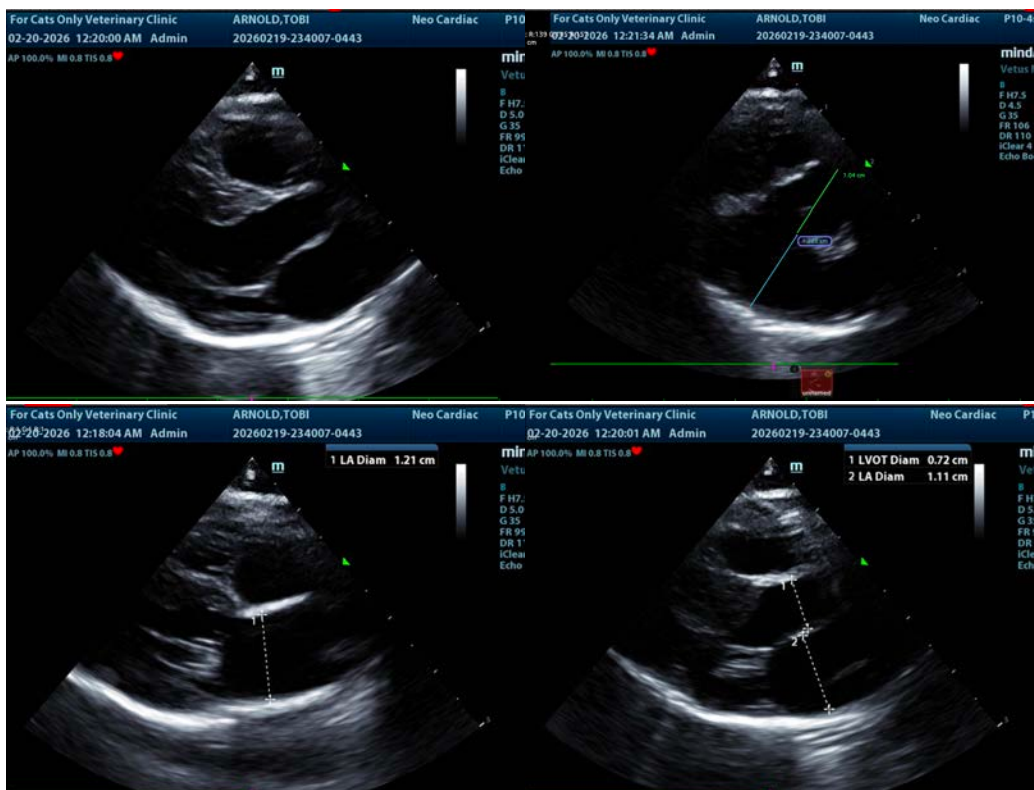
2/20/26

## ULTRASONOGRAPHIC FINDINGS

- Normal echocardiogram.

## INTERPRETATION OF THE FINDINGS & FURTHER RECOMMENDATIONS

No evidence of pathology.



The information and recommendations provided are based on the images presented by the referring veterinarian/sonographer. No evaluation can be communicated regarding pathology that was not visible in the image/video clips provided.

Thank you for this referral. If the clinical or image interpretation does not parallel your findings or if I can be of any further assistance please contact me.

**Eric Lindquist**, DMV, DABVP(CFM), Cert. IVUSS,  
CEO, Owner, Founder -- SonoPath.com  
[info@SonoPath.com](mailto:info@SonoPath.com)