



## PATIENT

Ragnar Agostin

## SPECIES

Feline

## BREED

Siberian

## SEX

Neutered Male

## AGE

6 Years 5 Months

## WEIGHT

13 Pounds 4 Ounces

## INTERPRETED BY

Eric Lindquist, DMV,  
DABVP (Canine &  
Feline), Cert. IVUSS

## IMAGING PERFORMED BY

Heather

## HOSPITAL NAME

ACC Flanders

## REFERRING VET

Dr. Hallihan

## INVOICE

35904

## DATE

2/20/26

## PRESENTING CLINICAL SIGNS

- Office visit on 2/14/26 Heart murmur (new finding) - r/o hypertrophic cardiomyopathy, flow murmur, congenital heart disease.
- Grade 1-2/6 systolic murmur
- Medications: Gabapentin 100mg/ml - Gave 0.6 ml po 2 hours prior to echo
- Abnormal PE/Chem/CBC/UA Results: Bp done on 2/20/26: 123 average - systolic

## ULTRASONOGRAPHIC EXAMINATION OF THE HEART

FELINE CARDIAC PARAMETERS	BODY WEIGHT (kg)	HR (BPM)	IVSd (cm)	LVIDd (cm)	LVWd (cm)	FS (%)	EF (%)
<b>NORMAL PARAMETER</b>	-----	150-240	0.3-0.6	1.0-2.1	0.25-0.6	35-67	80-100
<b>PATIENT</b>	13 lbs 5 oz	200	0.48	1.4	0.56	45	90
FELINE CARDIAC PARAMETERS	LA/AO (M-mode)	LA/AO HEART BASE (Sisson)	LAD LA MAX 4 Chamber		LVOT VEL. (m/s)	RVOT VEL. (m/s)	IVRT (m/)
<b>NORMAL PARAMETER</b>	<1.5	1.6	0.7-1.7		<1.6	<1.3	40-60
<b>PATIENT</b>	1.0	1.2	1.6		1.30	.90	NM
Adapted from June Boon, Veterinary Echocardiography, 1998 Sisson D et al. JVIM 1991; 5: 232, Jacobs et al. Am J Vet Res 1985; 46:1705							

EPSS: 0.1

## Cardiac Presentation

The echocardiogram in this patient demonstrated normal **left atrial** size based on 3 separate LA measurements. Mitral insufficiency was noted on spectral doppler. The **left ventricle** presented normal thicknesses with linear contour and was not dilated nor restricted. The **myocardium** presented normal echogenicity without subjective evidence of significant fibrotic or ischemic disease. **Contractility** of the ventricular walls was adequate and in normal range for this patient evidenced by the fractional shortening measurement and subjective evaluation of the different regions and angles of the myocardium. The **left ventricular outflow** tract demonstrated normal laminar flow and subjective structural integrity. The **right atrium** and auricle revealed normal size, structure and content. No evidence of masses was noted or chamber overload. **Tricuspid** valvular assessment demonstrated adequate linear morphology and kinetics. The **right ventricle** was of normal size (1/3 diameter of LV), chordae structure, myocardial echogenicity and thickness. **Pulmonic** tract assessment



## PATIENT

Ragnar Agostin

## SPECIES

Feline

## BREED

Siberian

## SEX

Neutered Male

## AGE

6 Years 5 Months

## WEIGHT

13 Pounds 4 Ounces

## INTERPRETED BY

Eric Lindquist, DMV,  
DABVP (Canine &  
Feline), Cert. IVUSS

## IMAGING PERFORMED BY

Heather

## HOSPITAL NAME

ACC Flanders

## REFERRING VET

Dr. Hallihan

## INVOICE

35904

## DATE

2/20/26

revealed normal valve structure, laminar flow, and diameter (approx.1:1 pa/ao ratio). No visible **pericardial** or free pleura fluid was noted or extra cardiac pathology in the visible planes. The cranial **mediastinum and pericardial regions** were free of masses in the visible window.

## ULTRASONOGRAPHIC FINDINGS

- Normal echocardiogram with trivial mitral insufficiency.

## INTERPRETATION OF THE FINDINGS & FURTHER RECOMMENDATIONS

No evidence of clinical disease. No therapy is recommended at this time.



**PATIENT**

Ragnar Agostin

**SPECIES**

Feline

**BREED**

Siberian

**SEX**

Neutered Male

**AGE**

6 Years 5 Months

**WEIGHT**

13 Pounds 4 Ounces

**INTERPRETED BY**

Eric Lindquist, DMV,  
DABVP (Canine &  
Feline), Cert. IVUSS

**IMAGING  
PERFORMED BY**

Heather

**HOSPITAL NAME**

ACC Flanders

**REFERRING VET**

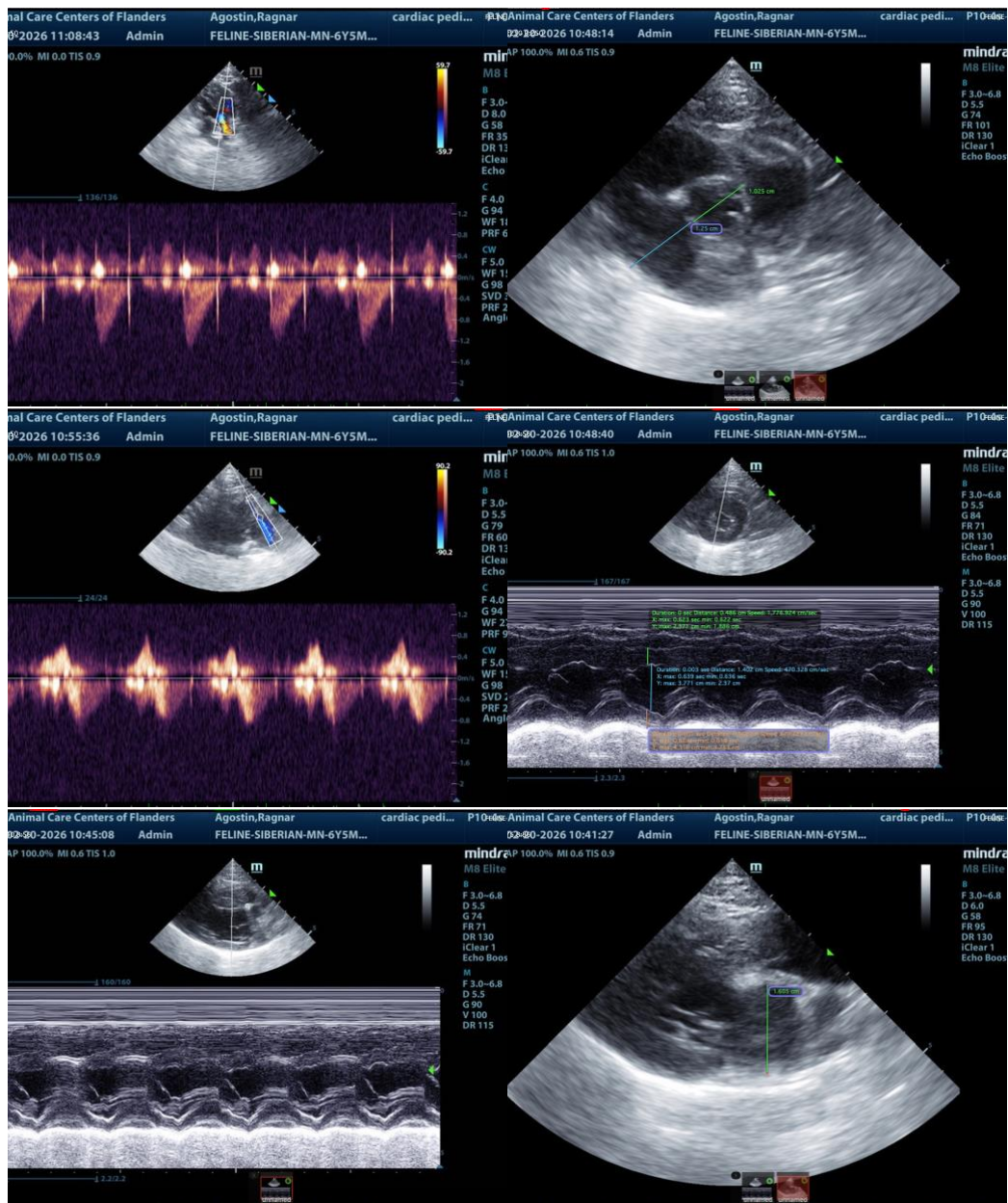
Dr. Hallihan

**INVOICE**

35904

**DATE**

2/20/26



The information and recommendations provided are based on the images presented by the referring veterinarian/sonographer. No evaluation can be communicated regarding pathology that was not visible in the image/video clips provided.

Thank you for this referral. If the clinical or image interpretation does not parallel your findings or if I can be of any further assistance please contact me.

**Eric Lindquist**, DMV, DABVP(CFM), Cert. IVUSS,  
CEO, Owner, Founder -- SonoPath.com



**PATIENT**

[info@SonoPath.com](mailto:info@SonoPath.com)

Ragnar Agostin

**SPECIES**

Feline

**BREED**

Siberian

**SEX**

Neutered Male

**AGE**

6 Years 5 Months

**WEIGHT**

13 Pounds 4 Ounces

**INTERPRETED BY**

Eric Lindquist, DMV,  
DABVP (Canine &  
Feline), Cert. IVUSS

**IMAGING  
PERFORMED BY**

Heather

**HOSPITAL NAME**

ACC Flanders

**REFERRING VET**

Dr. Hallihan

**INVOICE**

35904

**DATE**

2/20/26