



PATIENT

Monty Hargis

SPECIES

Canine

BREED

Miniature Schnauzer

SEX

Neutered Male

AGE

11.7 Years

WEIGHT

15 Pounds

INTERPRETED BY

Eric Lindquist, DMV,
 DABVP(CFM), Cert.
 IUUSS

IMAGING PERFORMED BY

Ginny Dodd, DVM, D,
 ABVP (CFP)

HOSPITAL NAME

All Creatures Pet
 Hospital

REFERRING VET

Dr. Sarah Jenkins

INVOICE

35688

DATE

2/2/26

PRESENTING CLINICAL SIGNS

Weight loss (5#) since 2024), new heart murmur, coughing, retching, normal appetite

Abnormal PE/Chem/CBC/UA Results: PE: BCS 2/9, moderate calculus, 3/6 heart murmur, strong pulses
 CBC- wnl CHEM- Mg 1.7 (N>1.8); CL 107 (N <>108); ALT 290 (N < 121); ALP 192 (N, 160); alb 2.7 (N
 2.7-3.9); UA- 1.025, pH 8.0, Prot +2, dip- WNL; casts 2+ gran, epith +1 T4 total normal.

ULTRASONOGRAPHIC EXAMINATION OF THE HEART

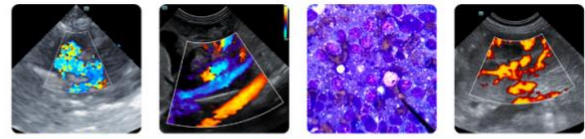
CANINE CARDIAC PARAMETERS	MR VMAX (m/s)	TR VMAX (m/s)	LA/AO (M-Mode)	LA/AO (Heart Base; Swe)	FS (%)	EF (%)	EPSS (cm)
NORMAL PARAMETER	4.5-5.5	<2.7	1.3	Up to 1.6	28-40	40-100	<0.6
PATIENT	--	2.38	1.0	1.4	36	68	0.1
CANINE CARDIAC PARAMETERS	HR (BPM)	AV VMAX (m/s)	PV MAX (m/s)	BODY WEIGHT	LAD LA MAX 4 Chamber	LVIDd Avg; 2D and m-mode short axis (cm)	LVIDs Avg; 2D and m-mode short axis (cm)
NORMAL PARAMETER	50-100	0.7-1.7	0.7-1.6				
PATIENT	129	1.00	1.25	15 lbs	2.0	2.3	--

Cardiac Presentation

The cardiac presentation in this patient presented an extensive infiltrative mass, occupying the heart base. This appears to be deriving from the right atrium or right auricle. The luminal portion of the mass measured 2.0 cm x 1.4 cm, invading into the heart base, however, the mass extended further into the heart base and dorsal thorax, extending completely approximately 5.0+ cm. The mass appears to extend inside and outside of the heart and impinges upon the diaphragm caudally. Slight pericardial effusion was noted with normal left atrium and left ventricle. Mitral insufficiency was noted, not clinically significant. Tricuspid insufficiency was noted. Periodic arrhythmia was noted.

ULTRASONOGRAPHIC FINDINGS

- Thoracic mass involving the heart base and extracardiac space
- Mitral and tricuspid insufficiency
- Slight pericardial effusion
- Periodic arrhythmia



PATIENT

Monty Hargis

SPECIES

Canine

BREED

Miniature Schnauzer

SEX

Neutered Male

AGE

11.7 Years

WEIGHT

15 Pounds

INTERPRETED BY

Eric Lindquist, DMV,
 DABVP(CFM), Cert.
 IVUSS

IMAGING PERFORMED BY

Ginny Dodd, DVM, D,
 ABVP (CFP)

HOSPITAL NAME

All Creatures Pet
 Hospital

REFERRING VET

Dr. Sarah Jenkins

INVOICE

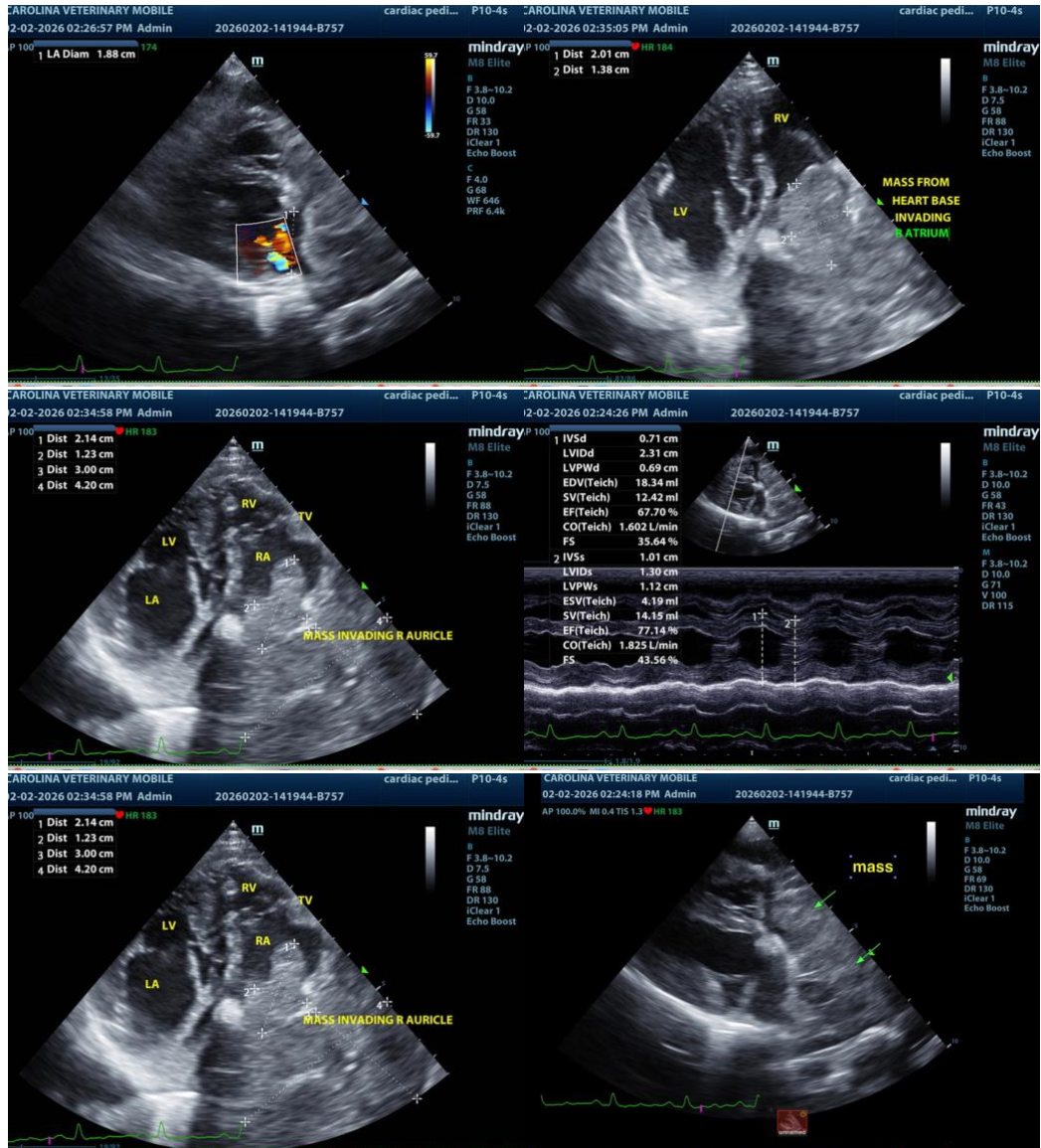
35688

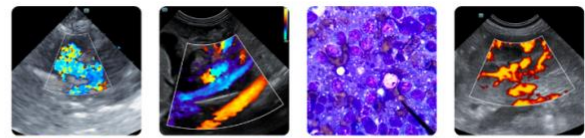
DATE

2/2/26

INTERPRETATION OF THE FINDINGS & FURTHER RECOMMENDATIONS

Ultrasound guided FNA of portions of the mass could be considered if this is potential chemoreducible, as well as abdominal sonogram to assess for passive congestion, secondary ascites, comorbidities or related pathology. Hemangiosarcoma is possible, however, other types of neoplasia, such as fibrosarcoma or chemodectoma could be considered. Cardiology or oncological referral is recommended.





PATIENT

Monty Hargis

SPECIES

Canine

BREED

Miniature Schnauzer

SEX

Neutered Male

AGE

11.7 Years

WEIGHT

15 Pounds

INTERPRETED BY

Eric Lindquist, DMV,
 DABVP(CFM), Cert.
 IVUSS

IMAGING PERFORMED BY

Ginny Dodd, DVM, D,
 ABVP (CFP)

HOSPITAL NAME

All Creatures Pet
 Hospital

REFERRING VET

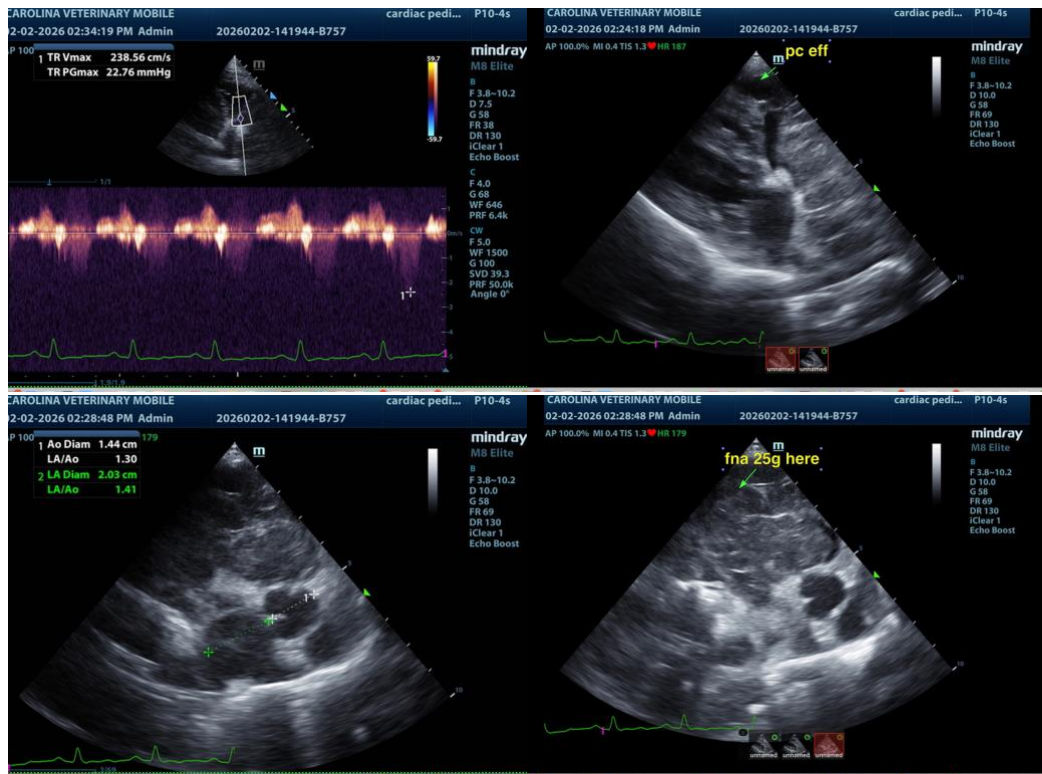
Dr. Sarah Jenkins

INVOICE

35688

DATE

2/2/26



The information and recommendations provided are based on the images presented by the referring veterinarian/sonographer. No evaluation can be communicated regarding pathology that was not visible in the image/video clips provided.

Thank you for this referral. If the clinical or image interpretation does not parallel your findings or if I can be of any further assistance please contact me.

Eric Lindquist, DMV, DABVP(CFM), Cert. IVUSS,
 CEO, Owner, Founder -- SonoPath.com
info@SonoPath.com

Pericardial Effusion and Cardiac Neoplasia

<http://www.sonopath.com/CardiacNeoplasiaEffusion>

Description: The pericardium is a fibrous sac that encloses the heart and the great vessels—aorta, pulmonary artery, proximal pulmonary veins, and vena cava—located at the heart’s base. It is attached caudally to the diaphragm and under normal circumstances contains 1-15 mL of fluid. The latter is comprised of phospholipids that lubricate the heart and allow it to expand and contract without generating friction. The pericardium also fixes the heart, prevents excess motion, and links the diastolic distensibility of the ventricles, thus limiting the degree to which either the left or the right ventricle will distend during diastole. When there are acute changes in venous return (i.e., during exercise), the pericardium plays a critical role in



PATIENT

Monty Hargis

SPECIES

Canine

BREED

Miniature Schnauzer

SEX

Neutered Male

AGE

11.7 Years

WEIGHT

15 Pounds

INTERPRETED BY

Eric Lindquist, DMV,
 DABVP(CFM), Cert.
 IVUSS

IMAGING PERFORMED BY

Ginny Dodd, DVM, D,
 ABVP (CFP)

HOSPITAL NAME

All Creatures Pet
 Hospital

REFERRING VET

Dr. Sarah Jenkins

INVOICE

35688

DATE

2/2/26

limiting ventricular filling. In cases of chronic cardiac enlargement, the pericardium also becomes distended, and its ability to limit ventricular filling, especially when the heart is at rest, becomes compromised. Pericardial tamponade occurs when there is a rapid accumulation of fluid and the pressure inside the pericardium increases significantly. With tamponade, ventricular filling is restricted and cardiac output is decreased. The right atrium and ventricle are the most vulnerable to this condition as these compartments have thinner walls and a lower pressure.

Etiology: Causes of pericardial effusion include:

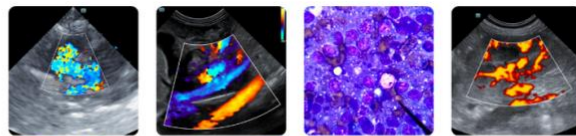
- Neoplasia
 - Right atrial (RA) hemangiosarcoma
 - Heart base (aortic body) tumors
 - Mesothelioma
 - Rhabdomyosarcoma
 - Ectopic thyroid carcinoma
 - Metastatic neoplasia
- Idiopathic
- Congestive heart failure
- Peritoneal-pericardial diaphragmatic hernia
- Pericardial cyst
- Hypoalbuminemia
- Infectious pericarditis (bacterial, *Coccidioides immitis*)
- Feline infectious peritonitis
- Left atrial tear secondary to valvular disease
- Coagulopathy

The majority of neoplastic masses consist of hemangiosarcoma and heart-based tumors (chemodectomas or ectopic thyroid adenocarcinoma). Idiopathic pericardial effusion is a diagnosis of exclusion; the effusion is typically hemorrhagic. Approximately 50% of dogs will be cured with a single pericardiocentesis, while some dogs will require multiple pericardiocenteses as well as surgery. A peritoneal-pericardial diaphragmatic hernia is a congenital hernia seen in dogs and cats in which the abdominal contents (i.e., liver, small intestine, spleen, stomach) herniate into the pericardial sac. Constrictive pericarditis is an uncommon condition in which a non-distensible, thickened, fibrotic pericardium develops over time.

Clinical Signs: One will observe the following clinical signs, which often present in combination: ascites, lethargy, exercise intolerance, pale mucous membranes, weak pulses, *pulsus paradoxus*, and respiratory distress.

Diagnostics: Survey radiographs will reveal hepatomegaly, cardiomegaly (generalized or sectorial globoid), and small pulmonary vessels. Pulmonary edema is typically not found, although one may discover concurrent pulmonary metastatic disease. An ECG will show electrical alternans or small complexes, but often the changes are very subtle and difficult to detect.

Echocardiography is usually considered the gold standard for diagnosing pericardial effusion. Findings include:



PATIENT

Monty Hargis

SPECIES

Canine

BREED

Miniature Schnauzer

SEX

Neutered Male

AGE

11.7 Years

WEIGHT

15 Pounds

INTERPRETED BY

Eric Lindquist, DMV,
 DABVP(CFM), Cert.
 IVUSS

IMAGING PERFORMED BY

Ginny Dodd, DVM, D,
 ABVP (CFP)

HOSPITAL NAME

All Creatures Pet
 Hospital

REFERRING VET

Dr. Sarah Jenkins

INVOICE

35688

DATE

2/2/26

- Anechoic space between the heart and the pericardium.
- Abnormal side-to-side cardiac motion.
- Decreased chamber size (right ventricle [RV] and left ventricle [LV]).
- Presence of a pericardial or cardiac mass.
- Tamponade with early diastolic RA and RV collapse.

Cytology is helpful in the diagnosis of lymphoma, septic pericarditis, and idiopathic effusion, but not in cases of neoplasia.

According to a study that found troponin I levels to be higher in dogs with neoplastic pericardial effusion, the cardiac troponin I assay can be helpful in the diagnosis hemangiosarcoma.

Prognosis:

- Cardiac hemangiosarcoma: < 8 months with surgical debulking and chemotherapy.
- Chemodectoma (aortic derived): MST 730 days post pericardectomy.
- Idiopathic: 50% complete resolution post cardiocentesis; curative with pericardectomy, which can be done via thoracotomy, or thorascopy, or using a balloon to tear the pericardium.
- Mesothelioma: Poor.
- Restrictive pericarditis: Poor, especially when the pericardium has not been surgical stripped.

References:

Cagle LA, Epstein SE, Owens SD, et al. Diagnostic yield of cytology analysis of pericardial effusion in dogs. *J Vet Int Med* 2014;28:66-71.

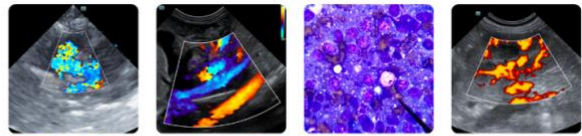
Feigenbaum H. Pericardial disease. In: Feigenbaum H, ed. *Echocardiography, 5th ed.* Philadelphia, PA: Lippincott, Williams & Wilkins; 1994:556-588.

Jackson J, Richter KP, Launer DP. Thorascopic partial pericardectomy in 13 dogs. *J Vet Int Med* 1999;13:529-33.

Johnson MS, Martin M, Binns S. A retrospective study of clinical findings, treatment and outcome in 143 dogs with pericardial effusion. *J Small Anim Prac* 2004;45:546-52.

Kienle RD, Thomas WP. Echocardiography. In: Nyland TG and Mattoon JS, eds. *Small Animal Diagnostic Ultrasound, 2nd ed.* Philadelphia, PA: WB Saunders; 2000:354-423.

Miller MW, Sisson DD. Pericardial disorders. In: Ettinger SJ and Feldman EC, eds. *Textbook of Veterinary Internal Medicine, 5th ed.* Philadelphia, PA: WB Saunders; 2000:923-36.



PATIENT

Monty Hargis

Rajagopalan V, Jesty SA, Craig LE, et al. Comparison of presumptive echocardiographic and definitive diagnoses of cardiac tumors in dogs. *J Vet Int Med* 2013;27:1092-96.

SPECIES

Canine

Shaw SP, Rozanski EA, Ruhs JE. Cardiac troponins I and T in dogs with pericardial effusion. *J Vet Int Med* 2004;18:322-24.

BREED

Miniature Schnauzer

Sidley JA, Atkins CE, Keene BW, et al. Percutaneous balloon pericardiotomy as a treatment for recurrent pericardial effusion in 6 dogs. *J Vet Intern Med* 2002;16:541.

SEX

Neutered Male

Sisson D, Thomas WP. Pericardial disease and cardiac tumors. In: Fox PR, Sisson D, Moise NS, eds. *Textbook of Canine and Feline Cardiology*, 2nd ed. Philadelphia, PA: WB Saunders; 1999:679-701.

AGE

11.7 Years

Sisson D, Thomas WP, Reed J, et al. Intrapericardial cysts in the dog. *J Vet Int Med* 1993;7:364-69.

WEIGHT

15 Pounds

INTERPRETED BY

Eric Lindquist, DMV,
DABVP(CFM), Cert.
IVUSS

**IMAGING
PERFORMED BY**

Ginny Dodd, DVM, D,
ABVP (CFP)

HOSPITAL NAME

All Creatures Pet
Hospital

REFERRING VET

Dr. Sarah Jenkins

INVOICE

35688

DATE

2/2/26