



PATIENT

Abril Carrillo

SPECIES

Canine

BREED

Chihuahua

SEX

Spayed female

AGE

12 years

WEIGHT

6.7 kg

INTERPRETED BY

Eric Lindquist, DMV
DABVP, Cert. IVUSS

IMAGING PERFORMED BY

Dr. Iacovides

HOSPITAL NAME

Tuxedo AH

REFERRING VET

Dr. Lameg (Corydon
AH)

INVOICE

71147

DATE

2/2/26

PRESENTING CLINICAL SIGNS

- Monitoring and sx planning for dental.
- HX of b2 heart disease, on vetmedin, SRR may be slowing creeping up. (18-26)
- cough 1x/week
- New elevation in ALP and pre-existing elevation in ALT, both mild. Moderate elevation in urea and lipase is increased. Pet clinically well with only occasional vomit.
- Grade 4/6 murmur TPR wnl BCS 7/9 Lateral and VD chest x-rays from Jan 22, 2026 attached
CBC: Pltccrit 0.57% (0.14-0.46) CHEM: Urea 17 mmol/l (2.5-9.6) ALT 322 u/l (10-125) ALP 304 u/l (23-212) Bilirubin 6 umol/l (0-15) Lipase 2432 u/l (200-1800) T4 normal

ULTRASONOGRAPHIC EXAMINATION OF THE ABDOMEN

Urinary System

The **urinary bladder**, trigone, and pelvic urethra presented normal thicknesses and normal tone. The ureters were not visible which is normal. No uroliths or sediment were visualized and anechoic urine was present. No evidence of inflammatory or neoplastic changes was noted. Ureteral papillae were normal.

The **kidneys** had thickened irregular cortices, slight pyelectasia and loss of corticomedullary definition. Cortical cysts were noted as well as corticomedullary calculi and pelvic, non-obstructive. A macrocystic change was noted in the left kidney and measured 3.0 cm. The left kidney measured 5.17 cm. The right kidney measured 5.86 cm.

Adrenal Glands

The **adrenal glands** appeared slightly enlarged and swollen. No evidence of focal capsular expansion or invasion into the phrenic veins was noted. No overt suspicion of neoplasia was noted. This is considered likely a hyperplastic change associated with stress or adrenal endocrinopathy (PDH). If isosthenuria is persistently present and the patient morphologically suggests Cushing's disease then ACTH testing would be indicated. The right adrenal gland measured 0.65 cm at the caudal pole and 0.9 cm at the cranial pole. The left adrenal gland measured 0.77 cm at the caudal pole and 0.6 cm at the cranial pole.

Spleen

The **spleen** presented a smooth homogeneous parenchyma hyperechoic to liver and renal cortical parenchyma. The capsule was smooth without noticeable expansion or deviation from within the spleen or adjacent pathology. The splenic vasculature demonstrated normal volume without signs of congestion or thrombosis. No sonographic evidence of acute or chronic inflammatory, neoplastic, or infarctual changes was noted.

Liver

Exam of the cranial abdomen demonstrated excessive **liver** size, swollen contour, with conserved uniform architecture. Parenchymal echogenicity was diffusely isoechoic to the spleen and falciform fat.



PATIENT

Abril Carrillo

SPECIES

Canine

BREED

Chihuahua

SEX

Spayed female

AGE

12 years

WEIGHT

6.7 kg

INTERPRETED BY

Eric Lindquist, DMV
DABVP, Cert. IVUSS

IMAGING PERFORMED BY

Dr. Iacovides

HOSPITAL NAME

Tuxedo AH

REFERRING VET

Dr. Lameg (Corydon
AH)

INVOICE

71147

DATE

2/2/26

Occasional, hypoechoic, non-disruptive nodular change was noted. Occasional, microcystic liver change was noted. Minor excessive GB debris was noted with the presence gall bladder dilation and precipitate without the overt formation of mucocele but this may be an issue in the future. This type of liver presentation typically is associated with slow and gradual SAP elevations with low-grade ALT rise. USG-FNA sampling is encouraged if more aggressive LE profiles are present such as ALT > 200 or rapid rise in SAP. These presentations are usually reactive hepatopathies owing to other disease processes either endocrine (Diabetes, Hypothyroidism, Cushing's disease), "antigen surveillance" from the gut/pancreas, or idiopathic breed predisposed progressions.

Gastrointestinal

Examination of the **gastrointestinal tract** revealed a stomach and intestine free of stasis, of normal wall thickness, acceptable curvilinear mural detail, and peristaltic activity. Small and large intestine demonstrated normal luminal chyme and stool consistency respectively. No obstructive or overt infiltrative disease was noted. No associated abnormal lymphatic activity was noted.

Pancreas

The base and limbs of the **pancreas** were observed to be largely isoechoic to surrounding omental fat. Pancreatic duct and capsular contour were acceptably normal and parenchyma respected normal curvilinear patterns. No overt evidence of active inflammatory or neoplastic disease was noted.

ULTRASONOGRAPHIC FINDINGS

Subjectively benign hepatopathy with nodular changes.

Minor excessive gallbladder debris.

Polycystic kidneys with moderate degenerative changes and calculi.

Bilateral adrenal hypertrophy, potential emerging PDH.

INTERPRETATION OF THE FINDINGS & FURTHER RECOMMENDATIONS

Long term viability of the kidneys and potential underlying PDH/Cushing's are the primary concerns in this patient. Blood pressure measurements and full urinary work-up is warranted. If the patient appears Cushingoid and urine specific gravity is less than 1.020 repeatedly then work-up for PDH is indicated.

Efficient & Accurate Cushing's Work up-Lindquist

Notes regarding Cushing's Clinical Presentations:

Nearly all Cushing's dogs have SAP elevations and true PU/PD (USG < 1.025) and most are polyphagic.

Cushing's dogs are > 6 years and usually > 9 years old, usually have poor skin coats, body scores > 3/5, and are usually sedentary animals.



PATIENT

Abril Carrillo

SPECIES

Canine

BREED

Chihuahua

SEX

Spayed female

AGE

12 years

WEIGHT

6.7 kg

INTERPRETED BY

Eric Lindquist, DMV
DABVP, Cert. IVUSS

IMAGING PERFORMED BY

Dr. Iacovides

HOSPITAL NAME

Tuxedo AH

REFERRING VET

Dr. Lameg (Corydon
AH)

INVOICE

71147

DATE

2/2/26

Its important to remember that Cushing's dogs usually look and play the part and other diseases cause false + stress related cortisol spikes. On rare occasion a Cushing's dog will not follow the rules but this is truly an exception.

Potential Cushing's patient workups can be costly and frustrating if not definitive and, in my experience, the non-definitive patient usually has something else going on that may be contributing to some of the clinical signs a Cushing's dog will have, especially SAP elevations or PU/PD. Based on this prelude of information I came up with the following algorithm in the spirit of diagnostic efficiency. The following suggested protocol is based on current available literature on Cushing's disease and extensive clinical-sonographic experience evaluation + Cushing's and False + LDDST & ACTH stim. cases in order to maximize the efficiency of a Cushing's workup in practice.

Screen first, workup second

1) **UA:** Repeatable (2-3 urine samples) Urine specific gravity & urine cortisol/creatinine ratio (UCCR): If **repeatable USG < 10.20 and + UCCR** move to next step 2.

Note: UA is inexpensive and easy to obtain and if UA criteria is not met for Cushing's then resources can be spent into other more pertinent diagnostics or left on hold until the UA criteria is met in emerging Cushing's cases.

2) **Sonogram:** Does the patient **have concurrent disease** clinically or sonographically as non-Cushing's illness will influence the potential false + LDDST or even ACTH stim. The sonogram gives a global perspective of the internal health of the patient to be considered in the Cushing's workup as an assessment of concurrent disease. Is there a concurrent neoplastic process, UTI pancreatitis, mucocele....? Are the adrenals enlarged (Cushing's-PDH, stress, age related or breed variant), or atrophied (Iatrogenic Cushing's or adrenal burnout), have asymmetric enlargement (Adrenal tumor, hyperplasia, adenoma, age related variant), or is there vascular invasion (Invasive pheo with false + UA criteria or adenocarcinoma or phrenic thrombosis)? The sonogram answers these questions proactively.

Address & treat concurrent disease first before performing Cushing's testing or testing will be artificially altered increasing false negatives and positives.

3) **LDDST** (0.01 D-Sodium phosphate mg/kg IV **with precise dosing******) (Better screening test but plagued with false + but considered more specific than ACTH stim) Use if there is potential early Cushing's or if adrenal asymmetry present on sonogram suspecting tumor. Use LDDST in cats at a higher dose (0.1 mg/kg IV). **Interpretation LDDST:** Look at 8-hour post first: If > 1.4 = Cushing's. Then look at 4-hour: if > 1.4 or > 50% baseline = Cushing's. 4-hour do then 8-hour spike most consistent with PDH. Flat line high constant curve without dip more consistent with tumor but can be PDH. See attached graph.



PATIENT

Abril Carrillo

SPECIES

Canine

BREED

Chihuahua

SEX

Spayed female

AGE

12 years

WEIGHT

6.7 kg

INTERPRETED BY

Eric Lindquist, DMV
DABVP, Cert. IVUSS

IMAGING PERFORMED BY

Dr. Iacovides

HOSPITAL NAME

Tuxedo AH

REFERRING VET

Dr. Lameg (Corydon
AH)

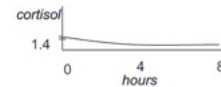
INVOICE

71147

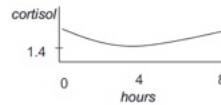
DATE

2/2/26


LDDS



Normal dogs



PDH



Adrenal Tumor
35% PDH

Courtesy: Rebecca Berg DACVIM, DECVIM

4) **ACTH stim.** (Better confirming test but can have false +) Use if the patient “looks” Cushingoid or if bilateral adrenal enlargement is present, or high normal width on sonogram, or if iatrogenic Cushing’s suspected (Cortisone Tx in past). ACTH stim is better for diagnosis of Addison’s, Iatrogenic Cushing’s, and Cushing’s therapy monitoring but problematic with initial Cushing’s diagnosis. First dx LDDST is suggested.

5) If **diabetic** then run both LDDST & ACTH stim but stabilize as much as possible first.

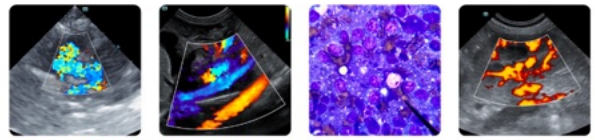
5) Run a **serial blood pressure** in a BP friendly non “white coat effect” atmosphere. Run at least 3 at different times over a few hours or when eating as the patient tends to be calm when eating or give Torbutrol when entering the facility. Cushing’s hypertension is usually 150-180 systolic range while pheochromocytoma range is more often > 180 systolic.

6) **Perform CT** of the pituitary to identify macro adenoma expansion if any lethargy or dullness or other central clinical CNS signs are minimally present. CT for adrenal may be more thorough for adrenalectomy surgical planning if ultrasound views of the CVC were problematic.

7) **Adrenectomy** for adrenal mass is prescribed then it is essential to stabilize the patient first regarding secondary disease such as organ dysfunction, hypertension, diabetes mellitus, hypernatremia, thromboembolic risk urinary and other infection in order to minimize potential for operative and postoperative complications as they are common in adrenalectomy. Trilostane stabilization therapy for Cushing’s would be the first approach then address surgery and hypertension should be managed ideally < 160 systolic with ace inhibitors, phenoxybenzamine, or amlodipine.

Suggested reading:

Behrend EN, Kooistra HS, Nelson R, et al. Diagnosis of Spontaneous Canine Hyperadrenocorticism: 2012 ACVIM Consensus Statement (Small Animal). J Vet Intern Med 2013;27:1292–1304 .



PATIENT

Abril Carrillo

SPECIES

Canine

BREED

Chihuahua

SEX

Spayed female

AGE

12 years

WEIGHT

6.7 kg

INTERPRETED BY

Eric Lindquist, DMV
DABVP, Cert. IVUSS

IMAGING PERFORMED BY

Dr. Iacovides

HOSPITAL NAME

Tuxedo AH

REFERRING VET

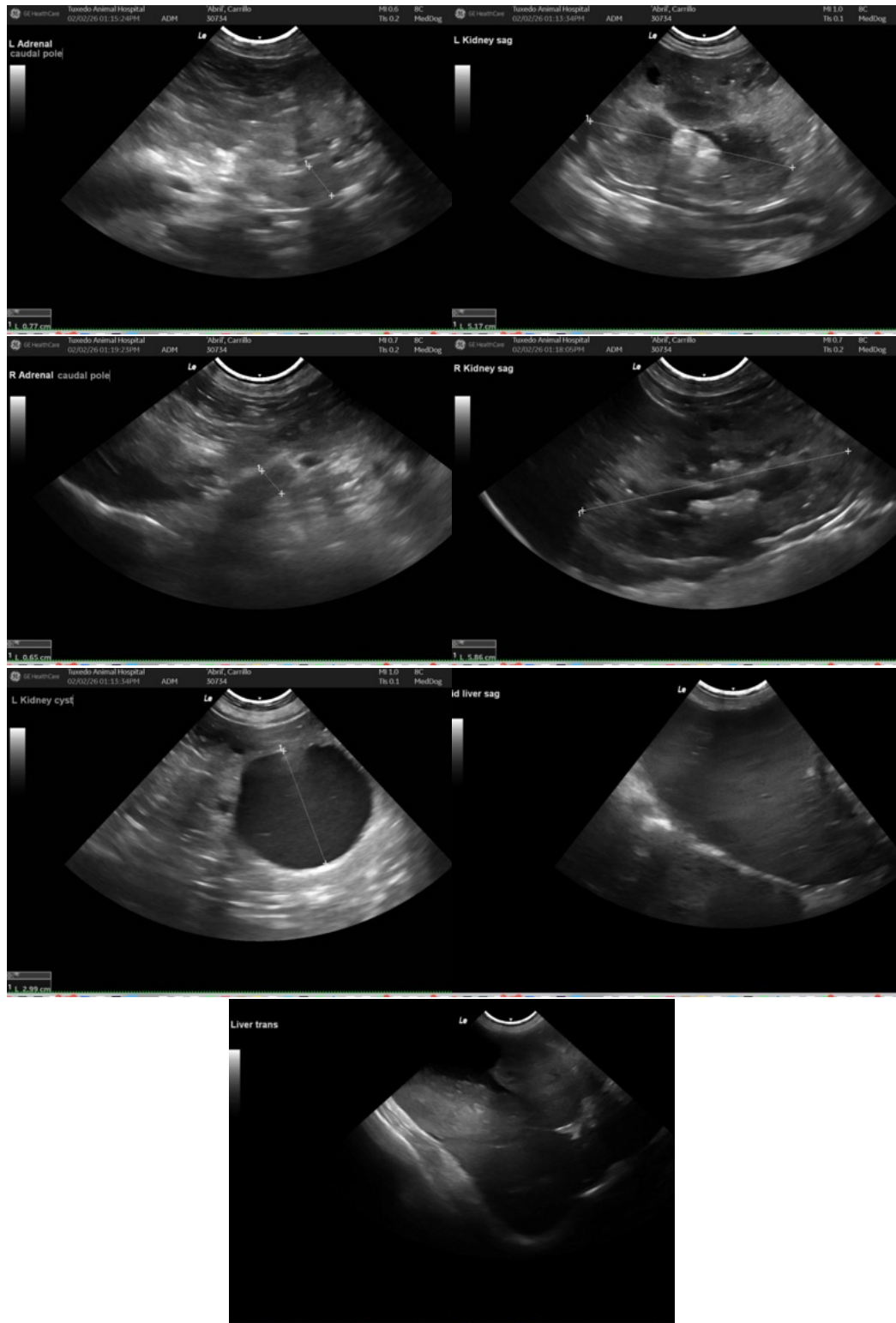
Dr. Lameg (Corydon
AH)

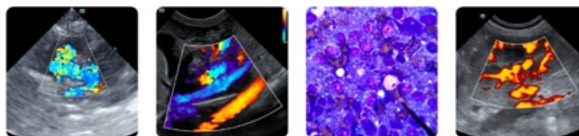
INVOICE

71147

DATE

2/2/26





PATIENT

Abril Carrillo

SPECIES

Canine

BREED

Chihuahua

SEX

Spayed female

AGE

12 years

WEIGHT

6.7 kg

INTERPRETED BY

Eric Lindquist, DMV
DABVP, Cert. IVUSS

IMAGING PERFORMED BY

Dr. Iacovides

HOSPITAL NAME

Tuxedo AH

REFERRING VET

Dr. Lameg (Corydon
AH)

INVOICE

71147

DATE

2/2/26

The information and recommendations provided are based on the images presented by the referring veterinarian/sonographer. No evaluation can be communicated regarding pathology that was not visible in the image/video clips provided.

Thank you for this referral. If the clinical or image interpretation does not parallel your findings or if I can be of any further assistance please contact me.

Eric Lindquist, DMV, DABVP (CFM), Cert. IVUSS, CEO of SonoPath.com

info@SonoPath.com