



**PATIENT PRESENTING CLINICAL SIGNS**

**PATIENT** Phil Aldi History: presented for dental cleaning and skin mass removal doing well at home no v/d/c/s eating and drinking normal

**SPECIES** Abnormal PE/Chem/CBC/UA Results: grade 3 heart murmur chem : high alt 124 , alp 1313 xray : normal heart size , normal pulmonary parenchyma xray of abdomen shows hepatomegaly

Canine

**ULTRASONOGRAPHIC EXAMINATION OF THE HEART**

**BREED**

Cocker Spaniel

**SEX**

Neutered male

**AGE**

12 years

**WEIGHT**

35 lbs

The echocardiogram in this patient demonstrated normal **left atrial** size based on 3 different LA measurement methods. Chamber volumes and echogenicity were normal. The cranial and caudal **mitral** valve leaflets presented vegetative thickening consistent with endocardiosis. Doppler indicated measurable insufficiency. The mitral insufficiency was centralized. The **left ventricle** presented thicknesses with linear contour and was not dilated nor restricted. The **myocardium** presented normal echogenicity without subjective evidence of significant fibrotic or ischemic disease. **Contractility** of the ventricular walls was adequate and in normal range for this patient evidenced by the fractional shortening measurement and subjective evaluation of the different regions of the myocardium. The **left ventricular outflow** tract demonstrated normal laminar flow and subjective structural integrity. The **right atrium** and auricle revealed normal size, structure and content. No evidence of masses was noted or chamber overload. **Tricuspid** valvular assessment demonstrated adequate linear morphology. The **right ventricle** was of normal size (1/3 diameter of LV), chordae structure, myocardial echogenicity and thickness. **Pulmonic** tract assessment revealed normal valve structure, laminar flow, and diameter (approx. 1:1 pa/ao ratio). No visible **pericardial** or free pleura fluid was noted. No echographically detectable evidence of infiltrative disease was visible. The cranial **mediastinum and pericardial regions** were free of masses in the visible window.

**INTERPRETED BY**

Eric Lindquist, DMV  
DABVP, Cert. IVUSS

**IMAGING PERFORMED BY**

Dr. Gabriel

**HOSPITAL NAME**

Central Jersey AH

**REFERRING VET**

Dr. Gabriel

**INVOICE**

42536

**DATE**

2/2/23

CANINE CARDIAC PARAMETERS	MR VMAX (m/s)	TR VMAX (m/s)	LA/AO (Boon method)	LA/AO (Heart Base;)	FS (%)	EF (%)	EPSS (cm)
NORMAL PARAMETER	4.5-5.5	<2.7	1.3	<1.6	28-40	40-100	<0.6
PATIENT			1.2	1.3	47	80	NM
CANINE CARDIAC PARAMETERS	HR (BPM)	AV VMAX (m/s)	PV MAX (m/s)	BODY WEIGHT	LA 2D short axis Base view (cm)	LVIDd Avg; 2D and m-mode short axis (cm)	LVIDs Avg; 2D and m-mode short axis (cm)
NORMAL PARAMETER	50-100	0.7-1.7	0.7-1.6	BELOW	BELOW	BELOW	BELOW
PATIENT			1.4	35 lbs	3.18	3.64	



**PATIENT**

Phil Aldi

**ULTRASONOGRAPHIC EXAMINATION OF THE ABDOMEN**

**Urinary System**

**SPECIES**

Canine

The **urinary bladder**, trigone, and pelvic urethra presented normal thicknesses and normal tone. The pelvic urethra was imaged 2.0 cm beyond the cystourethral junction and appeared normal. The ureters were not visible which is normal. No uroliths or sediment were visualized and anechoic urine was present. No evidence of inflammatory or neoplastic changes was noted. Ureteral papillae were normal.

**BREED**

Cocker Spaniel

The residual prostate measured 0.7 cm.

**SEX**

Neutered male

The **kidneys** revealed largely normal size and structure, corticomedullary definition and ratio (cortex 1/3 of medulla) were essentially maintained with some age-related loss of curvilinear patterns regarding the capsule and C/M junction. The cortices presented largely uniform texture with some increased echogenicity expected for his age patient. Medullary structure differed distinctly from that of the cortex and no evidence of pelvic dilation was present. The left kidney measured 4.0 cm. The right kidney measured 4.0 cm.

**AGE**

12 years

**Adrenal Glands**

**WEIGHT**

35 lbs

Both **adrenal glands** were visualized and recognized as having normal shape, size, position and echogenicity for this breed. The phrenic vasculature, glandular echogenicity and detail were unremarkable. Capsule, cortex, and medullary definition were normal for this age patient. The left adrenal gland measured 0.7 cm. The right adrenal gland 0.75 cm at the caudal pole and 1.0 cm at the cranial pole.

**INTERPRETED BY**

Eric Lindquist, DMV  
DABVP, Cert. IVUS

**Spleen**

The **spleen** in this patient was mildly enlarged with uniform parenchyma and was folded upon itself cranially. This is a positional variant and is not pathological. There was no evidence of significant disease.

**IMAGING PERFORMED BY**

Dr. Gabriel

**Liver**

**HOSPITAL NAME**

Central Jersey AH

The **liver** was uniformly swollen with minor, excessive gallbladder debris and over distension with dependent and suspended bile without evidence of overt mucocele formation. However, excessive sludge was present. The liver presented coarse architecture with mildly increased portal markings and subtle, mixed echogenic changes. This is consistent with vacuolar hepatopathy and some level of remodeling and history of inflammatory component. Mixed, echogenic nodular changes were noted on the liver and were non-disruptive.

**REFERRING VET**

Dr. Gabriel

**INVOICE**

42536

**Gastrointestinal**

Examination of the **gastrointestinal tract** revealed a stomach and intestine free of stasis, of normal wall thickness, acceptable curvilinear mural detail, and peristaltic activity. Small and large intestine demonstrated normal luminal chyme and stool consistency respectively. No obstructive or overt infiltrative disease was noted. No associated abnormal lymphatic activity was noted.

**DATE**

2/2/23



**PATIENT**

Phil Aldi

**SPECIES**

Canine

**BREED**

Cocker Spaniel

**SEX**

Neutered male

**AGE**

12 years

**WEIGHT**

35 lbs

**INTERPRETED BY**

Eric Lindquist, DMV  
DABVP, Cert. IVUSS

**IMAGING PERFORMED BY**

Dr. Gabriel

**HOSPITAL NAME**

Central Jersey AH

**REFERRING VET**

Dr. Gabriel

**INVOICE**

42536

**DATE**

2/2/23

**Pancreas**

The base and limbs of the **pancreas** were observed to be largely isoechoic to surrounding omental fat. Pancreatic duct and capsular contour were acceptably normal and parenchyma respected normal curvilinear patterns. No overt evidence of active inflammatory or neoplastic disease was noted.

**ULTRASONOGRAPHIC FINDINGS**

Benign hepatopathy, minor remodeling.

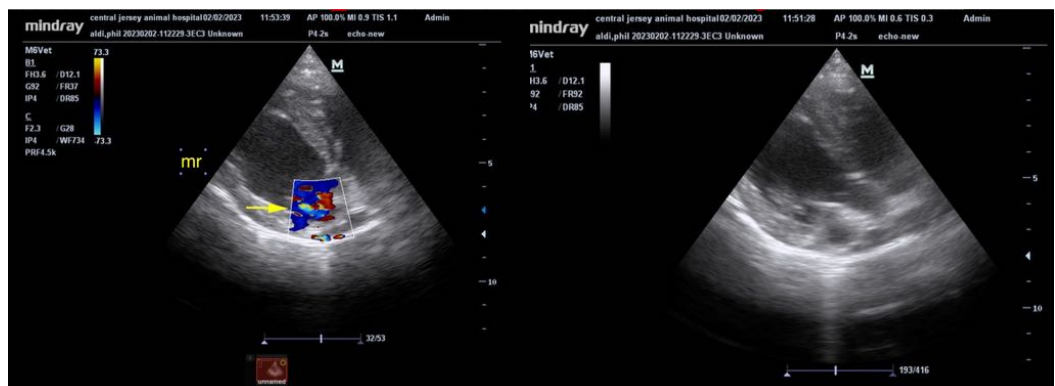Stage B1 valvular disease, no evidence of volume overload.

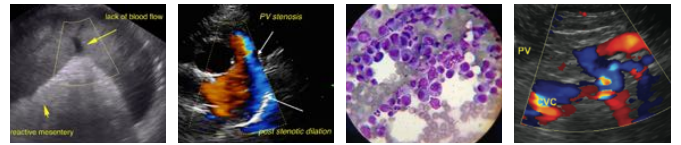
Mitral insufficiency, minor.

**INTERPRETATION OF THE FINDINGS & FURTHER RECOMMENDATIONS**

FNA of the liver is recommended for further definition. No cardiac therapy is recommended at this time.

The heart is stable without clinical disease. No overt contraindication for anesthesia of brief to moderate duration. I suggest Torbutrol premed, Propofol induction, Isoflor maintenance or similar protocol if anesthesia is desired. Blood pressure recommended if not already performed and target white coat negative systolic pressure of < 160 mmHg. If higher than this ACE-inhibitor is suggested to reach this level. Recheck echocardiogram is recommended in 6 months, earlier if murmur grade increases or clinical signs initiate.





**PATIENT**

Phil Aldi

**SPECIES**

Canine

**BREED**

Cocker Spaniel

**SEX**

Neutered male

**AGE**

12 years

**WEIGHT**

35 lbs

**INTERPRETED BY**

Eric Lindquist, DMV  
DABVP, Cert. IVUSS

**IMAGING PERFORMED BY**

Dr. Gabriel

**HOSPITAL NAME**

Central Jersey AH

**REFERRING VET**

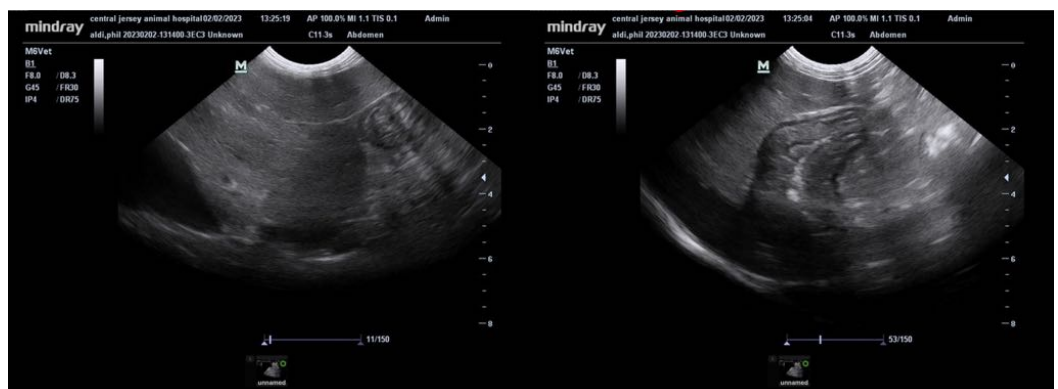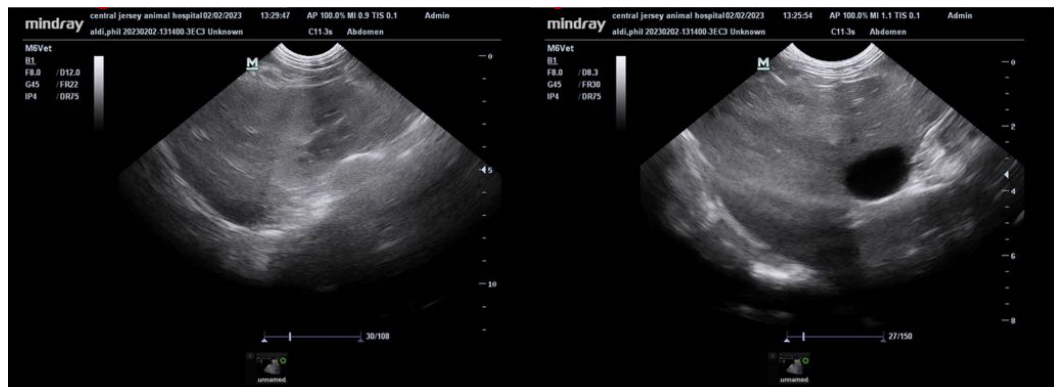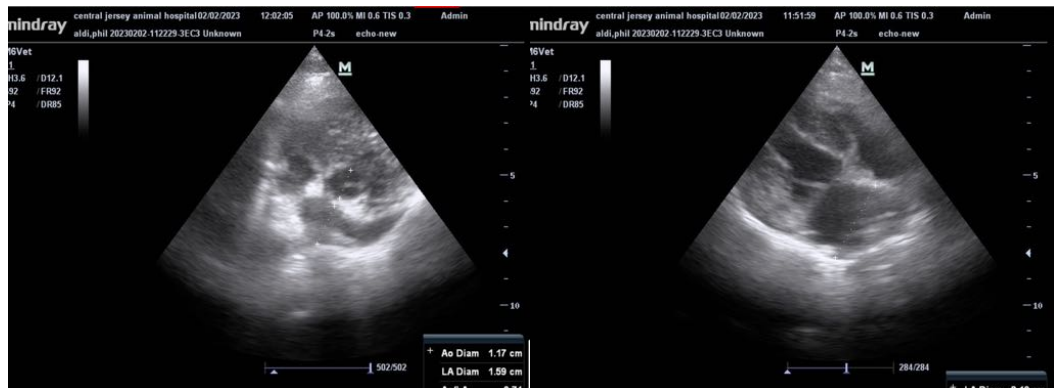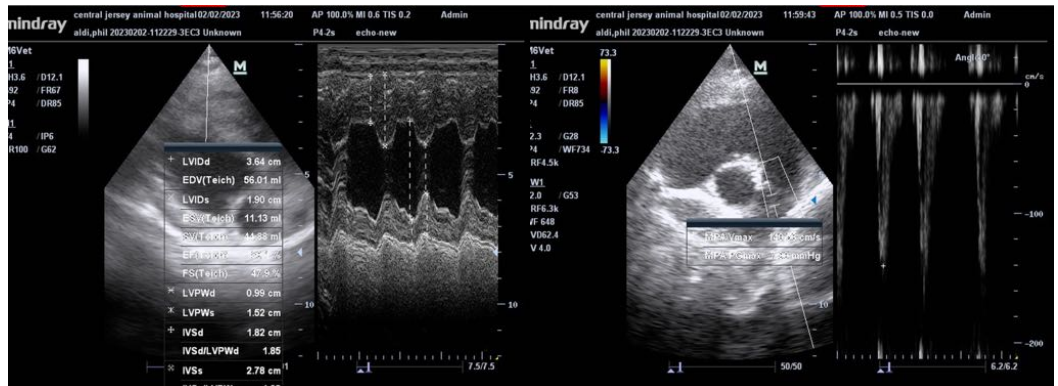
Dr. Gabriel

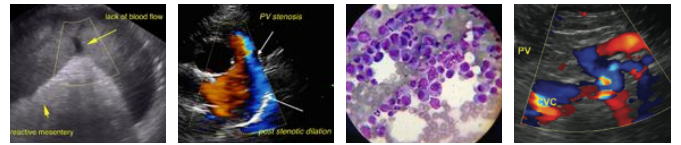
**INVOICE**

42536

**DATE**

2/2/23





**PATIENT**

Phil Aldi

**SPECIES**

Canine

**BREED**

Cocker Spaniel

**SEX**

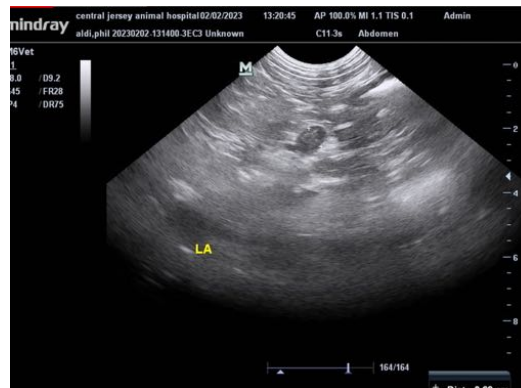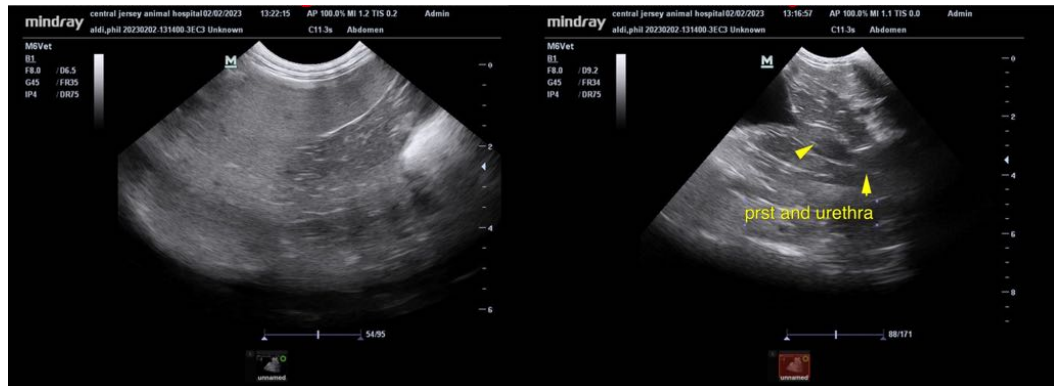Neutered male

**AGE**

12 years

**WEIGHT**

35 lbs



**INTERPRETED BY**

Eric Lindquist, DMV  
DABVP, Cert. IVUSS

**IMAGING PERFORMED BY**

Dr. Gabriel

**HOSPITAL NAME**

Central Jersey AH

**REFERRING VET**

Dr. Gabriel

**INVOICE**

42536

**DATE**

2/2/23

The information and recommendations provided are based on the images presented by the referring veterinarian/sonographer. No evaluation can be communicated regarding pathology that was not visible in the image/video clips provided.

Thank you for this referral. If the clinical or image interpretation does not parallel your findings or if I can be of any further assistance please contact me.

**Eric Lindquist**, DMV, DABVP, Cert. IVUSS, CEO of SonoPath.com  
info@SonoPath.com