



PATIENT

Violet Randav

PRESENTING CLINICAL SIGNS

History: Decreased appetite, hiding, gallop rhythm.

SPECIES

Feline

ULTRASONOGRAPHIC EXAMINATION OF THE ABDOMEN

Urinary System

BREED

Domestic Shorthair

The **urinary bladder**, trigone, and pelvic urethra presented normal thicknesses and normal tone. The pelvic urethra was imaged 3.0 cm beyond the cystourethral junction. The ureters were not visible which is normal. No uroliths or sediment were visualized and anechoic urine was present. No evidence of inflammatory or neoplastic changes was noted. Ureteral papillae were normal.

SEX

Spayed Female

The **kidneys** revealed normal size and structure, corticomedullary definition and ratio for this age. The cortices presented largely uniform texture with normal echogenic relationship to liver and spleen. Medullary structure differed distinctly from the cortex and no evidence of pelvic dilation was present. The capsules were acceptably uniform without significant irregularities. The right kidney measured 3.72 cm. The left kidney measured 3.85 cm.

AGE

6 years

WEIGHT

11.6 lbs

Adrenal Glands

Both **adrenal glands** were visualized and recognized as having normal shape, size, position and echogenicity for this breed. The phrenic vasculature, glandular echogenicity and detail were unremarkable. Capsule, cortex, and medullary definition were normal for this age patient. The left adrenal gland measured 0.27 cm. The right adrenal gland measured 0.28 cm.

INTERPRETED BY

Eric Lindquist, DMV
DABVP, Cert. IVUSS

Spleen

The **spleen** presented a smooth homogeneous parenchyma hyperechoic to liver and renal cortical parenchyma. The capsule was smooth without noticeable expansion or deviation from within the spleen or adjacent pathology. The splenic vasculature demonstrated normal volume without signs of congestion or thrombosis. No sonographic evidence of acute or chronic inflammatory, neoplastic, or infarctual changes was noted.

IMAGING PERFORMED BY

Kelly Vazquez, CVT

HOSPITAL NAME

Animal General on Hudson

Liver

The **liver** was diffusely hyperechoic to the falciform fat with minor, coarse architecture. Generalized hepatomegaly was present. The gallbladder and common bile duct were normal.

REFERRING VET

Dr. Ng

INVOICE

95765

Gastrointestinal

The **stomach** was filled with progressively shadowing material. I suspect hairball accumulation.

DATE

2/2/22



PATIENT

Pancreas

Violet Randav

The **pancreas** was mildly heterogenous and slightly irregular. Subxiphoid palpation is recommended to assess for pain-solicited response. If pain is noted low grade pancreatitis is suspected.

SPECIES

Feline

BREED

Domestic Shorthair

SEX

Spayed Female

AGE

6 years

WEIGHT

11.6 lbs

INTERPRETED BY

Eric Lindquist, DMV
DABVP, Cert. IVUSS

IMAGING PERFORMED BY

Kelly Vazquez, CVT

HOSPITAL NAME

Animal General on Hudson

REFERRING VET

Dr. Ng

INVOICE

95765

DATE

2/2/22

ULTRASONOGRAPHIC EXAMINATION OF THE HEART

The echocardiogram in this patient demonstrated normal **left atrial** size based on 3 separate LA measurements. The cranial and caudal **mitral** valve leaflets presented normal linear structure and kinetics. The **left ventricle** presented normal thicknesses with linear contour and was not dilated nor restricted. The **myocardium** presented normal echogenicity without subjective evidence of significant fibrotic or ischemic disease. **Contractility** of the ventricular walls was adequate and in normal range for this patient evidenced by the fractional shortening measurement and subjective evaluation of the different regions and angles of the myocardium. The **left ventricular outflow** tract demonstrated normal laminar flow and subjective structural integrity. The **right atrium** and auricle revealed normal size, structure and content. No evidence of masses was noted or chamber overload. **Tricuspid** valvular assessment demonstrated adequate linear morphology and kinetics. The **right ventricle** was of normal size (1/3 diameter of LV), chordae structure, myocardial echogenicity and thickness. **Pulmonic** tract assessment revealed normal valve structure, laminar flow, and diameter (approx.1:1 pa/ao ratio). No visible **pericardial** or free pleura fluid was noted or extra cardiac pathology in the visible planes. The cranial **mediastinum** and **pericardial regions** were free of masses in the visible window. Tachycardia was noted.

FELINE CARDIAC PARAMETERS	BODY WEIGHT	HR (BPM)	IVSd (cm)	LVIDd (cm)	LVWd (cm)	FS (%)	EF (%)
NORMAL PARAMETER	-----	150-240	0.3-0.6	1.0-2.1	0.25-0.6	35-67	80-100
PATIENT	11.6 lbs	155	0.59	1.81	0.59	45	79
FELINE CARDIAC PARAMETERS	LA/AO (Boon)	LA/AO HEART BASE (Sisson)	LA 2D 4-chamber long axis AS to FW (Sisson) (cm)	LVOT VEL. (m/s)	RVOT VEL. (m/s)	IVRT (m/)	
NORMAL PARAMETER	<1.5	0.88-1.79	0.7-1.7	<1.6	<1.3	40-60	
PATIENT		1.0		1.0	0.91	NM	
Adapted from June Boon, Veterinary Echocardiography, 1998 Sisson D et al. JVIM 1991; 5: 232, Jacobs et al. Am J Vet Res 1985; 46:1705							



PATIENT

Violet Randav

SPECIES

Feline

BREED

Domestic Shorthair

SEX

Spayed Female

AGE

6 years

WEIGHT

11.6 lbs

INTERPRETED BY

Eric Lindquist, DMV
DABVP, Cert. IVUSS

IMAGING PERFORMED BY

Kelly Vazquez, CVT

HOSPITAL NAME

Animal General on
Hudson

REFERRING VET

Dr. Ng

INVOICE

95765

DATE

2/2/22

ULTRASONOGRAPHIC FINDINGS

Normal echocardiogram with tachycardia.

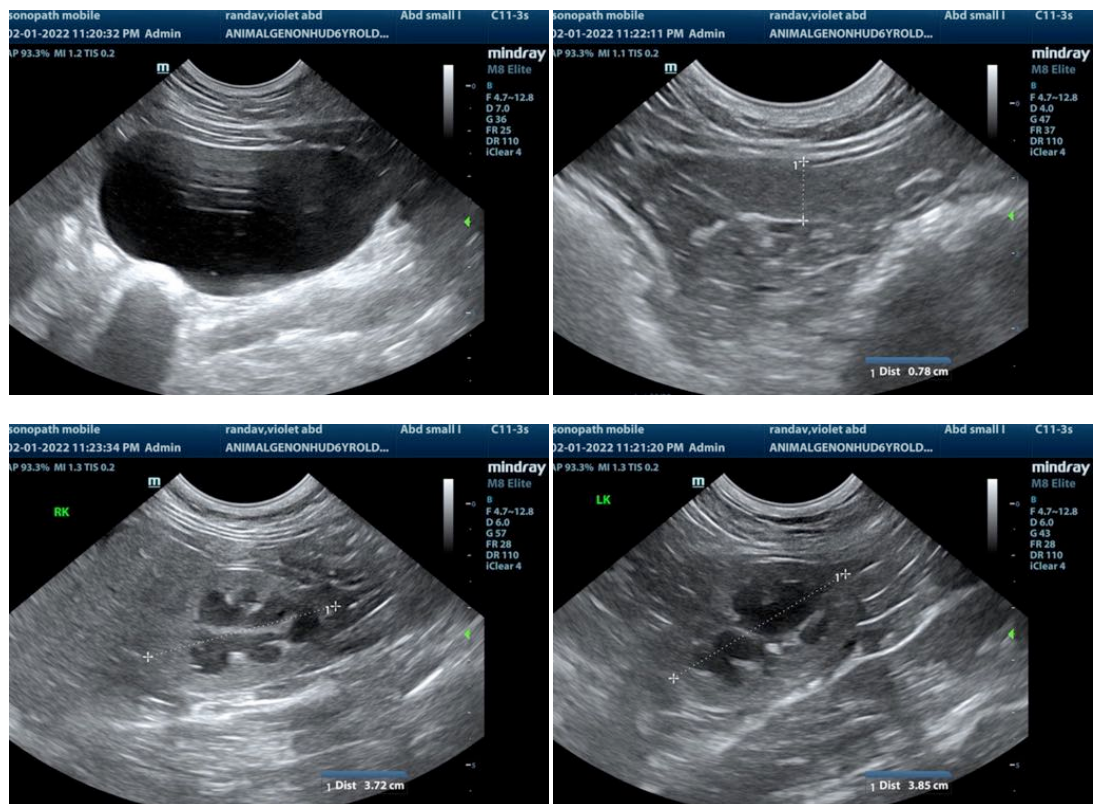
Possible low-grade pancreatitis.

Hairball accumulation.

INTERPRETATION OF THE FINDINGS & FURTHER RECOMMENDATIONS

EKG is warranted. There was no evidence of structural or functional cardiac disease.

From a sonographic standpoint there is a potential for low-grade pancreatitis and hairball accumulation may be responsible for the poor appetite. Otherwise, there is no evidence of pathology.





PATIENT

Violet Randav

SPECIES

Feline

BREED

Domestic Shorthair

SEX

Spayed Female

AGE

6 years

WEIGHT

11.6 lbs

INTERPRETED BY

Eric Lindquist, DMV
DABVP, Cert. IVUSS

IMAGING PERFORMED BY

Kelly Vazquez, CVT

HOSPITAL NAME

Animal General on
Hudson

REFERRING VET

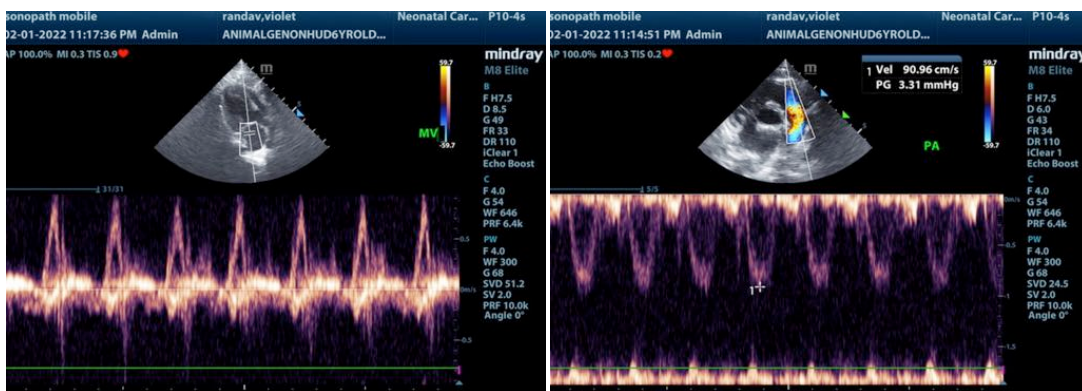
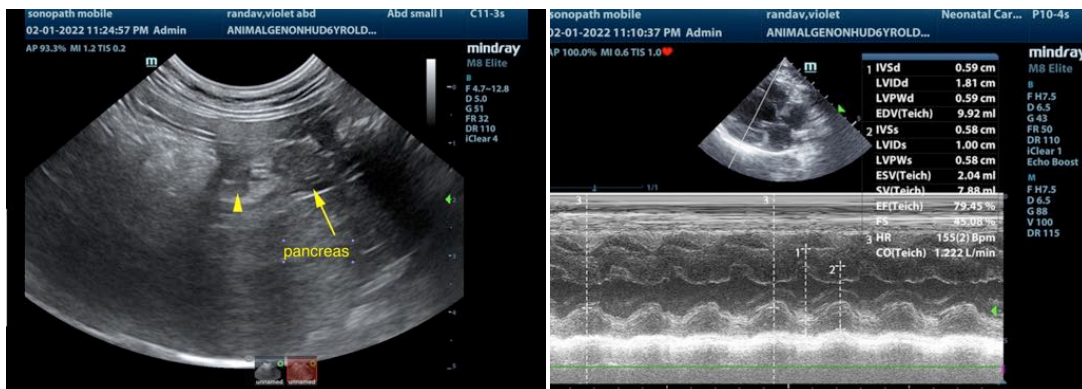
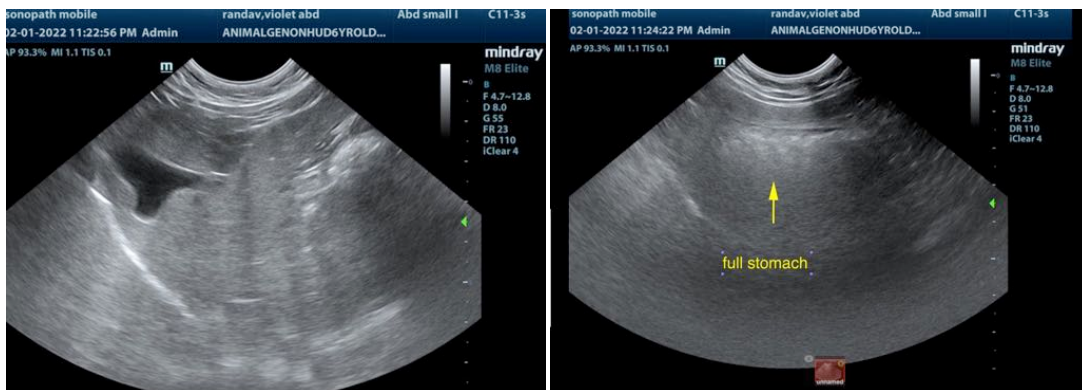
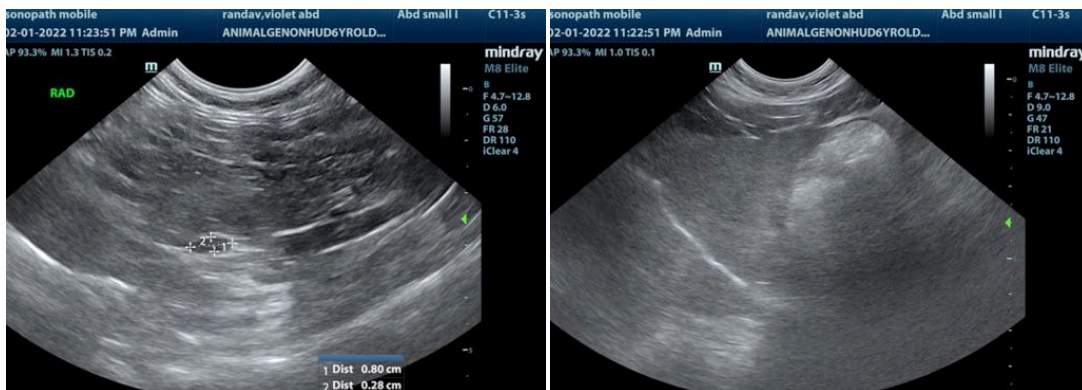
Dr. Ng

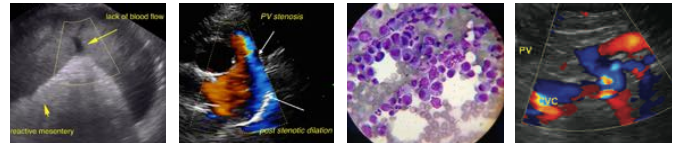
INVOICE

95765

DATE

2/2/22





PATIENT

Violet Randav

SPECIES

Feline

BREED

Domestic Shorthair

SEX

Spayed Female

AGE

6 years

WEIGHT

11.6 lbs

INTERPRETED BY

Eric Lindquist, DMV
DABVP, Cert. IVUSS

IMAGING PERFORMED BY

Kelly Vazquez, CVT

HOSPITAL NAME

Animal General on
Hudson

REFERRING VET

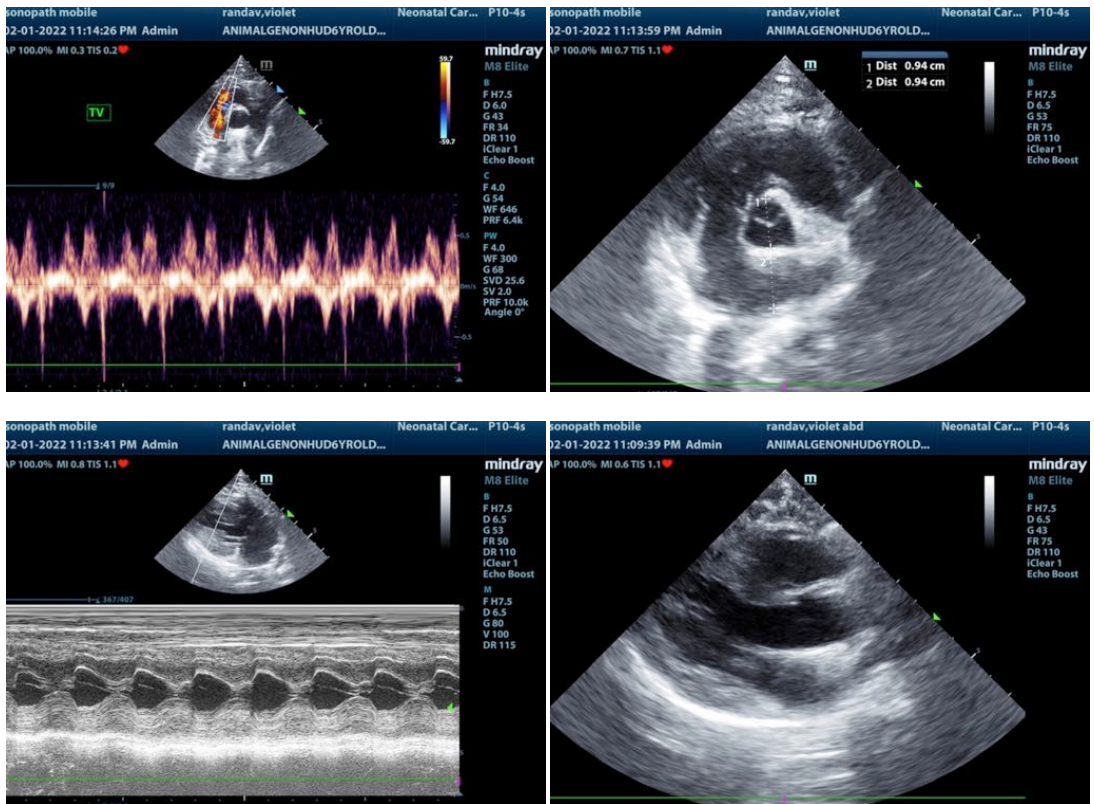
Dr. Ng

INVOICE

95765

DATE

2/2/22



The information and recommendations provided are based on the images presented by the referring veterinarian/sonographer. No evaluation can be communicated regarding pathology that was not visible in the image/video clips provided.

Thank you for this referral. If the clinical or image interpretation does not parallel your findings or if I can be of any further assistance please contact me.

Eric Lindquist, DMV, DABVP, Cert. IVUSS, CEO of SonoPath.com
info@SonoPath.com