



**PATIENT**

Chester Whooley

**PRESENTING CLINICAL SIGNS**

Prev U/S on 1/24/22. No improvement (vomiting, decreased appetite, lethargy)  
Abnormal PE/Chem/CBC/UA Results: N/A

**SPECIES**

Canine

**LIMITED ULTRASONOGRAPHIC EXAMINATION**

**8 videos and 1 still image submitted.**

**BREED**

West Highland White Terrier

A regional portion of jejunum revealed a 0.83 cm x 1.5 cm thickening with loss of structural detail and regional inflammation. Slight mesenteric lymphadenopathy noted, reactive. Variable areas of small intestinal thickening noted elsewhere. However, the area in question meets neoplastic criteria.

**SEX**

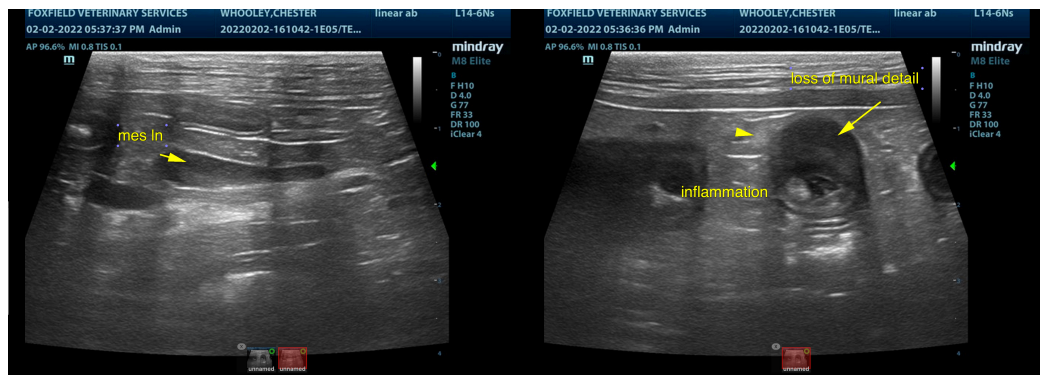
Neutered male

**INTERPRETATION OF THE FINDINGS & FURTHER RECOMMENDATIONS**

Ultrasound guided FNA could be considered, or surgical approach for resection and lymph node biopsy.

**AGE**

12 Years



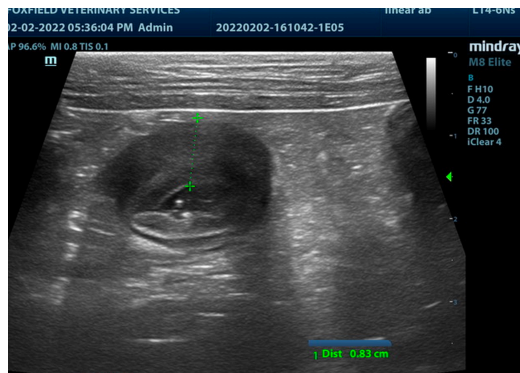**WEIGHT**

21 Pounds

**INTERPRETED BY**

Eric Lindquist, DMV

DABVP, Cert. IVUSS



**IMAGING PERFORMED BY**

Dr. Rodriguez

**HOSPITAL NAME**

Foxfield Vet Services

**REFERRING VET**

Dr. Rodriguez

The information and recommendations provided are based on the images presented by the referring veterinarian/sonographer. No evaluation can be communicated regarding pathology that was not visible in the image/video clips provided.

**INVOICE**

35409

Thank you for this referral. If the clinical or image interpretation does not parallel your findings or if I can be of any further assistance please contact me.

**Eric Lindquist, DMV, DABVP, Cert. IVUSS, CEO of SonoPath.com**

**DATE**

2/2/22

[info@SonoPath.com](mailto:info@SonoPath.com)