



PATIENT

Ally Hernandez

SPECIES

Canine

BREED

Welsh Corgi

SEX

Canine

AGE

8 years

WEIGHT

59 lbs

INTERPRETED BY

Eric Lindquist, DMV
DABVP, Cert. IVUSS

IMAGING PERFORMED BY

Breanna Wokatsch

HOSPITAL NAME

Underdog Pet Rescue

REFERRING VET

Dr. Wokatsch

INVOICE

71767

DATE

2/19/26

PRESENTING CLINICAL SIGNS

- Patient was diagnosed with a mammary carcinoma, owner requesting ultrasound to assess for any internal masses.
- BCS 9/9 Previous chest x-rays show no evidence of metastasis

ULTRASONOGRAPHIC EXAMINATION OF THE ABDOMEN

Urinary System

The **bladder** in this patient was mildly thickened with slight echogenic mural changes. The bladder wall measured 0.78 cm with anechoic urine. No calculi or masses were noted. Slight micropolypoid changes were noted. This is a frequent finding in older animals and may be linked to a history of chronic urinary tract infection or active urinary tract infection. Urinalysis would be recommended with culture if any evidence of inflammatory sediment is present. The region of the trigone and visible pelvic urethra were normal.

The **kidneys** revealed largely normal size and structure, corticomedullary definition and ratio (cortex 1/3 of medulla) were essentially maintained with some age-related loss of curvilinear patterns regarding the capsule and C/M junction. The cortices presented largely uniform texture with some increased echogenicity expected for this age patient. Medullary structure differed distinctly from that of the cortex and no evidence of pelvic dilation was present. Slight mineralization was noted in the kidneys. The left kidney measured 6.45 cm. The right kidney measured 6.6 cm.

Adrenal Glands

Both **adrenal glands** were visualized and recognized as having normal shape, size, position and echogenicity for this breed. The phrenic vasculature, glandular echogenicity and detail were unremarkable. Capsule, cortex, and medullary definition were normal for this age patient. The left adrenal gland measured 0.5 cm. The right adrenal gland measured 0.8 cm.

Spleen

The **spleen** presented a smooth homogeneous parenchyma hyperechoic to liver and renal cortical parenchyma. The capsule was smooth without noticeable expansion or deviation from within the spleen or adjacent pathology. The splenic vasculature demonstrated normal volume without signs of congestion or thrombosis. No sonographic evidence of acute or chronic inflammatory, neoplastic, or infarctual changes was noted.

Liver

The **liver** images submitted revealed subjectively normal liver size, contour, and structure. Parenchymal echogenicity was naturally coarse and hypoechoic to the spleen. Vascular and biliary tracts were of normal volume with no evidence of congestion. The gallbladder presented acceptably thin walls with primarily anechoic content. The cystic and common bile ducts were normal. No pathological hepatic



PATIENT

Ally Hernandez

lymphadenopathy was evident. No overt structural evidence of inflammatory, infiltrative or regenerative pathology was evident.

SPECIES

Canine

Gastrointestinal

Examination of the **gastrointestinal tract** revealed a stomach and intestine free of stasis, of normal wall thickness, acceptable curvilinear mural detail, and peristaltic activity. Small and large intestine demonstrated normal luminal chyme and stool consistency respectively. No obstructive or overt infiltrative disease was noted. No associated abnormal lymphatic activity was noted.

BREED

Welsh Corgi

SEX

Canine

Pancreas

The base and limbs of the **pancreas** were observed to be largely isoechoic to surrounding omental fat. Pancreatic duct and capsular contour were acceptably normal and parenchyma respected normal curvilinear patterns. No overt evidence of active inflammatory or neoplastic disease was noted.

AGE

8 years

WEIGHT

59 lbs

ULTRASONOGRAPHIC FINDINGS

Structurally unremarkable abdomen.

INTERPRETED BY

Eric Lindquist, DMV
DABVP, Cert. IVUSS

INTERPRETATION OF THE FINDINGS & FURTHER RECOMMENDATIONS

There was no evidence of significant disease.

IMAGING PERFORMED BY

Breanna Wokatsch

HOSPITAL NAME

Underdog Pet Rescue

REFERRING VET

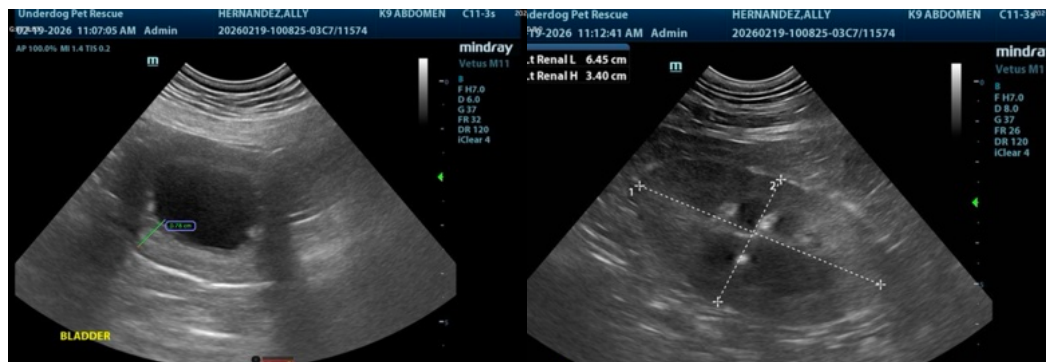Dr. Wokatsch

INVOICE

71767

DATE

2/19/26





PATIENT

Ally Hernandez

SPECIES

Canine

BREED

Welsh Corgi

SEX

Canine

AGE

8 years

WEIGHT

59 lbs

INTERPRETED BY

Eric Lindquist, DMV
DABVP, Cert. IVUSS

IMAGING PERFORMED BY

Breanna Wokatsch

HOSPITAL NAME

Underdog Pet Rescue

REFERRING VET

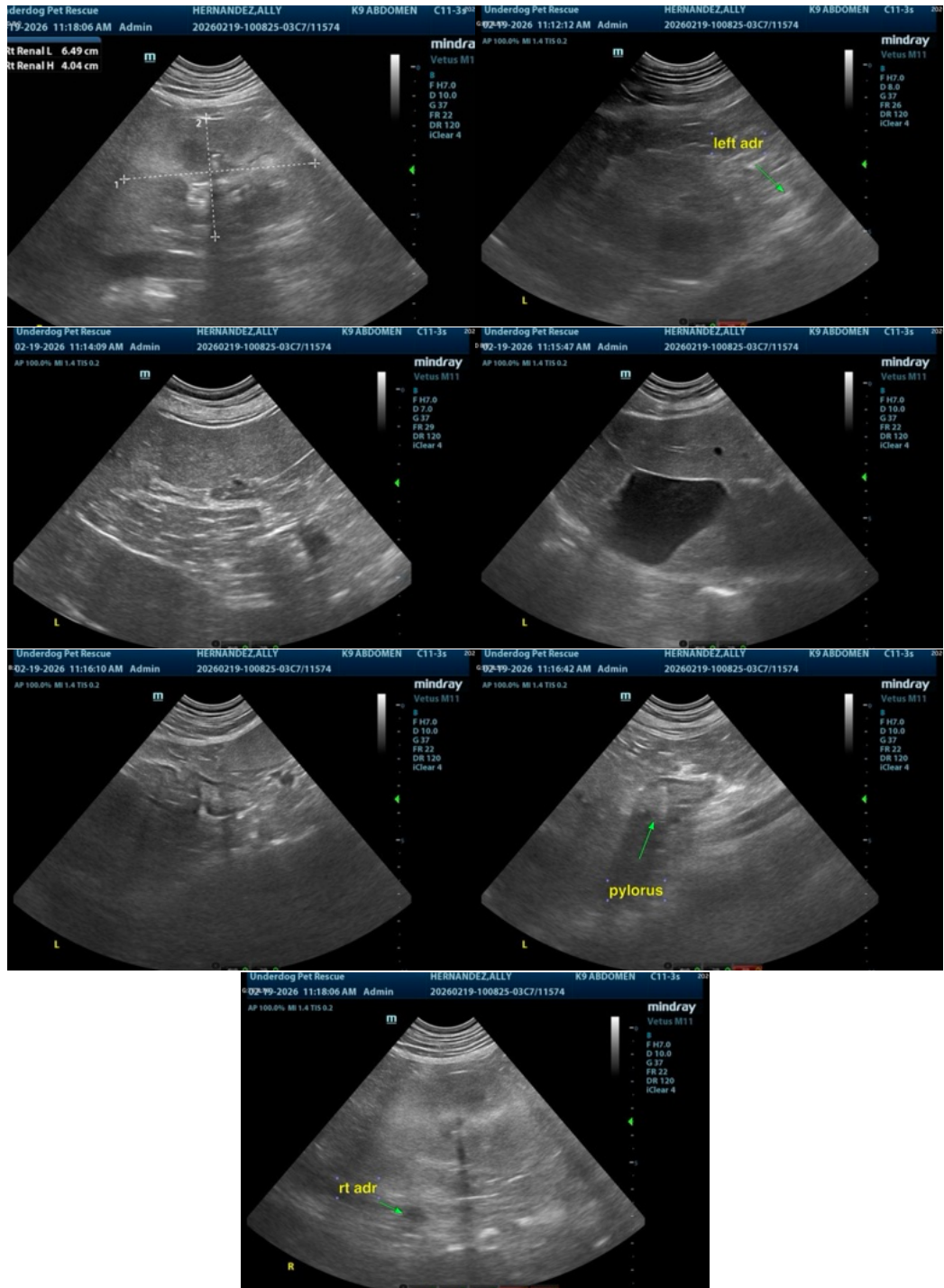
Dr. Wokatsch

INVOICE

71767

DATE

2/19/26



The information and recommendations provided are based on the images presented by the referring veterinarian/sonographer. No evaluation can be communicated regarding pathology that was not visible in the image/video clips provided.



PATIENT

Ally Hernandez

SPECIES

Canine

BREED

Welsh Corgi

SEX

Canine

AGE

8 years

WEIGHT

59 lbs

INTERPRETED BY

Eric Lindquist, DMV
DABVP, Cert. IVUSS

**IMAGING
PERFORMED BY**

Breanna Wokatsch

HOSPITAL NAME

Underdog Pet Rescue

REFERRING VET

Dr. Wokatsch

INVOICE

71767

DATE

2/19/26

Thank you for this referral. If the clinical or image interpretation does not parallel your findings or if I can be of any further assistance please contact me.

Eric Lindquist, DMV, DABVP (CFM), Cert. IVUSS, CEO of SonoPath.com

info@SonoPath.com