



## PATIENT

Yasmin Mohamed Ali

## SPECIES

Feline

## BREED

British Long Hair

## SEX

Female

## AGE

15 Months

## WEIGHT

3.6

## INTERPRETED BY

Eric Lindquist, DMV  
DABVP, Cert. IVUSS

## IMAGING PERFORMED BY

Doctor Valentina

## HOSPITAL NAME

The Veterinary Surgery

## REFERRING VET

Dr. Valentina Fresta

## INVOICE

21194

## DATE

2/19/23

## PRESENTING CLINICAL SIGNS

History: Presented for MCH's and PDK assessment. The owner reports no concerns about Cameron's health. At the Clinical examination the patient is BAR. Heart and lung sound clear. mmc are pink Heart rate 170 RR 32. The rest of the examination is unremarkable. The patient is on raw diet regime along with RC dry food

Abnormal PE/Chem/CBC/UA Results: Cbc reveals normal parameters. The minichemistry reveals slight increased amylasis.

## ULTRASONOGRAPHIC EXAMINATION OF THE HEART

FELINE CARDIAC PARAMETERS	BODY WEIGHT (kg)	HR (BPM)	IVSd (cm)	LVIDd (cm)	LVWd (cm)	FS (%)	EF (%)
NORMAL PARAMETER	-----	150-240	0.3-0.6	1.0-2.1	0.25-0.6	35-67	80-100
PATIENT	--	220	0.31	1.3	0.33	55	--
FELINE CARDIAC PARAMETERS	LA/AO (Boon)	LA/AO HEART BASE (Sisson)	LA 2D 4-chamber long axis AS to FW (Sisson) (cm)	LVOT VEL. (m/s)	RVOT VEL. (m/s)	IVRT (m/)	
NORMAL PARAMETER	<1.5	0.88-1.79	0.7-1.7	<1.6	<1.3	40-60	
PATIENT	1.15	--	1.25	--	--	NM	
Adapted from June Boon, Veterinary Echocardiography, 1998 Sisson D et al. JVIM 1991; 5: 232, Jacobs et al. Am J Vet Res 1985; 46:1705							

## Cardiac Presentation

All four chambers appear to be of normal volume. Cardiac structure is normal with adequate contractility. No gross valvular disease is noted. Pericardial and pleural spaces were unremarkable. NO evidence of cardiac disease. The hepatic veins were not dilated.

## ULTRASONOGRAPHIC FINDINGS

- Normal echocardiogram

## INTERPRETATION OF THE FINDINGS & FURTHER RECOMMENDATIONS

No evidence of pathology.



**PATIENT**

Yasmin Mohamed Ali

**SPECIES**

Feline

**BREED**

British Long Hair

**SEX**

Female

**AGE**

15 Months

**WEIGHT**

3.6

**INTERPRETED BY**

Eric Lindquist, DMV  
DABVP, Cert. IVUSS

**IMAGING PERFORMED BY**

Doctor Valentina

**HOSPITAL NAME**

The Veterinary Surgery

**REFERRING VET**

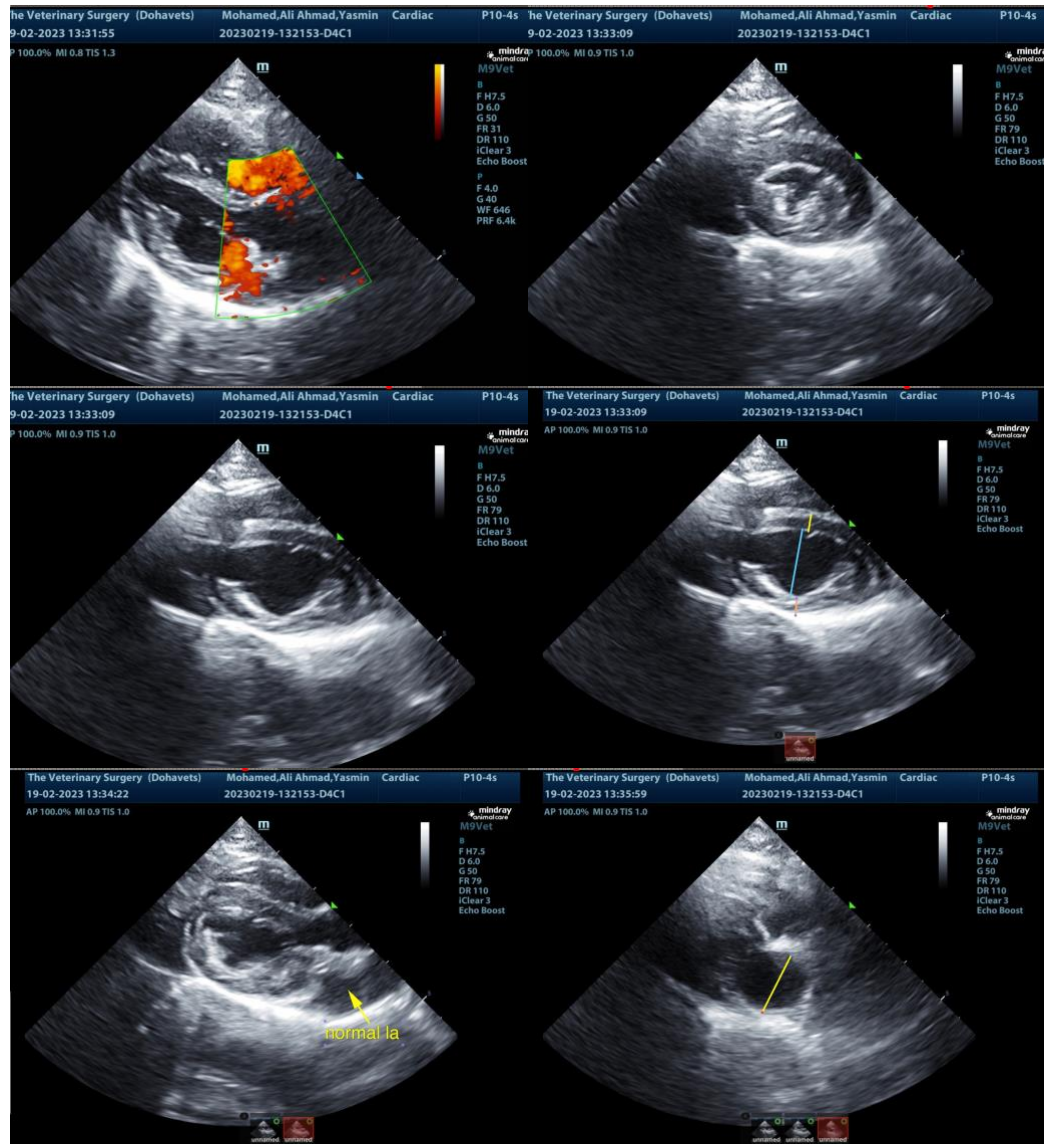
Dr. Valentina Fresta

**INVOICE**

21194

**DATE**

2/19/23



The information and recommendations provided are based on the images presented by the referring veterinarian. No evaluation can be communicated regarding pathology that was not visible in the image/video clips provided.

Thank you for this referral. If the clinical or image interpretation does not parallel your findings or if I can be of any further assistance please contact me.

**Eric Lindquist**, DMV, DABVP, Cert. IVUSS, CEO of SonoPath.com  
info@SonoPath.com