



PATIENT

Cameron/Hamad
Mohamed Ali

SPECIES

Feline

BREED

British Long Hair

SEX

Male

AGE

13 Months

WEIGHT

4.3

INTERPRETED BY

Eric Lindquist, DMV
DABVP, Cert. IVUSS

IMAGING PERFORMED BY

Doctor Valentina

HOSPITAL NAME

The Veterinary Surgery

REFERRING VET

Dr. Valentina Fresta

INVOICE

21193

DATE

2/19/23

PRESENTING CLINICAL SIGNS

History: Presented for MCH's and PDK assessment. The owner reports no concerns about Cameron's health. At the Clinical examination the patient is BAR. Heart and lung sound clear. mmc are pink Heart rate 170 RR 32 .The rest of the examination is unremarkable. The patient is on raw diet regime along with RC dry food

Abnormal PE/Chem/CBC/UA Results: CBC reveals normal parameters. The minichemistry reveal slight increased ALT and BUN.

ULTRASONOGRAPHIC EXAMINATION OF THE HEART

FELINE CARDIAC PARAMETERS	BODY WEIGHT (kg)	HR (BPM)	IVSd (cm)	LVIDd (cm)	LVWd (cm)	FS (%)	EF (%)
NORMAL PARAMETER	-----	150-240	0.3-0.6	1.0-2.1	0.25-0.6	35-67	80-100
PATIENT	--	NM	0.48	1.39	0.5	50	--
FELINE CARDIAC PARAMETERS	LA/AO (Boon)	LA/AO HEART BASE (Sisson)	LA 2D 4-chamber long axis AS to FW (Sisson) (cm)	LVOT VEL. (m/s)	RVOT VEL. (m/s)	IVRT (m/)	
NORMAL PARAMETER	<1.5	0.88-1.79	0.7-1.7	<1.6	<1.3	40-60	
PATIENT	1.0	1.0	--	--	--	NM	
Adapted from June Boon, Veterinary Echocardiography, 1998							
Sisson D et al. JVIM 1991; 5: 232, Jacobs et al. Am J Vet Res 1985; 46:1705							

Cardiac Presentation

The cardiac presentation revealed normal septal and free wall thicknesses. No pericardial or pleural effusion noted. Subjectively, the heart appeared to have adequate contractility.

ULTRASONOGRAPHIC FINDINGS

- Normal echocardiogram

INTERPRETATION OF THE FINDINGS & FURTHER RECOMMENDATIONS

No obvious evidence of congenital disease, however, left ventricular and right ventricular outflow velocities and further doppler evaluation of the valvular apparatuses would be ideal to definitively assess for congenital disease, yet no evidence of clinical cardiac disease is present.



PATIENT

Cameron/Hamad
Mohamed Ali

SPECIES

Feline

BREED

British Long Hair

SEX

Male

AGE

13 Months

WEIGHT

4.3

INTERPRETED BY

Eric Lindquist, DMV
DABVP, Cert. IVUSS

IMAGING PERFORMED BY

Doctor Valentina

HOSPITAL NAME

The Veterinary Surgery

REFERRING VET

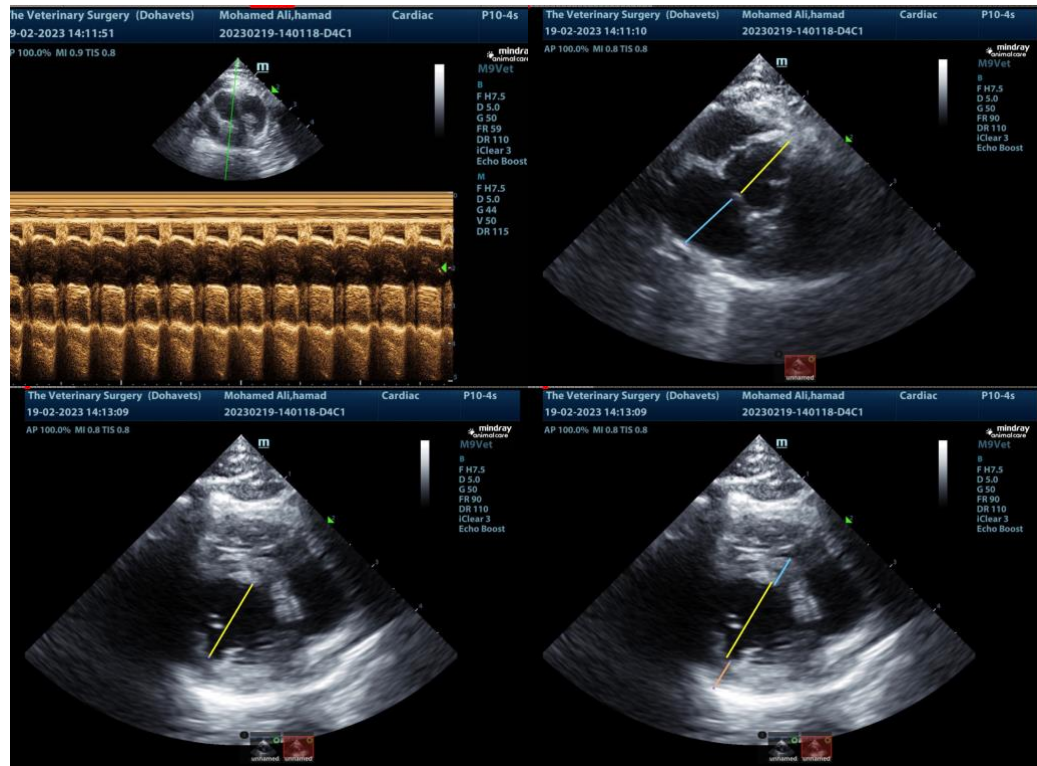
Dr. Valentina Fresta

INVOICE

21193

DATE

2/19/23



The information and recommendations provided are based on the images presented by the referring veterinarian. No evaluation can be communicated regarding pathology that was not visible in the image/video clips provided.

Thank you for this referral. If the clinical or image interpretation does not parallel your findings or if I can be of any further assistance please contact me.

Eric Lindquist, DMV, DABVP, Cert. IVUSS, CEO of SonoPath.com
info@SonoPath.com