



PATIENT

Balto Finck

SPECIES

Canine

BREED

Husky

SEX

Neutered male

AGE

8 years

WEIGHT

63 lbs

INTERPRETED BY

Eric Lindquist, DMV
DABVP, Cert. IVUSS

IMAGING PERFORMED BY

Tiffany Boomer

HOSPITAL NAME

Moyock AH

REFERRING VET

Dr. Tracy Eure

INVOICE

71677

DATE

2/18/26

PRESENTING CLINICAL SIGNS

- 2/14/26 STARTED WITH VOMITING (AT LEAST 3X THAT AFTERNOON) AND THEN DIARRHEA STARTED AND HAD NOT STOPPED WHEN WE SAW P ON 2/16. HAD ALSO CONTINUED TO VOMIT SEVERAL TIMES. O BROUGHT P TO SEE US 2/16---P WAS BAR, BUT CONT GI SYMPTOMS.
- LIPASE AND CPL ELEVATED, OTHERWISE NSF.

ULTRASONOGRAPHIC EXAMINATION OF THE ABDOMEN

Urinary System

The **urinary bladder**, trigone, and pelvic urethra presented normal thicknesses and normal tone. The pelvic urethra was imaged 2.0 cm beyond the cystourethral junction and appeared normal. The ureters were not visible which is normal. No uroliths or sediment were visualized and anechoic urine was present. No evidence of inflammatory or neoplastic changes was noted. Ureteral papillae were normal.

The **kidneys** revealed normal size and structure, corticomedullary definition and ratio for this age. The cortices presented largely uniform texture with normal echogenic relationship to liver and spleen. Medullary structure differed distinctly from the cortex and no evidence of pelvic dilation was present. The capsules were acceptably uniform without significant irregularities. The left and right kidney measured 6.0 cm.

The iliac trifurcation was unremarkable.

Adrenal Glands

Both **adrenal glands** were visualized and recognized as having normal shape, size, position and echogenicity for this breed. The phrenic vasculature, glandular echogenicity and detail were unremarkable. Capsule, cortex, and medullary definition were normal for this age patient. The left adrenal gland measured 0.5 cm. The right adrenal gland measured 1.0 cm at the cranial pole and 0.5 cm at the caudal pole.

Spleen

The **spleen** in this patient was mildly enlarged with uniform parenchyma and was folded upon itself cranially. This is a positional variant and is not pathological. There was no evidence of significant disease.

Liver

The **liver** images submitted revealed subjectively normal liver size, contour, and structure. Parenchymal echogenicity was naturally coarse and hypoechoic to the spleen. Vascular and biliary tracts were of normal volume with no evidence of congestion. The gallbladder presented acceptably thin walls with primarily anechoic content. The cystic and common bile ducts were normal. No pathological hepatic lymphadenopathy was evident. No overt structural evidence of inflammatory, infiltrative or regenerative pathology was evident.



PATIENT

Balto Finck

SPECIES

Canine

BREED

Husky

SEX

Neutered male

AGE

8 years

WEIGHT

63 lbs

INTERPRETED BY

Eric Lindquist, DMV
DABVP, Cert. IVUSS

IMAGING PERFORMED BY

Tiffany Boomer

HOSPITAL NAME

Moyock AH

REFERRING VET

Dr. Tracy Eure

INVOICE

71677

DATE

2/18/26

Gastrointestinal

Examination of the **gastrointestinal tract** revealed a stomach and intestine free of stasis, of normal wall thickness, acceptable curvilinear mural detail, and peristaltic activity. Gastric luminal fluid was noted in this patient. Small and large intestine demonstrated normal luminal chyme and stool consistency respectively. No obstructive or overt infiltrative disease was noted. No associated abnormal lymphatic activity was noted.

Pancreas

The right base of the **pancreas** revealed a mild amount of remodeling and heterogenous parenchymal changes. There is a potential for low grade inflammation.

ULTRASONOGRAPHIC FINDINGS

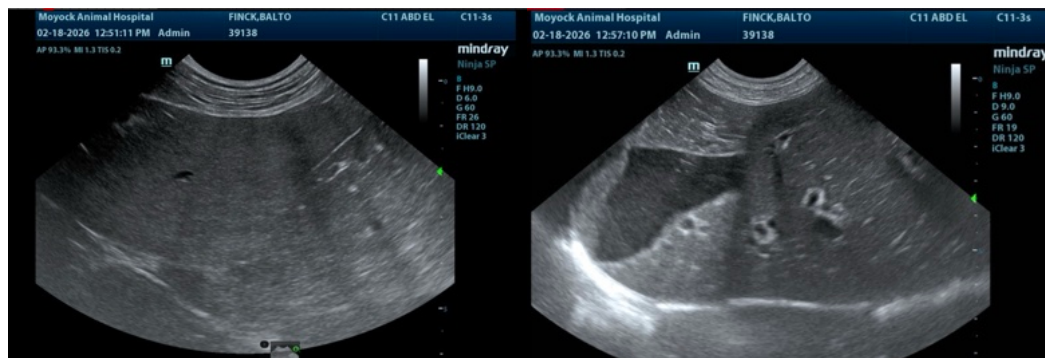
Mild gastritis.

Slight, chronic pancreatic changes, potential low-grade pancreatitis.

INTERPRETATION OF THE FINDINGS & FURTHER RECOMMENDATIONS

The patient should respond to medical management. Medical management for gastric irritation is indicated. A clinical trial of the following may prove effective.

Dietary indiscretion, food intolerance, structurally significant inflammatory bowel or occult parasitism and occult Addison's are all potentials.





PATIENT

Balto Finck

SPECIES

Canine

BREED

Husky

SEX

Neutered male

AGE

8 years

WEIGHT

63 lbs

INTERPRETED BY

Eric Lindquist, DMV
DABVP, Cert. IVUSS

IMAGING PERFORMED BY

Tiffany Boomer

HOSPITAL NAME

Moyock AH

REFERRING VET

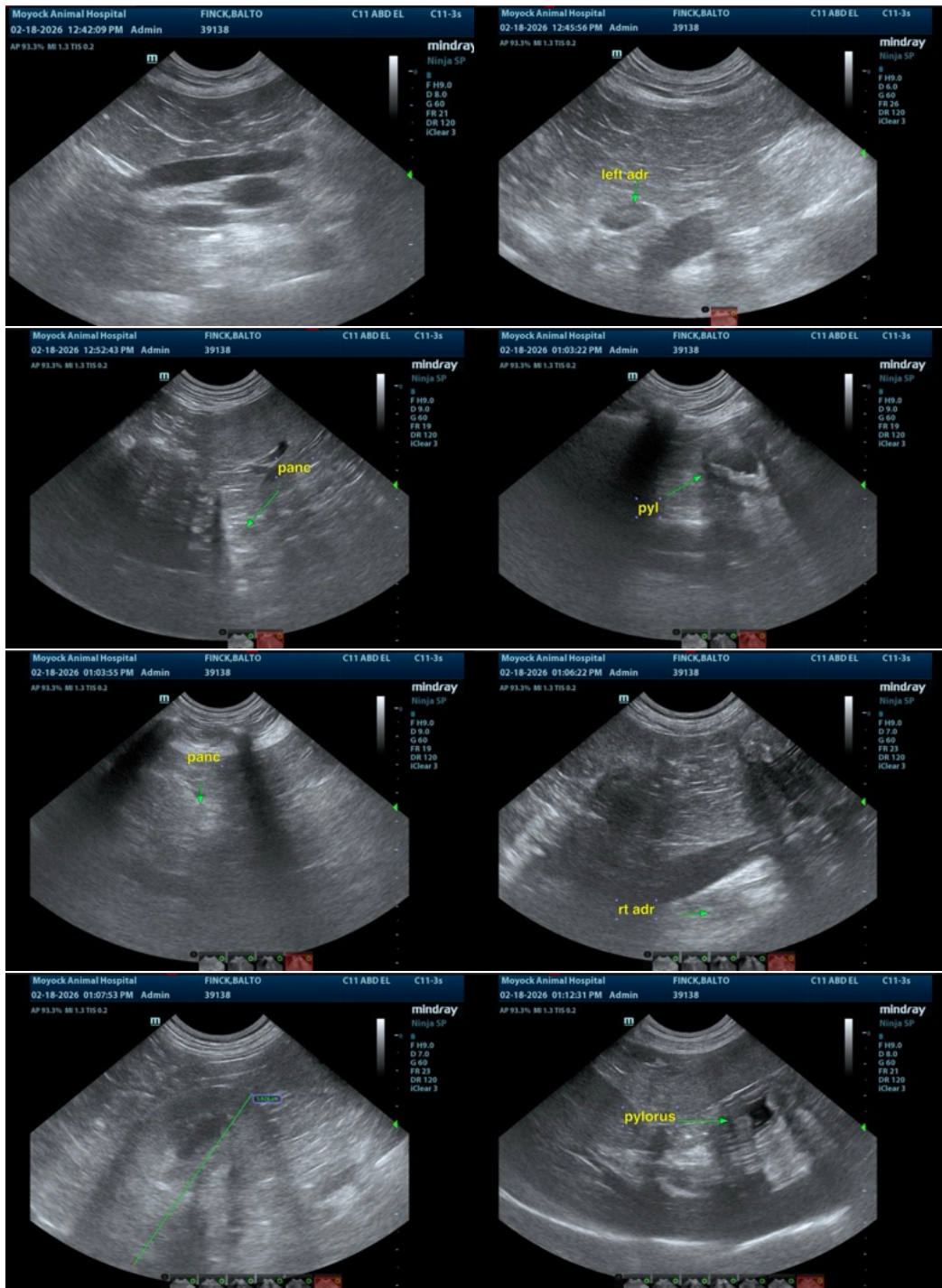
Dr. Tracy Eure

INVOICE

71677

DATE

2/18/26



The information and recommendations provided are based on the images presented by the referring veterinarian/sonographer. No evaluation can be communicated regarding pathology



PATIENT

Balto Finck

SPECIES

Canine

BREED

Husky

SEX

Neutered male

AGE

8 years

WEIGHT

63 lbs

INTERPRETED BY

Eric Lindquist, DMV
DABVP, Cert. IVUSS

IMAGING PERFORMED BY

Tiffany Boomer

HOSPITAL NAME

Moyock AH

REFERRING VET

Dr. Tracy Eure

INVOICE

71677

DATE

2/18/26

that was not visible in the image/video clips provided.

Thank you for this referral. If the clinical or image interpretation does not parallel your findings or if I can be of any further assistance please contact me.

Eric Lindquist, DMV, DABVP (CFM), Cert. IVUSS, CEO of SonoPath.com

info@SonoPath.com