

**DATE**

2/18/22

PRESENTING CLINICAL SIGNS

History: Presents for hx of pu/pd and vomiting more than normal.
 BW shows iris stage 2, elevated WBC.

PATIENT

Toby Burnish

Date of Previous IntraPet Ultrasound: No previous IntraPet scans.
 Sedation: Not required to complete full diagnostic ultrasound.
 Stat Report: Not requested.

SPECIES

Feline

Imaging Performed By: Stephanie Pearce RDCS, RVT.

BREED

DSH

ULTRASONOGRAPHIC EXAMINATION OF THE ABDOMEN**SEX**

Neutered Male

Urinary System

The **urinary bladder** was largely unremarkable with a minor focal 7.0 cm x 3.0 mm thickening at the apical ventral wall, appears subjectively benign, however, should be monitored.

AGE

11/9/07

The **kidneys** presented a relatively uniform cortical hyperechogenicity when compared to the renal medulla, spleen and liver. No overt masses were noted. Corticomedullary definition was nebulous and the ratio favored the cortex slightly. The ureters were not visible and assumed to be normal. These changes are most consistent with chronic interstitial nephritis yet infiltrative disease could not be entirely ruled out without biopsy though neoplasia is not suspected. The right kidney measured 4.38 cm. Blood flow to the kidneys appeared to be subjectively subnormal, indicative of chronic disease.

WEIGHT

10.4 Pounds

Adrenal Glands

The **left adrenal gland** was visualized and recognized as having normal shape, size, position and echogenicity for this breed. The phrenic vasculature, glandular echogenicity and detail were unremarkable. Capsule, cortex, and medullary definition were normal for this age patient. The left adrenal gland measured 0.56 cm.

INTERPRETED BY

Eric Lindquist, DMV
 DABVP, Cert. IVUSS

The region of the **right adrenal gland** revealed no evident pathology.

HOSPITAL NAME

Homeward Bound VS

Spleen

The **spleen** was mildly enlarged with uniform, but subtly micronodular parenchyma, and mild undulating capsular contour. This is consistent with reactive spleen owing to immune stimulus or early infiltrative disease such as mast cell disease or lymphoma. 25-gauge FNA would be ideal if weight loss is an issue to differentiate early round cell neoplasia versus splenitis or reactive spleen all of which can present in this manner. Slight micronodular changes were noted in the spleen. The spleen measured 1.0 cm in width.

REFERRING VET

Dr. Vance

Liver**INVOICE**

14000

The **liver** images submitted revealed subjectively normal liver size, contour, and structure. Parenchymal echogenicity was naturally coarse and hypoechoic to the spleen. Vascular and biliary tracts were of normal volume with no evidence of congestion. The gallbladder presented acceptably thin walls with primarily anechoic content. The cystic and common bile ducts were normal. No pathological hepatic lymphadenopathy was evident. No overt structural evidence of inflammatory, infiltrative or regenerative pathology was evident.

Gastrointestinal

The **gastrointestinal** presentation revealed mild uniform prominence of the gastric mucosa as well as areas of "ropey" small intestinal wall. Muscularis/mucosal ratio was 1:1. The intestinal submucosa was slightly irregular, thickened and hyperechoic suggestive of low grade, chronic disease. No concerning lymphadenopathy was visible. No evidence of obstruction was present. Chronic inflammatory bowel disease is likely with a low possibility of an early neoplastic event such as lymphoma. Full thickness tissue biopsies via open laparotomy, ideally guided by intraoperative ultrasound in order to obtain the most representative mural sample, would be necessary to rule out this possibility. Some retention of ingesta was noted in the stomach.

Pancreas

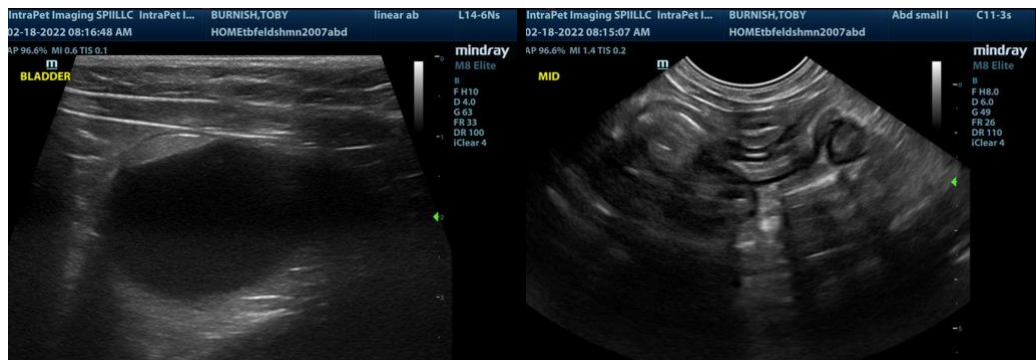
The base and limbs of the **pancreas** were observed to be largely isoechoic to surrounding omental fat. Some parenchymal remodeling, however, with mild deviation from curvilinear normalcy was observed. Pancreatic duct and capsular irregularities were present consistent with age related changes. If pain upon imaging (+ Murphy sign) was present or if the patient is focally painful in subxyphoid palpation then low-grade smoldering chronic pancreatitis should be suspected. The left limb of the pancreas measured 0.56 cm. The right limb of the pancreas measured 0.93 cm.

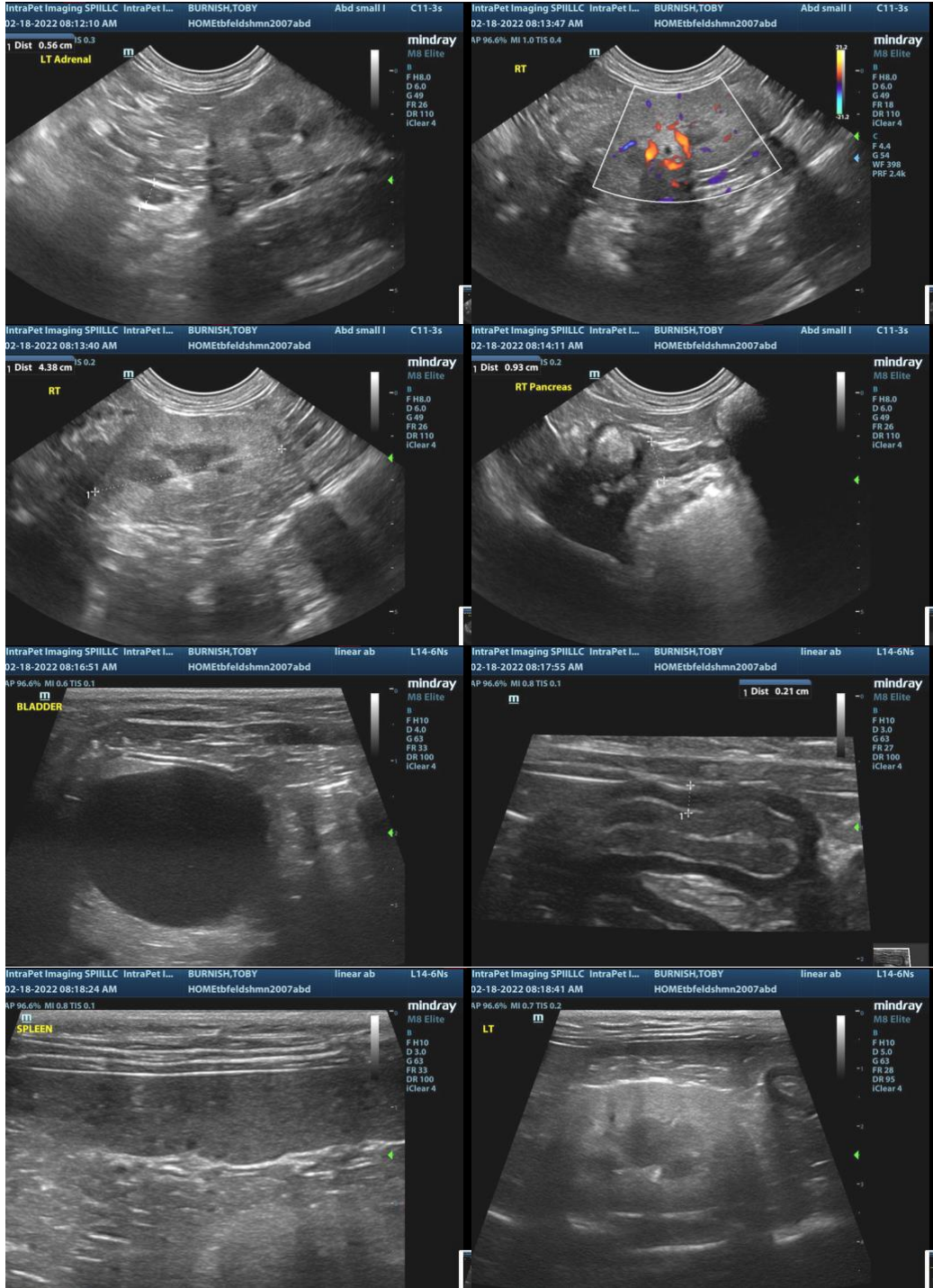
ULTRASONOGRAPHIC FINDINGS

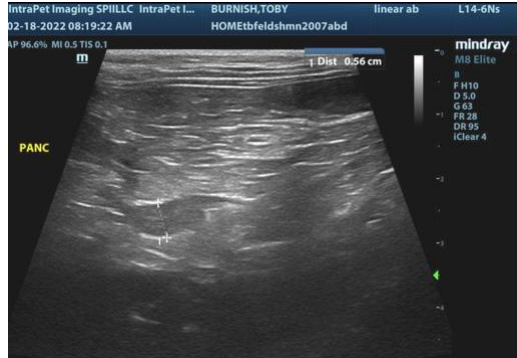- Minor intestinal thickening
- Chronic interstitial nephrosis pattern
- Prominent irregular pancreas
- Urinary bladder wall thickening

INTERPRETATION OF THE FINDINGS & FURTHER RECOMMENDATIONS

Both prerenal and renal disease may be playing a role in this patient with the intestinal thickening and prominent pancreas. Subxyphoid palpation is recommended to assess for pain or discomfort associated with the pancreas. The kidneys do not subjectively appear end stage. However, persistent monitoring and management for chronic renal disease is indicated. If clinically warranted, IV fluid support and treatment for prerenal disease warranted. Assessment for any urinary inflammatory sediment recommended. 72-hour IV fluid protocol to treat both prerenal and renal disease would be indicated with FNA of the spleen to ensure this is a reactive state and no emerging round cell neoplasia is present.







The information and recommendations provided are based on the images presented by the referring veterinarian. No evaluation can be communicated regarding pathology that was not visible in the image/video clips provided.

Thank you for this referral. If the clinical or image interpretation does not parallel your findings or if I can be of any further assistance please contact me.

Eric Lindquist, DMV, DABVP, Cert. IVUSS, CEO of SonoPath.com
Eric.Lindquist@SonoPath.com