

**DATE**

2/18/22

PRESENTING CLINICAL SIGNS**PATIENT**

History: Chronic on and off diarrhea ~5 years. Occasional vomiting
 Jan 2021-acute vomiting ~7-10-day duration. Pet would not take rx
 Jan 2022-liquid diarrhea; rx metronidazole

Ethyl Grocott

SPECIES

Current Medications: Metronidazole 125mg po BID, has finished., Cerenia inj 0.75ml on 2/11/22, LRS 250ml 2/11/22.

Feline

Lab Results: No rads, CBC chem from 1/2021 WNL and CBC chem T4 from 1/2022 WNL. Attached separately.

BREED

DSH

Date of Previous IntraPet Ultrasound: No previous IntraPet scans.

SEX

Sedation: IV sedation: Butorphanol 10mg/ml 0.05ml IV Midazolam 5mg/ml 0.01ml IV.

Stat Report: Not requested.

Spayed Female

Imaging Performed By: Rachel Brillhart, RDMS.

AGE

1/19/17

ULTRASONOGRAPHIC EXAMINATION OF THE ABDOMEN**WEIGHT**

18.5 Lbs.

Urinary System

The **urinary bladder**, trigone, and pelvic urethra presented normal thicknesses and normal tone. The ureters were not visible which is normal. No uroliths or sediment were visualized and anechoic urine was present. No evidence of inflammatory or neoplastic changes were noted. Ureteral papillae were normal.

The **kidneys** revealed normal size and structure, corticomedullary definition and ratio for this age. The cortices presented largely uniform texture with normal echogenic relationship to liver and spleen. Medullary structure differed distinctly from the cortex and no evidence of pelvic dilation was present. The capsules were acceptably uniform without significant irregularities. The left kidney measured 4.0 cm. The right kidney measured 4.0 cm.

INTERPRETED BY

Eric Lindquist, DMV
 DABVP, Cert. IVUSS

Adrenal Glands

The regions of the **adrenal glands** revealed no evident pathology.

HOSPITAL NAME

Bel Air VH

Spleen

The **spleen** presented a smooth homogeneous parenchyma hyperechoic to liver and renal cortical parenchyma. The capsule was smooth without noticeable expansion or deviation from within the spleen or adjacent pathology. The splenic vasculature demonstrated normal volume without signs of congestion or thrombosis. No sonographic evidence of acute or chronic inflammatory, neoplastic, or infarctual changes were noted.

REFERRING VET

Dr. Schmidt

INVOICE

14004

Liver

The **liver** images submitted revealed subjectively normal liver size, contour, and structure. Parenchymal echogenicity was naturally coarse and hypoechoic to the spleen. Vascular and biliary tracts were of normal volume with no evidence of congestion. The gallbladder presented acceptably thin walls with primarily anechoic content. The cystic and common bile ducts were normal. No pathological hepatic lymphadenopathy was evident. No overt structural evidence of inflammatory, infiltrative or regenerative pathology was evident.

Gastrointestinal

The **gastrointestinal** presentation revealed mild uniform prominence of the gastric mucosa as well as areas of "ropey" small intestinal wall (thickness up to 0.28 cm). Muscularis/mucosal ratio was 1:1. The intestinal submucosa was slightly irregular, thickened and hyperechoic suggestive of low grade, chronic disease. No concerning lymphadenopathy was visible. No evidence of obstruction was present. Chronic inflammatory bowel disease is likely with a low possibility of an early neoplastic event such as lymphoma. Full thickness tissue biopsies via open laparotomy, ideally guided by intraoperative ultrasound in order to obtain the most representative mural sample, would be necessary to rule out this possibility.

Pancreas

The base and limbs of the **pancreas** were observed to be largely isoechoic to surrounding omental fat. Pancreatic duct and capsular contour were acceptably normal and parenchyma respected normal curvilinear patterns. No overt evidence of active inflammatory or neoplastic disease was noted.

ULTRASONOGRAPHIC FINDINGS

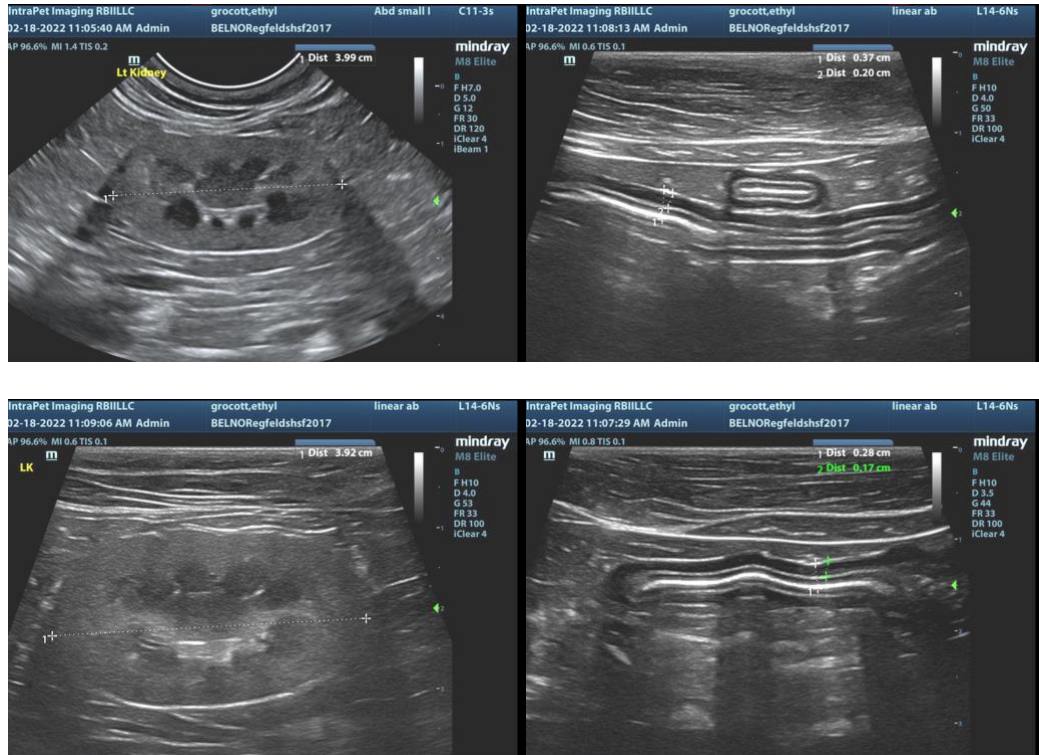
- Diffuse intestinal thickening with idiopathic muscularis hypertrophy

INTERPRETATION OF THE FINDINGS & FURTHER RECOMMENDATIONS

Neoplastic criteria not met. This is likely chronic inflammatory bowel. If weight loss is an issue, full thickness intestinal biopsies necessary for further definition. Hydrolyzed diet recommended. A clinical trial of the following may prove effective. Antiparasitic protocol warranted.

Triaditis/Pancreatitis protocol

Part or all of this protocol may be considered based on your clinical impression of the patient: Recommend pain management when anorexic with **Buprenorphine** (0.01-0.02 mg/kg IM or SC), clinical trial of **Zithromax** (50 mg sid/cat x 10 days, 3 weeks if bartonella +), **Prednisolone** (0.5-2 mg/kg tapering over 1 week to minimal effective dose), and **B12 injections** if weight loss (Cyanobalamine 250 mcg sub-q once-weekly x six weeks, then every other week for six weeks and then once-monthly, long-term if necessary), **novel-protein or hydrolyzed diet** (*Hydrolyzed diets have been shown to be more effective in dietary intolerance case management compared to hypoallergenic diets*) or the **magical Purina DM** (changing protein source is crucial and may need rotation every 6 months if clinical signs recur) Diet trials is a whatever works phenomenon. If vomiting becomes a persistent issue then endoscopy would be warranted and/or recheck sonogram to assess more emerging disease. One diet does not work for all patients so different trials may be necessary or protein source rotation every 6 months as new sensitivities develop.



The information and recommendations provided are based on the images presented by the referring veterinarian. No evaluation can be communicated regarding pathology that was not visible in the image/video clips provided.

Thank you for this referral. If the clinical or image interpretation does not parallel your findings or if I can be of any further assistance please contact me.

Eric Lindquist, DMV, DABVP, Cert. IVUSS, CEO of SonoPath.com
 Eric.Lindquist@SonoPath.com