

**DATE PRESENTING CLINICAL SIGNS**

2/18/22

PATIENT

History: Patient presented 2/14/22 w/ history of chronic GI problems (decreased appetite + will vomit bile while not eating which happens at night). Weight loss 38# on 2/14 was 45.6# on 8/2/21. Decreased drinking but urinating a TON. Palpable prescapular (bilat) + submandibular lymph node (bilat) not terribly large or firm.

Cooper Wehr

SPECIES

Current Medications: Entyce, Provable, Prilosec, disc adding Cerenia.

Lab Results: increased GGTP 23 (1-12), *increased Ca 12.9 (8.9-11.4)*

Creat 1.3 (0.5-1.6), decreased PCT 90 w/ few small clumps + giant platelets, USG 1.010. Attached separately.

Canine

BREED

Date of Previous IntraPet Ultrasound: No previous IntraPet scans.

Sedation: Not required to complete full diagnostic ultrasound.

Stat Report: Not requested.

Pug Mix

SEX

Imaging Performed By: Rachel Brillhart, RDMS.

Neutered Male

ULTRASONOGRAPHIC EXAMINATION OF THE ABDOMEN**AGE****Urinary System**

3/12/17

The **urinary bladder**, trigone, and pelvic urethra presented normal thicknesses and normal tone. The ureters were not visible which is normal. No uroliths or sediment were visualized and anechoic urine was present. No evidence of inflammatory or neoplastic changes were noted. Ureteral papillae were normal.

WEIGHT

45.8 Pounds

The **kidneys** revealed normal size and structure, corticomedullary definition and ratio for this age. The cortices presented largely uniform texture with normal echogenic relationship to liver and spleen. Medullary structure differed distinctly from the cortex and no evidence of pelvic dilation was present. The capsules were acceptably uniform without significant irregularities. The left kidney measured 5.98 cm. The right kidney measured 5.16 cm.

INTERPRETED BYEric Lindquist, DMV
DABVP, Cert. IVUSS**Adrenal Glands**

Both **adrenal glands** were visualized and recognized as having normal shape, size, position and echogenicity for this breed. The phrenic vasculature, glandular echogenicity and detail were unremarkable. Capsule, cortex, and medullary definition were normal for this age patient. The right adrenal gland measured 2.36 cm x 0.84 cm at the caudal pole and 0.79 cm at the cranial pole. The left adrenal gland measured 2.56 cm x 0.68 cm at the caudal pole and 0.68 cm at the cranial pole.

HOSPITAL NAME

Bel Air VH

REFERRING VET

Dr. Stevenson

SpleenThe **spleen** revealed multifocal hypoechoic nodular changes, suggestive for round cell neoplasia.**INVOICE**

14003

LiverThe **liver** was swollen with increased portal markings. The gallbladder and common bile duct were unremarkable.**Gastrointestinal**Examination of the **gastrointestinal tract** revealed a stomach and intestine free of stasis, of normal wall thickness, acceptable curvilinear mural detail, and peristaltic activity. Small and large intestine

demonstrated normal luminal chyme and stool consistency respectively. No obstructive or overt infiltrative disease was noted. No associated abnormal lymphatic activity was noted.

Pancreas

The base and limbs of the **pancreas** were observed to be largely isoechoic to surrounding omental fat. Pancreatic duct and capsular contour were acceptably normal and parenchyma respected normal curvilinear patterns. No overt evidence of active inflammatory or neoplastic disease was noted.

Other

The cranial **mediastinum** revealed a complex mixed hypoechoic and partially cystic mass, measuring 7.2 cm, appeared to be deriving from a cranial mediastinal lymph node. No entrapped air noted, which would suggest non-pulmonary component. The cranial mediastinal mass appeared to envelop the cranial thoracic aorta.

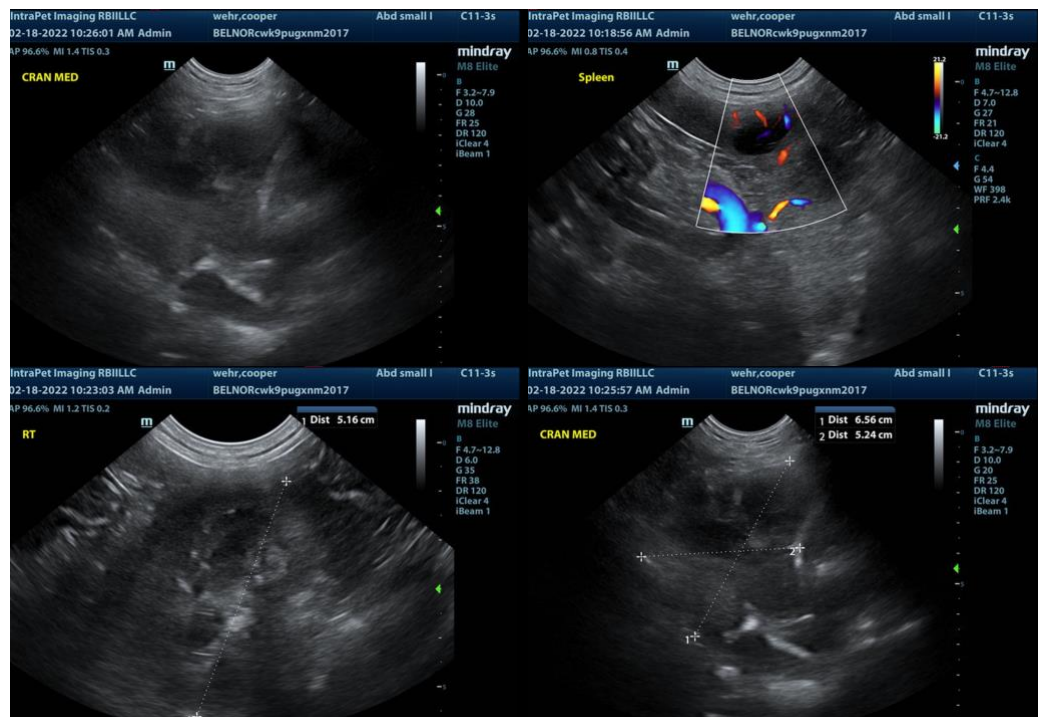
A rapid view of the **heart** revealed normal contractility and volume.

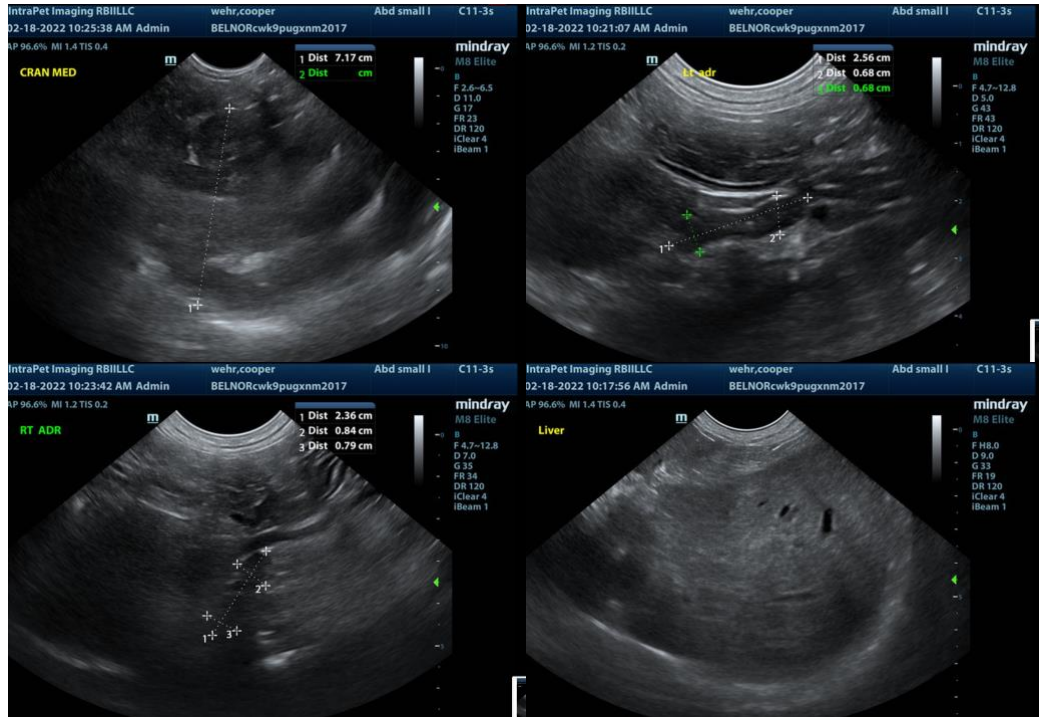
ULTRASONOGRAPHIC FINDINGS

- Splenic nodule
- Swollen liver
- Cranial mediastinal mass

INTERPRETATION OF THE FINDINGS & FURTHER RECOMMENDATIONS

Multicentric round cell neoplasia suspected. Splenic nodular hyperplasia and thymoma possible yet less likely. FNA of the splenic lesions, liver and cranial mediastinal mass all indicated. The cranial mediastinal mass appeared to envelop the cranial thoracic aorta- a clean resection may be difficult.





The information and recommendations provided are based on the images presented by the referring veterinarian. No evaluation can be communicated regarding pathology that was not visible in the image/video clips provided.

Thank you for this referral. If the clinical or image interpretation does not parallel your findings or if I can be of any further assistance please contact me.

Eric Lindquist, DMV, DABVP, Cert. IVUSS, CEO of SonoPath.com
 Eric.Lindquist@SonoPath.com