



PATIENT

Precious Amati

SPECIES

Feline

BREED

DSH

SEX

Spayed Female

AGE

8 Years

WEIGHT

10 Pounds

INTERPRETED BY

Eric Lindquist, DMV
DABVP, Cert. IVUSS

IMAGING PERFORMED BY

John Ammeraal, DVM

HOSPITAL NAME

Sova AH

REFERRING VET

John Ammeraal, DVM

INVOICE

21145

DATE

2/17/23

PRESENTING CLINICAL SIGNS

History: Looked dazed the other day according to owner, Eating drinking fine . Normal BM's urination

Abnormal PE/Chem/CBC/UA Results: AST: 128 U/L , ALT 336 U/L , Alkp 142 U/L, Rest of Chem/ CBC WNL USG 1.017

ULTRASONOGRAPHIC EXAMINATION OF THE ABDOMEN

Urinary System

The **urinary bladder**, trigone, and pelvic urethra presented normal thicknesses and normal tone. The ureters were not visible which is normal. No uroliths or sediment were visualized and anechoic urine was present. No evidence of inflammatory or neoplastic changes were noted. Ureteral papillae were normal.

The **kidneys** revealed normal size and structure, corticomedullary definition and ratio for this age. The cortices presented largely uniform texture with normal echogenic relationship to liver and spleen. Medullary structure differed distinctly from the cortex and no evidence of pelvic dilation was present. The capsules were acceptably uniform without significant irregularities. The left kidney measured 3.44 cm.

Adrenal Glands

The **right adrenal gland** was visualized and recognized as having normal shape, size, position and echogenicity for this breed. The phrenic vasculature, glandular echogenicity and detail were unremarkable. Capsule, cortex, and medullary definition were normal for this age patient. The right adrenal gland measured 0.48 cm. The left adrenal gland measured 0.35 cm.

The region of the **left adrenal gland** revealed no evident pathology.

Spleen

The **spleen** presented a smooth homogeneous parenchyma hyperechoic to liver and renal cortical parenchyma. The capsule was smooth without noticeable expansion or deviation from within the spleen or adjacent pathology. The splenic vasculature demonstrated normal volume without signs of congestion or thrombosis. No sonographic evidence of acute or chronic inflammatory, neoplastic, or infarctual changes were noted.

Liver

The **liver** revealed slight coarse architecture and minor increased portal markings. The gallbladder wall was slightly echogenic. This change is consistent with nonspecific cholangitis. FNA is indicated.

Gastrointestinal

The **gastrointestinal** presentation revealed mild uniform prominence of the gastric mucosa as well as areas of "ropey" small intestinal wall with slight disruption of the normal 1:3 muscularis/mucosal ratio. The intestinal submucosa was slightly irregular, thickened and hyperechoic suggestive of low grade, chronic disease. No concerning lymphadenopathy was visible. No evidence of obstruction was present. Chronic inflammatory bowel disease is likely with a low possibility of an early neoplastic event such as lymphoma. Full thickness tissue biopsies via open laparotomy, ideally guided by intraoperative ultrasound in order to obtain the most representative mural sample, would be necessary to rule out this possibility. This is a minor change.



PATIENT

Pancreas

Precious Amati

The base and limbs of the **pancreas** were observed to be largely isoechoic to surrounding omental fat. Pancreatic duct and capsular contour were acceptably normal and parenchyma respected normal curvilinear patterns. No overt evidence of active inflammatory or neoplastic disease was noted.

SPECIES

Feline

ULTRASONOGRAPHIC FINDINGS

- Minor intestinal thickening
- Cholangitis liver pattern, mild chronic changes

BREED

DSH

INTERPRETATION OF THE FINDINGS & FURTHER RECOMMENDATIONS

SEX

Triaditis is likely an underlying issue in this patient. Bile acid profile is warranted given the patient history.

Spayed Female

AGE

8 Years

WEIGHT

10 Pounds

INTERPRETED BY

Eric Lindquist, DMV
DABVP, Cert. IVUSS

IMAGING PERFORMED BY

John Ammeraal, DVM

HOSPITAL NAME

Sova AH

REFERRING VET

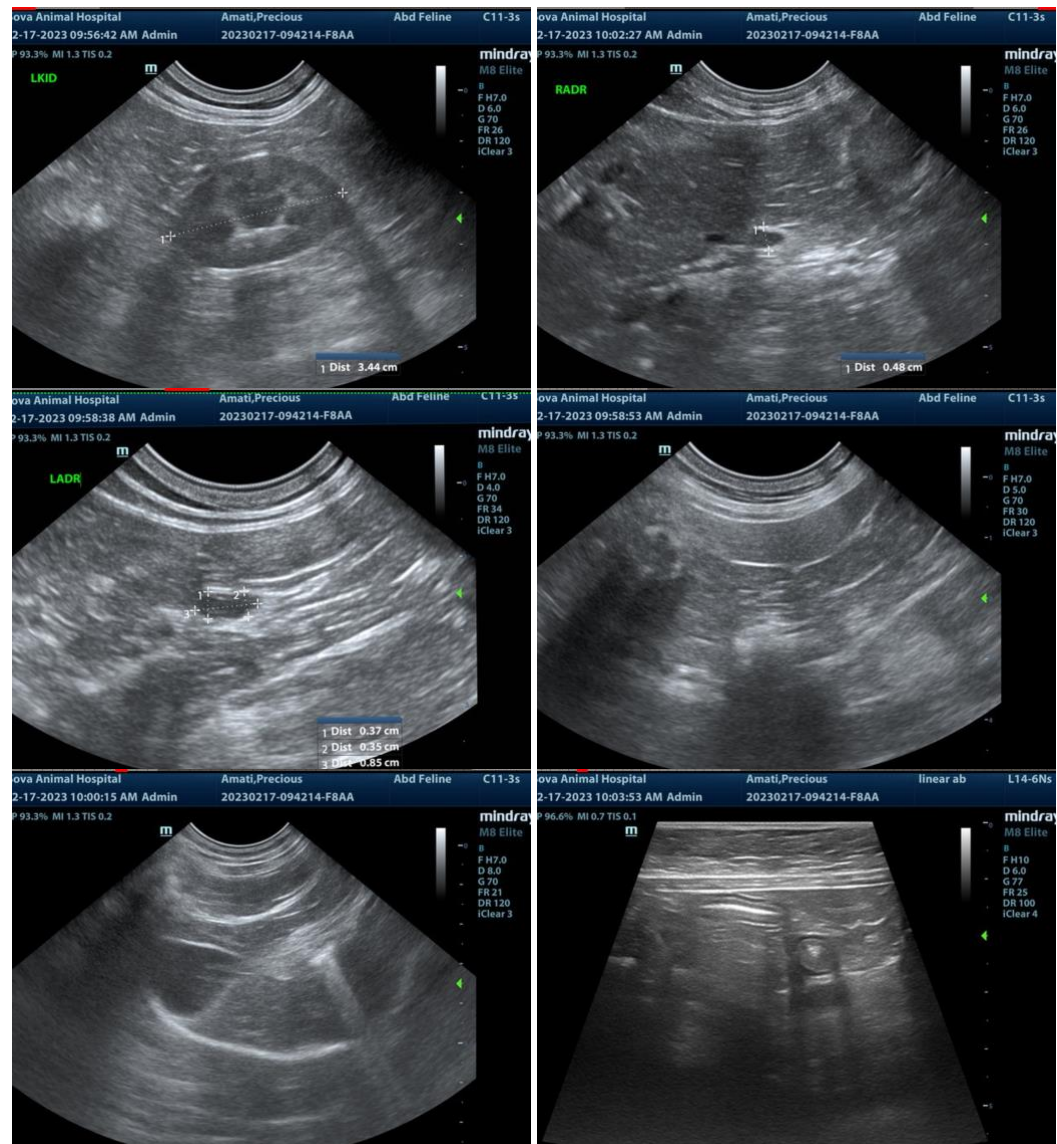
John Ammeraal, DVM

INVOICE

21145

DATE

2/17/23





PATIENT

Precious Amati

SPECIES

Feline

BREED

DSH

SEX

Spayed Female

AGE

8 Years

WEIGHT

10 Pounds

INTERPRETED BY

Eric Lindquist, DMV
DABVP, Cert. IVUSS

**IMAGING
PERFORMED BY**

John Ammeraal, DVM

HOSPITAL NAME

Sova AH

REFERRING VET

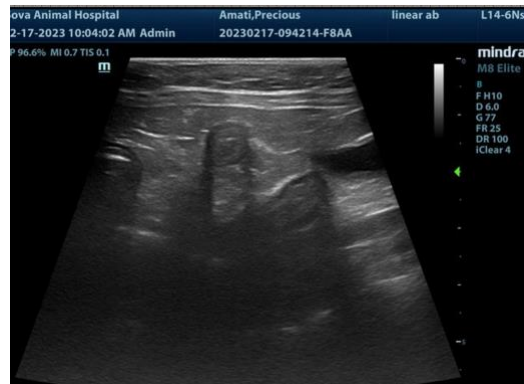John Ammeraal, DVM

INVOICE

21145

DATE

2/17/23



The information and recommendations provided are based on the images presented by the referring veterinarian. No evaluation can be communicated regarding pathology that was not visible in the image/video clips provided.

Thank you for this referral. If the clinical or image interpretation does not parallel your findings or if I can be of any further assistance please contact me.

Eric Lindquist, DMV, DABVP, Cert. IVUSS, CEO of SonoPath.com
info@SonoPath.com