SonoPath
Clinical Sonography & Telecytology

EDUCATIONAL TELECONSULTATION SERVICES™

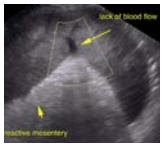
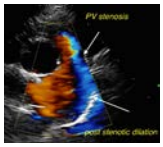
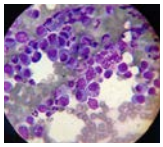
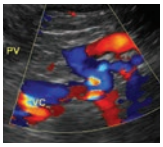

SonoPath.com™
1-800-838-4268 info@sonopath.com

PATIENT
Lola Cisneros Sr.

SPECIES
Canine

BREED
Bull Terrier

SEX
Intact Female

AGE
2 Years

WEIGHT
46.5 Pounds

INTERPRETED BY
Eric Lindquist, DMV
DABVP, Cert. IVUSS

IMAGING PERFORMED BY
Dr. Deml

HOSPITAL NAME
Craig Road AH

REFERRING VET
Dr. Deml

INVOICE
45347

DATE
2/17/23

PRESENTING CLINICAL SIGNS

P has become progressively more lethargic over the past 2 weeks. P is known to eat foreign objects. P vomited once 5 days ago and had diarrhea around the same time. P has not ate in 3 days.

Abnormal PE/Chem/CBC/UA Results: Abdominal radiographs revealed foreign material (mineral opaque, looks like a wire) in the cranial right abdomen; as well as a mineral opaque stone looking object in the cranial abdomen. CBC/Chem is pending.

ULTRASONOGRAPHIC EXAMINATION OF THE ABDOMEN

Urinary System

The **urinary bladder**, trigone, and pelvic urethra presented normal thicknesses and normal tone. The ureters were not visible which is normal. No uroliths or sediment were visualized and anechoic urine was present. No evidence of inflammatory or neoplastic changes were noted. Ureteral papillae were normal.

The **kidneys** revealed normal size and structure, corticomedullary definition and ratio for this age. The cortices presented largely uniform texture with normal echogenic relationship to liver and spleen. Medullary structure differed distinctly from the cortex and no evidence of pelvic dilation was present. The capsules were acceptably uniform without significant irregularities. The left kidney measured 6.0 cm. The right kidney measured 6.0 cm.

Adrenal Glands

The **right adrenal gland** was visualized and recognized as having normal shape, size, position and echogenicity for this breed. The phrenic vasculature, glandular echogenicity and detail were unremarkable. Capsule, cortex, and medullary definition were normal for this age patient. The right adrenal gland measured 0.15 cm at the cranial pole and 0.97 cm at the caudal pole.

The **left adrenal gland** had slight irregular contour and measured 0.77 cm.

Spleen

The **spleen** presented a smooth homogeneous parenchyma hyperechoic to liver and renal cortical parenchyma. The capsule was smooth without noticeable expansion or deviation from within the spleen or adjacent pathology. The splenic vasculature demonstrated normal volume without signs of congestion or thrombosis. No sonographic evidence of acute or chronic inflammatory, neoplastic, or infarctual changes were noted.

Liver

The **liver** was mildly subnormal in size with slight increased portal markings. The gallbladder and common bile duct were unremarkable.

Gastrointestinal

Shadowing material noted in the **stomach**. If NPO, this could be consistent with fabric type foreign matter. The upper duodenum was hyperperistaltic with fluid filled lumen with linear distal attachment. Spastic intestine noted with reactive surrounding mesentery.

Pancreas

The base and limbs of the **pancreas** were observed to be largely isoechoic to surrounding omental fat. Pancreatic duct and capsular contour were acceptably normal and parenchyma respected normal curvilinear patterns. No overt evidence of active inflammatory or neoplastic disease was noted.

SonoPath
Clinical Sonography & Telecytology

EDUCATIONAL TELECONSULTATION SERVICES™

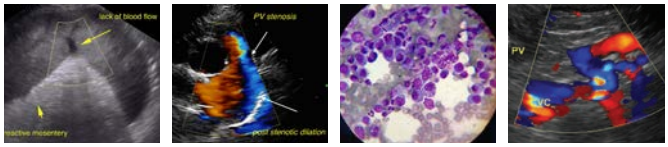

SonoPath.com™
1-800-838-4268 info@sonopath.com

PATIENT

Lola Cisneros Sr.

SPECIES

Canine

BREED

Bull Terrier

SEX

Intact Female

AGE

2 Years

WEIGHT

46.5 Pounds

INTERPRETED BY

Eric Lindquist, DMV

DABVP, Cert. IVUSS

IMAGING PERFORMED BY

Dr. Deml

HOSPITAL NAME

Craig Road AH

REFERRING VET

Dr. Deml

INVOICE

45347

DATE

2/17/23

ULTRASONOGRAPHIC FINDINGS

- Linear foreign body attached to the pylorus followed by empty small intestine with reactive mesentery
- Slightly irregular left adrenal gland
- Mildly subnormal liver size

INTERPRETATION OF THE FINDINGS & FURTHER RECOMMENDATIONS

Recommend immediate surgical exploratory. Blood pressure measurements warranted. GI and hepatic biopsies recommended at surgery.

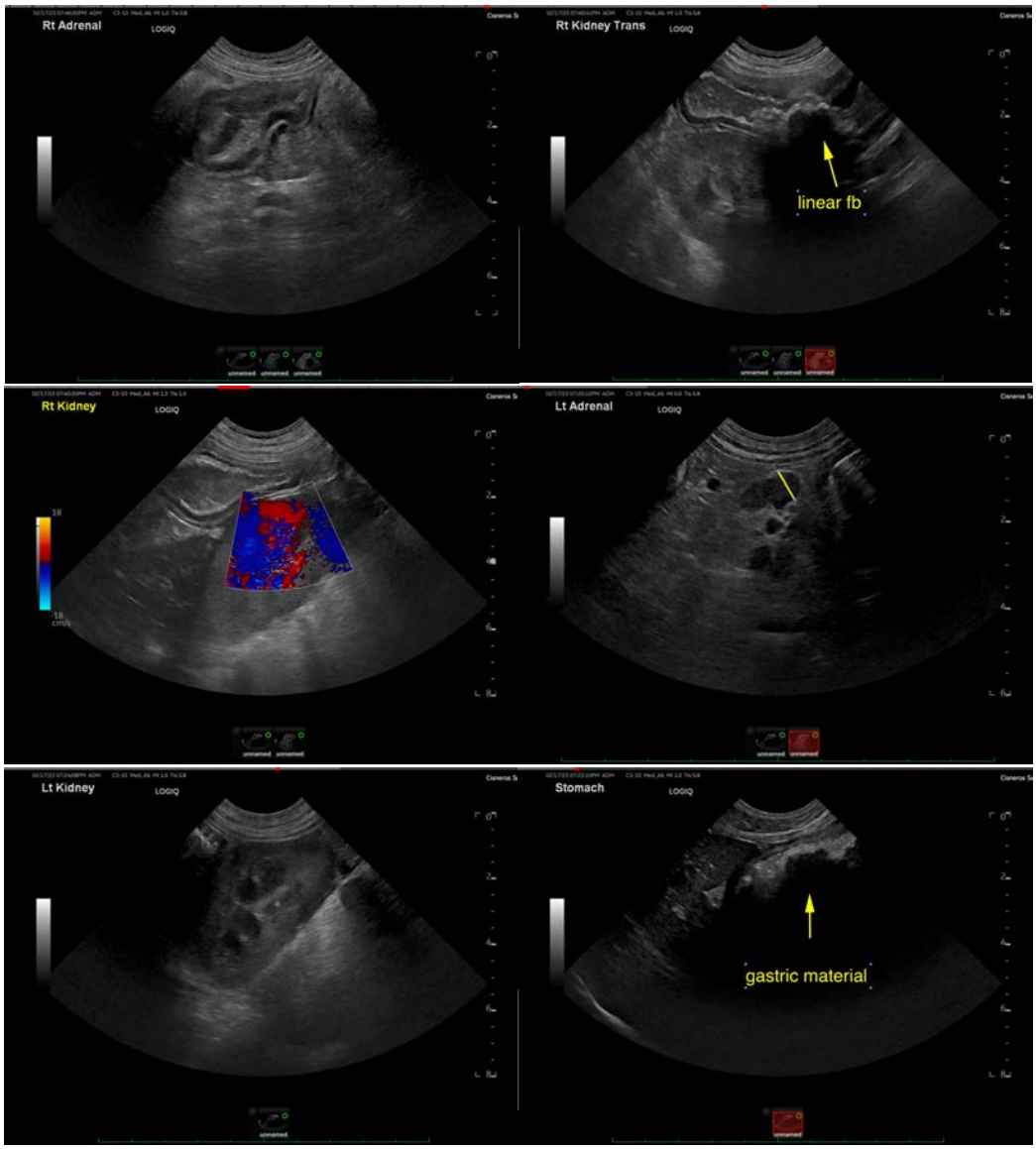

SonoPath

Clinical Sonography & Telecytology

EDUCATIONAL TELECONSULTATION SERVICES™

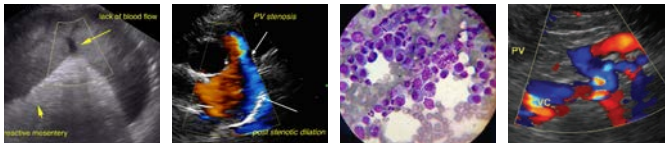

SonoPath.com™

1-800-838-4268 info@sonopath.com

PATIENT

Lola Cisneros Sr.

SPECIES

Canine

BREED

Bull Terrier

SEX

Intact Female

AGE

2 Years

WEIGHT

46.5 Pounds

INTERPRETED BY

Eric Lindquist, DMV

DABVP, Cert. IVUSS

IMAGING PERFORMED BY

Dr. Deml

HOSPITAL NAME

Craig Road AH

REFERRING VET

Dr. Deml

INVOICE

45347

DATE

2/17/23

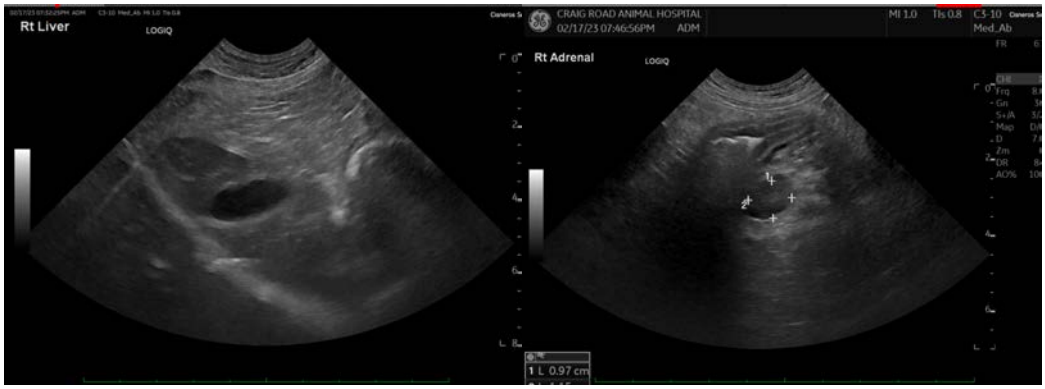

The information and recommendations provided are based on the images presented by the referring veterinarian/sonographer. No evaluation can be communicated regarding pathology that was not visible in the image/video clips provided.

Thank you for this referral. If the clinical or image interpretation does not parallel your findings or if I can be of any further assistance please contact me.

Eric Lindquist, DMV, DABVP, Cert. IVUSS, CEO of SonoPath.com

info@SonoPath.com