SonoPath

Clinical Sonography & Telecytology

EDUCATIONAL TELECONSULTATION SERVICES™

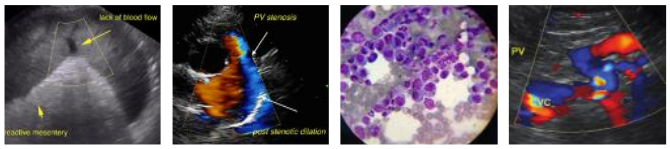

SonoPath.com™
1-800-838-4268 info@sonopath.com

PATIENT

Jackson Voytko

SPECIES

Canine

BREED

Mixed Breed

SEX

Neutered Male

AGE

10 Years

WEIGHT

19 Pounds

INTERPRETED BY

Eric Lindquist, DMV DABVP, Cert. IVUSS

IMAGING PERFORMED BY

Griffin

HOSPITAL NAME

Northside VC

REFERRING VET

Dr. Griffin

INVOICE

21147

DATE

2/17/23

PRESENTING CLINICAL SIGNS

History: Patient presented for stranguria 1/10 and bladder stones were noted and cystotomy was performed

Abnormal PE/Chem/CBC/UA Results: UA: USG 1.038, crystals 1-5 Rads: enlarged liver, bladder stones, no evidence of thoracic or abdominal mass 1/10/23CHEM, TP8.5 ALB4.4 ALT 99, ALKP 1560 Started on Denamarin, Clavamox and Metronidazole on 1/10/23 2/10/23 CHEM ALT202, ALKP 1880 Stone Analysis 1/10 Calcium Oxalate 90% rec C/D diet

ULTRASONOGRAPHIC EXAMINATION OF THE ABDOMEN

Urinary System

Nonobstructive calculi were noted in the **urinary bladder**, measuring up to 0.75 cm. The ureteral papilla revealed cystic changes consistent with ureteroceles. The urethra and prostate were unremarkable. The pelvic urethra was imaged 3.0 cm beyond the cystourethral junction. The prostate measured 6.0 mm.

The **kidneys** revealed largely normal size and structure, corticomedullary definition and ratio (cortex 1/3 of medulla) were essentially maintained with some moderate age-related loss of curvilinear patterns regarding the capsule and C/M junction. The cortices presented largely uniform texture with some increased echogenicity expected for his age patient. Medullary structure differed distinctly from that of the cortex and no evidence of pelvic dilation was present. The right kidney measured 4.18 cm. Calculi were noted in the kidneys. The largest calculus in the right kidney measured 0.32 cm. The left kidney measured 4.4 cm. The largest calculus in the left kidney measured 0.44 cm.

Adrenal Glands

Both **adrenal glands** were visualized and recognized as having normal shape, size, position and echogenicity for this breed. The phrenic vasculature, glandular echogenicity and detail were unremarkable. Capsule, cortex, and medullary definition were normal for this age patient. The right adrenal gland measured 0.67 cm at the cranial pole and 0.54 cm at the caudal pole. The left adrenal gland measured 0.53 cm at the cranial pole and 0.44 cm at the caudal pole.

Spleen

The **spleen** presented a smooth homogeneous parenchyma hyperechoic to liver and renal cortical parenchyma. The capsule was smooth without noticeable expansion or deviation from within the spleen or adjacent pathology. The splenic vasculature demonstrated normal volume without signs of congestion or thrombosis. No sonographic evidence of acute or chronic inflammatory, neoplastic, or infarctual changes were noted.

Liver

Minor **hepatic** enlargement was noted. The liver presented coarse architecture with mildly increased portal markings and subtle, mixed echogenic changes. This is consistent with vacuolar hepatopathy and some level of remodeling and history of inflammatory component. The portal vein to vena cava ratio is 1:1. A hypoechoic nodule was noted, measuring 1.0 cm. Other minor nodular changes were noted. Hyperechoic nodules were noted, consistent with lipogranulomas, measuring up to 1.0 cm. The gallbladder and common bile duct were unremarkable. Hepatic lymph nodes are slightly enlarged, reactive, the largest of which measured 1.2 cm x 0.6 cm.

SonoPath
Clinical Sonography & Telecytology
EDUCATIONAL TELECONSULTATION SERVICES™

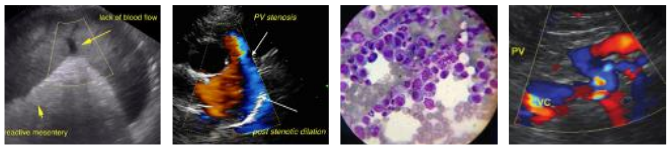

SonoPath.com
1-800-838-4268 info@sonopath.com

PATIENT

Jackson Voytko

SPECIES

Canine

BREED

Mixed Breed

SEX

Neutered Male

AGE

10 Years

WEIGHT

19 Pounds

INTERPRETED BY

Eric Lindquist, DMV
DABVP, Cert. IVUSS

IMAGING PERFORMED BY

Griffin

HOSPITAL NAME

Northside VC

REFERRING VET

Dr. Griffin

INVOICE

21147

DATE

2/17/23

Gastrointestinal

Examination of the **gastrointestinal tract** revealed a stomach and intestine free of stasis, of normal wall thickness, acceptable curvilinear mural detail, and peristaltic activity. Small and large intestine demonstrated normal luminal chyme and stool consistency respectively. No obstructive or overt infiltrative disease was noted. No associated abnormal lymphatic activity was noted.

Pancreas

The base and limbs of the **pancreas** were observed to be largely isoechoic to surrounding omental fat. Pancreatic duct and capsular contour were acceptably normal and parenchyma respected normal curvilinear patterns. No overt evidence of active inflammatory or neoplastic disease was noted.

ULTRASONOGRAPHIC FINDINGS

- Vacuolar hepatopathy/nodular hyperplasia liver pattern
- Slightly enlarged hepatic lymph nodes
- Nonobstructive nephrolithiasis with mild degenerative renal changes
- Urinary bladder calculi and ureterocele polypoid changes at the trigone

INTERPRETATION OF THE FINDINGS & FURTHER RECOMMENDATIONS

Cystotomy +/- correction of the ureteroceles is indicated. FNA of the liver could be considered for further definition, however, likely benign. The recurrence of the bladder calculi is likely owing to passing calculi from the kidneys to the bladder periodically.

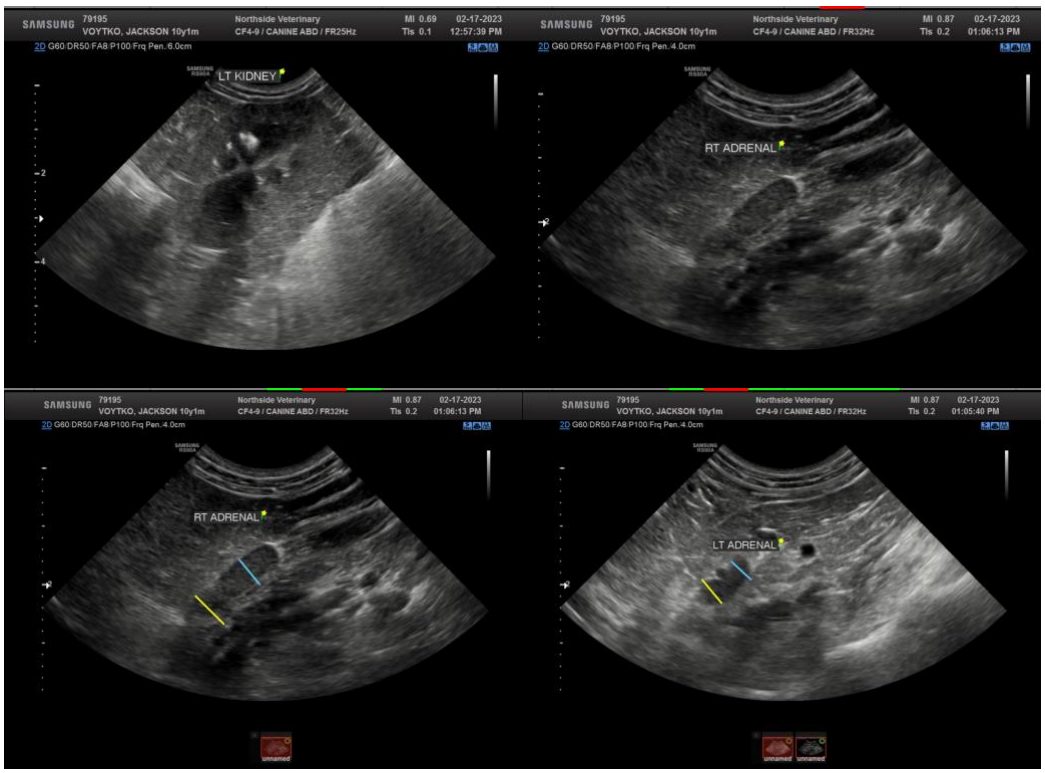

SonoPath

Clinical Sonography & Telecytology

EDUCATIONAL TELECONSULTATION SERVICES™

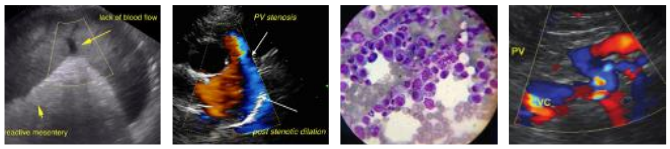

SonoPath.com
1-800-838-4268 info@sonopath.com

PATIENT

Jackson Voytko

SPECIES

Canine

BREED

Mixed Breed

SEX

Neutered Male

AGE

10 Years

WEIGHT

19 Pounds

INTERPRETED BY

Eric Lindquist, DMV
DABVP, Cert. IVUSS

IMAGING PERFORMED BY

Griffin

HOSPITAL NAME

Northside VC

REFERRING VET

Dr. Griffin

INVOICE

21147

DATE

2/17/23

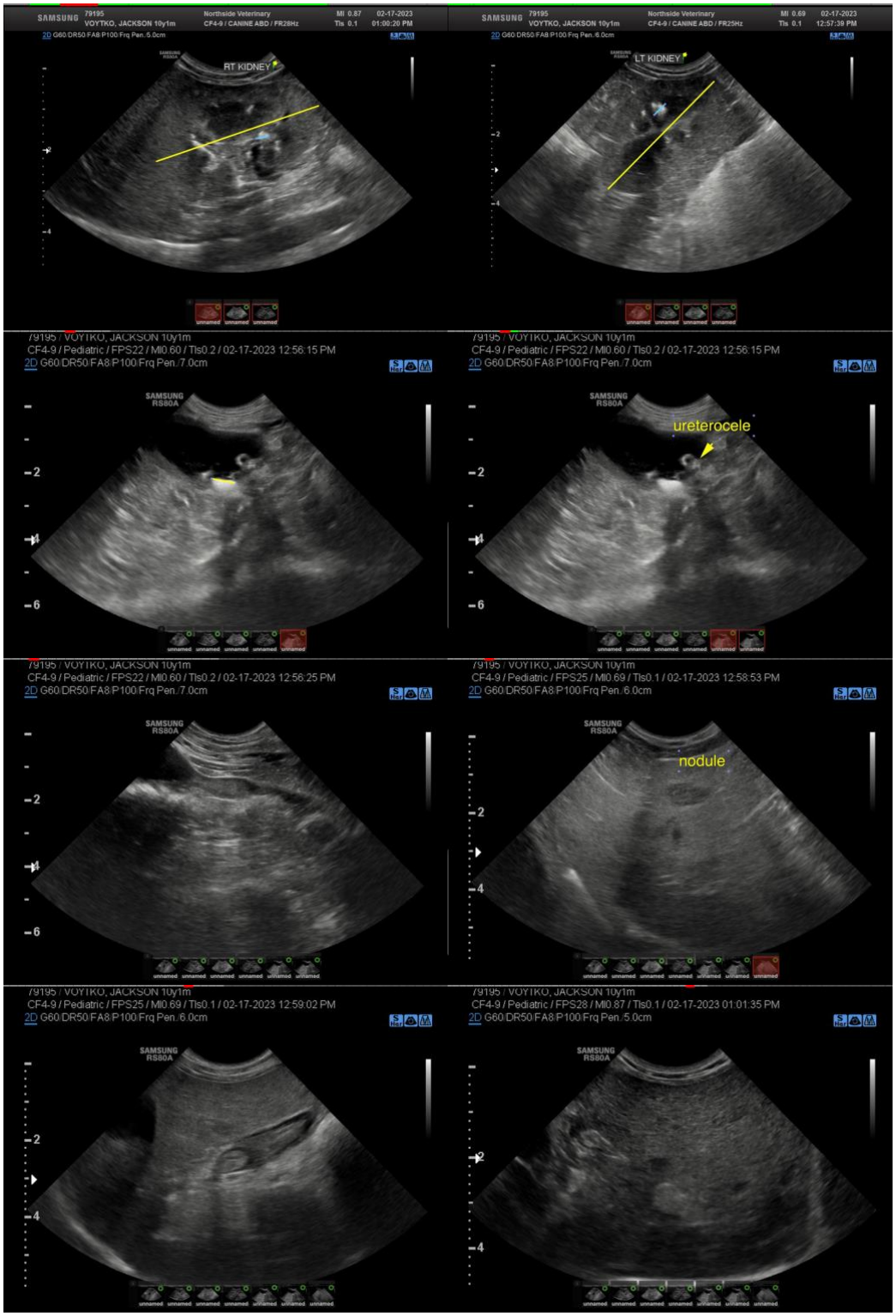

SonoPath
Clinical Sonography & Telecytology

EDUCATIONAL TELECONSULTATION SERVICES™

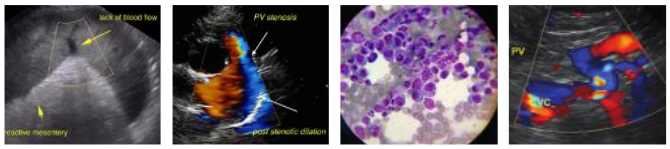

SonoPath.com™
1-800-838-4268 info@sonopath.com

PATIENT

Jackson Voytko

SPECIES

Canine

BREED

Mixed Breed

SEX

Neutered Male

AGE

10 Years

WEIGHT

19 Pounds

INTERPRETED BY

Eric Lindquist, DMV
DABVP, Cert. IVUSS

IMAGING PERFORMED BY

Griffin

HOSPITAL NAME

Northside VC

REFERRING VET

Dr. Griffin

INVOICE

21147

DATE

2/17/23

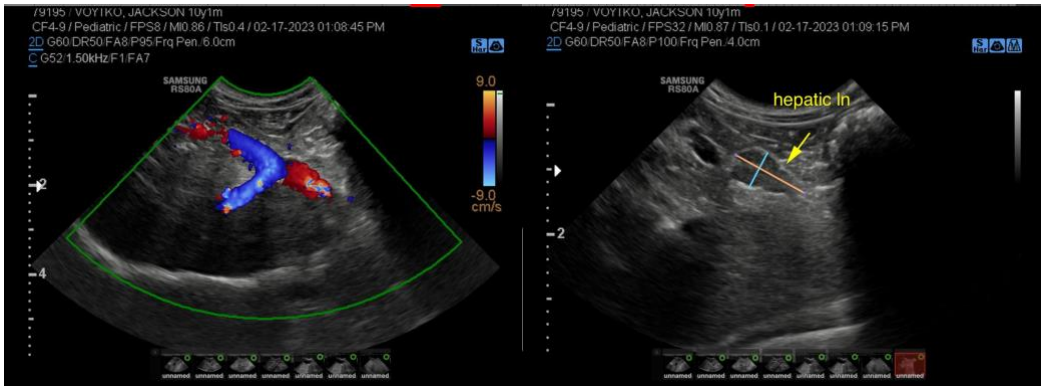

The information and recommendations provided are based on the images presented by the referring veterinarian. No evaluation can be communicated regarding pathology that was not visible in the image/video clips provided.

Thank you for this referral. If the clinical or image interpretation does not parallel your findings or if I can be of any further assistance please contact me.

Eric Lindquist, DMV, DABVP, Cert. IVUSS, CEO of SonoPath.com
info@SonoPath.com