



PATIENT

Viva Rand

SPECIES

Feline

BREED

Bengal

SEX

Spayed Female

AGE

8

WEIGHT

7.03

INTERPRETED BY

Eric Lindquist, DMV,
DABVP(CFM), Cert.
IVUSS

IMAGING PERFORMED BY

Dr. Brianna Gaines

HOSPITAL NAME

Healthy Pets
Veterinary Care- Boca
North

REFERRING VET

Dr. Brianna Gaines

INVOICE

13828

DATE

02/16/26

PRESENTING CLINICAL SIGNS

- Historic triaditis and low cobalamin - being supplemented with B12 weekly.

ULTRASONOGRAPHIC EXAMINATION OF THE ABDOMEN

Urinary System

The **urinary bladder**, trigone, and pelvic urethra to a depth of 1.0 cm presented normal thicknesses and normal tone. The ureters were not visible which is normal. No uroliths or sediment were visualized, and anechoic urine was present. No evidence of inflammatory or neoplastic changes were noted. Ureteral papillae were normal.

The **kidneys** revealed largely normal size and structure, corticomedullary definition and ratio (cortex 1/3 of medulla) were essentially maintained with some minor age-related loss of curvilinear patterns regarding the capsule and C/M junction. The cortices presented largely uniform texture with some increased echogenicity expected for his age patient. Medullary structure differed distinctly from that of the cortex and no evidence of pelvic dilation was present. The left kidney measured 3.3 cm in length. The right kidney measured 3.4 cm in length.

Adrenal Glands

Both **adrenal glands** were visualized and recognized as having normal shape, size, position and echogenicity for this breed. The phrenic vasculature, glandular echogenicity and detail were unremarkable. Capsule, cortex, and medullary definition were normal for this age patient. The left adrenal gland measured 0.40 cm width. The right adrenal gland measured 0.40 cm width.

Spleen

The **spleen** presented a smooth homogeneous parenchyma hyperechoic to liver and renal cortical parenchyma. The capsule was smooth without noticeable expansion or deviation from within the spleen or adjacent pathology. The splenic vasculature demonstrated normal volume without signs of congestion or thrombosis. No sonographic evidence of acute or chronic inflammatory, neoplastic, or infarctual changes were noted.

Liver

The **liver** images submitted revealed subjectively normal liver size, contour, and structure. Parenchymal echogenicity was naturally coarse and hypoechoic to the spleen. Vascular and biliary tracts were of normal volume with no evidence of congestion. The gallbladder presented acceptably thin walls with primarily anechoic content. The cystic and common bile ducts were normal. No pathological hepatic lymphadenopathy was evident. No overt structural evidence of inflammatory, infiltrative or regenerative pathology was evident.

Gastrointestinal

The **gastrointestinal** presentation revealed mild uniform prominence of the gastric mucosa as well as areas of "ropey" small intestinal wall with slight disruption of the normal 1:3 muscularis/mucosal ratio. The intestinal submucosa was slightly irregular, diffusely thickened and hyperechoic suggestive of low grade, chronic disease. No concerning lymphadenopathy was visible. No evidence of obstruction was present. Chronic inflammatory bowel disease is likely with a low possibility of an early neoplastic event such as lymphoma. Full thickness tissue biopsies via open laparotomy, ideally guided by intraoperative



PATIENT

ultrasound in order to obtain the most representative mural sample, would be necessary to rule out this possibility.

Viva Rand

Pancreas

SPECIES

Feline

The base and limbs of the **pancreas** were observed to be largely isoechoic to surrounding omental fat. Some parenchymal remodeling, however, with mild deviation from curvilinear normalcy was observed. Pancreatic duct and capsular irregularities were present consistent with age related changes. If pain upon imaging (+ Murphy sign) was present or if the patient is focally painful in subxiphoid palpation then low-grade smoldering chronic pancreatitis should be suspected.

BREED

Bengal

Free Abdomen

SEX

A minimal amount of abdominal fat was noted in this patient.

Spayed Female

ULTRASONOGRAPHIC FINDINGS

AGE

8

- Diffuse intestinal thickening consistent with inflammatory bowel.
- Unremarkable abdomen otherwise with age-related changes.

INTERPRETATION OF THE FINDINGS & FURTHER RECOMMENDATIONS

WEIGHT

7.03

No overt neoplastic criteria is present, however, cannot rule out a pre-neoplastic state. Full thickness gastrointestinal biopsy would be necessary for further definition.

INTERPRETED BY

Eric Lindquist, DMV,
DABVP(CFM), Cert.
IVUSS

Internal medicine consult can be utilized through SonoPath.com. You can select the internal medicine drop down at <http://spa.sonopath.com/>.

One of the world's top internists & SonoPath associate Dr. Remo Lobetti BVSc, MMedVet, PhD, DECVIM can evaluate your case through SonoPath. <https://sonopath.com/resources/sonopath-services/internal-medicine-teleconsultation-services>

IMAGING PERFORMED BY

Dr. Brianna Gaines

HOSPITAL NAME

Healthy Pets
Veterinary Care- Boca
North

REFERRING VET

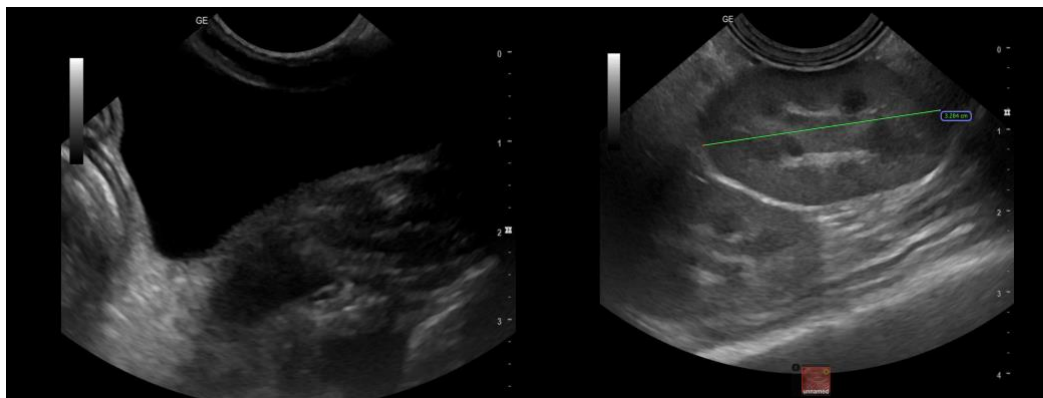
Dr. Brianna Gaines

INVOICE

13828

DATE

02/16/26





PATIENT

Viva Rand

SPECIES

Feline

BREED

Bengal

SEX

Spayed Female

AGE

8

WEIGHT

7.03

INTERPRETED BY

Eric Lindquist, DMV,
DABVP(CFM), Cert.
IVUSS

IMAGING PERFORMED BY

Dr. Brianna Gaines

HOSPITAL NAME

Healthy Pets
Veterinary Care- Boca
North

REFERRING VET

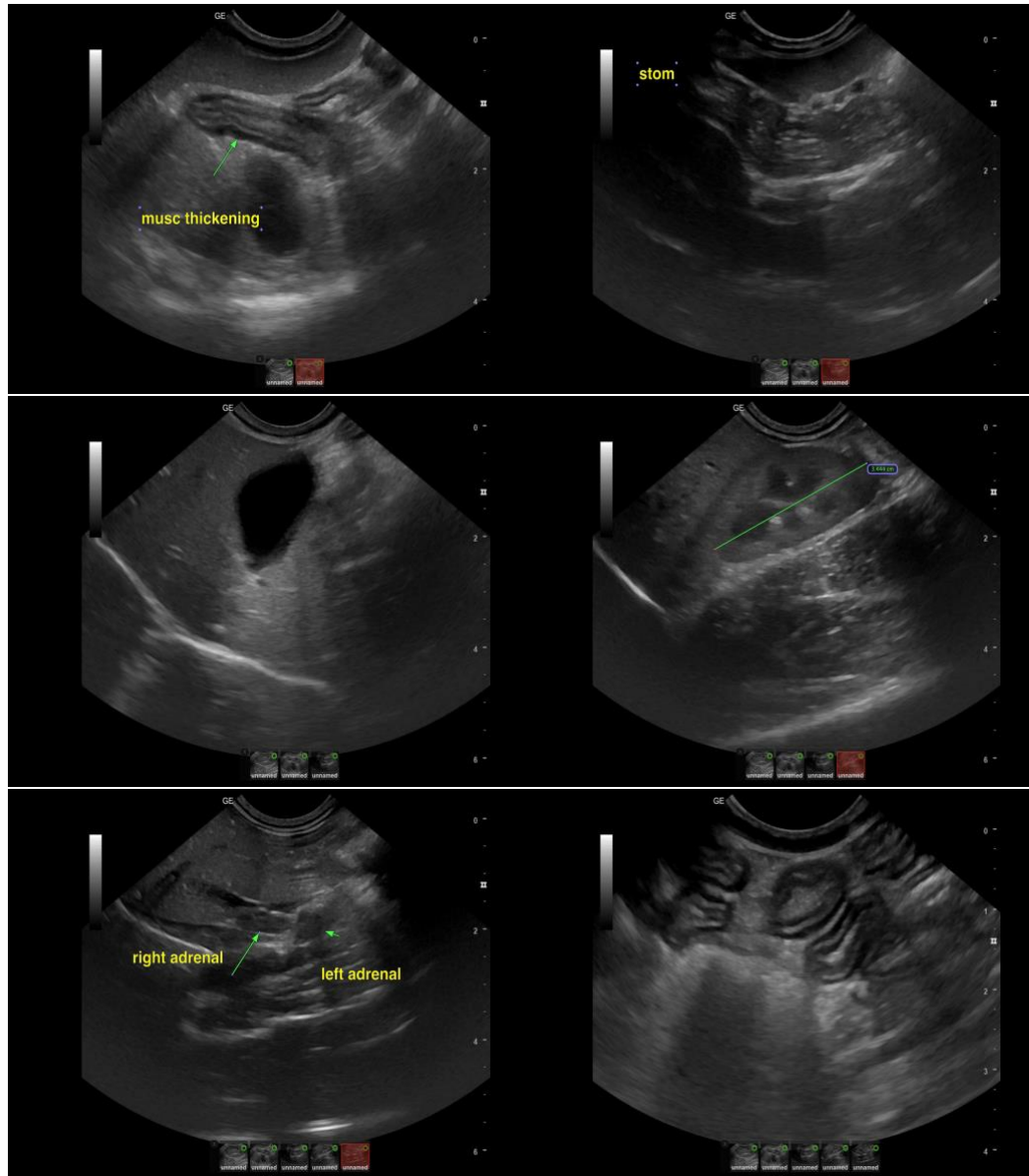
Dr. Brianna Gaines

INVOICE

13828

DATE

02/16/26



The information and recommendations provided are based on the images presented by the referring veterinarian/sonographer. No evaluation can be communicated regarding pathology that was not visible in the image/video clips provided.

Thank you for this referral. If the clinical or image interpretation does not parallel your findings or if I can be of any further assistance, please contact me.

Eric Lindquist, DMV, DABVP(CFM), Cert. IVUSS,

CEO, Owner, Founder -- SonoPath.com

info@SonoPath.com



PATIENT

Viva Rand

SPECIES

Feline

BREED

Bengal

SEX

Spayed Female

AGE

8

WEIGHT

7.03

INTERPRETED BY

Eric Lindquist, DMV,
DABVP(CFM), Cert.
IVUSS

IMAGING PERFORMED BY

Dr. Brianna Gaines

HOSPITAL NAME

Healthy Pets
Veterinary Care- Boca
North

REFERRING VET

Dr. Brianna Gaines

INVOICE

13828

DATE

02/16/26