



PATIENT

Lily Fransisco

SPECIES

Canine

BREED

Poodle Mix

SEX

Spayed Female

AGE

4

WEIGHT

54

INTERPRETED BY

Eric Lindquist, DMV,
DABVP(CFM), Cert.
IVUSS

IMAGING PERFORMED BY

Jenn

HOSPITAL NAME

Rockaway Animal
Hospital

REFERRING VET

Dr. Schiess

INVOICE

13821

DATE

02/16/26

PRESENTING CLINICAL SIGNS

- swallowed a potato suspect intestinal fb

Abnormal PE/Chem/CBC/UA Results: HCT 58% remainder CBC WNK Chem K Cl 105

ULTRASONOGRAPHIC EXAMINATION OF THE ABDOMEN

Urinary System

The **urinary bladder**, trigone, and pelvic urethra presented normal thicknesses and normal tone. The ureters were not visible which is normal. No uroliths or sediment were visualized, and anechoic urine was present. No evidence of inflammatory or neoplastic changes were noted. Ureteral papillae were normal.

The **kidneys** revealed normal size and structure, corticomedullary definition and ratio for this age. The cortices presented largely uniform texture with normal echogenic relationship to liver and spleen. Medullary structure differed distinctly from the cortex and no evidence of pelvic dilation was present. The capsules were acceptably uniform without significant irregularities. The left kidney measured 5.8 cm in length. The right kidney measured 6.0 cm in length.

Adrenal Glands

The **left adrenal gland** was visualized and recognized as having normal shape, size, position and echogenicity for this breed. The phrenic vasculature, glandular echogenicity and detail were unremarkable. Capsule, cortex, and medullary definition were normal for this age patient. The left adrenal gland measured 0.50 cm width.

The **right adrenal gland** was imaged with no evident pathology.

Spleen

The **spleen** was folded upon itself cranially.

Liver

The **liver** images submitted revealed subjectively normal liver size, contour, and structure. Parenchymal echogenicity was naturally coarse and hypoechoic to the spleen. Vascular and biliary tracts were of normal volume with no evidence of congestion. The gallbladder presented acceptably thin walls with primarily anechoic content. The cystic and common bile ducts were normal. No pathological hepatic lymphadenopathy was evident. No overt structural evidence of inflammatory, infiltrative or regenerative pathology was evident.

Gastrointestinal

The **stomach** revealed a shadowing foreign body measuring approximately 5.0 to 7.0 cm. This appears to be a fabric type density with a large amount of fluid stasis. The foreign body continued into the pylorus and into the small intestine with a linear attachment. Accordion pleading and intussusception was also present. A Slight amount of free fluid was present with enhanced mesentery.

Pancreas



PATIENT

Lily Fransisco

SPECIES

Canine

BREED

Poodle Mix

SEX

Spayed Female

AGE

4

WEIGHT

54

INTERPRETED BY

Eric Lindquist, DMV,
DABVP(CFM), Cert.
IUUSS

IMAGING PERFORMED BY

Jenn

HOSPITAL NAME

Rockaway Animal
Hospital

REFERRING VET

Dr. Schiess

INVOICE

13821

DATE

02/16/26

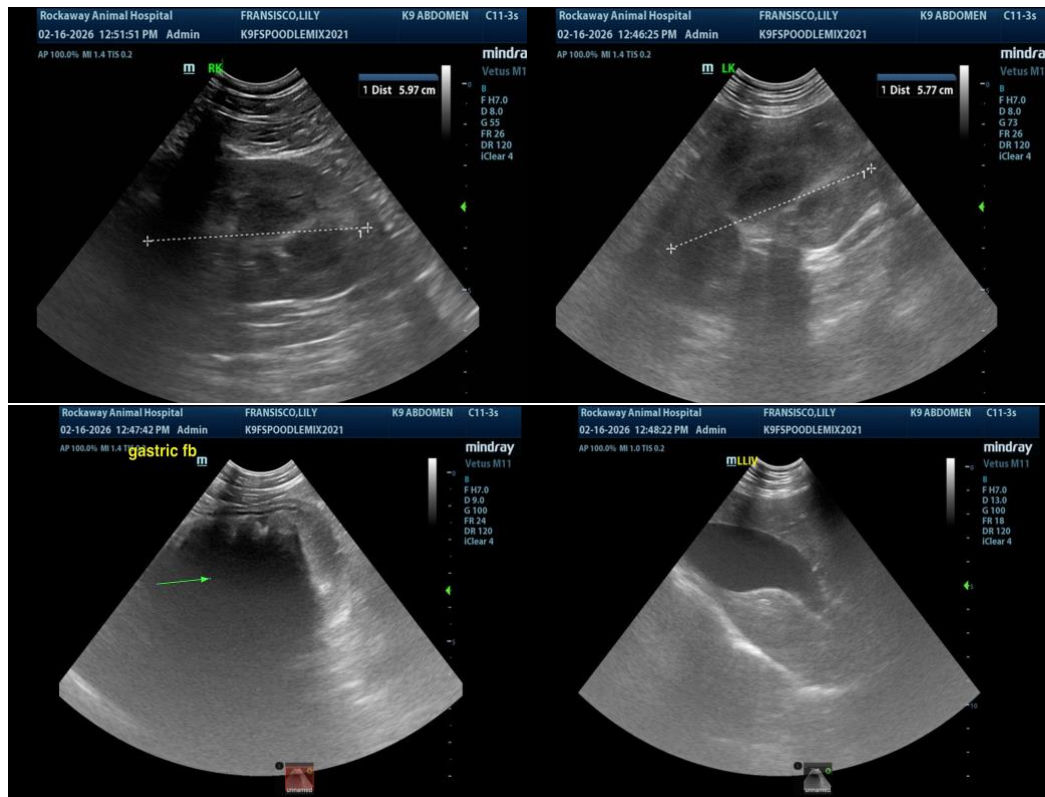
The base and limbs of the **pancreas** were observed to be largely isoechoic to surrounding omental fat. Pancreatic duct and capsular contour were acceptably normal and parenchyma respected normal curvilinear patterns. No overt evidence of active inflammatory or neoplastic disease was noted.

ULTRASONOGRAPHIC FINDINGS

- Folded spleen.
- GI fabric foreign body with linear attachment and intussusception.

INTERPRETATION OF THE FINDINGS & FURTHER RECOMMENDATIONS

Enterotomy and gastrotomy will be necessary in this patient with immediate exploratory surgery.





PATIENT

Lily Fransisco

SPECIES

Canine

BREED

Poodle Mix

SEX

Spayed Female

AGE

4

WEIGHT

54

INTERPRETED BY

Eric Lindquist, DMV,
DABVP(CFM), Cert.
IVUSS

IMAGING PERFORMED BY

Jenn

HOSPITAL NAME

Rockaway Animal
Hospital

REFERRING VET

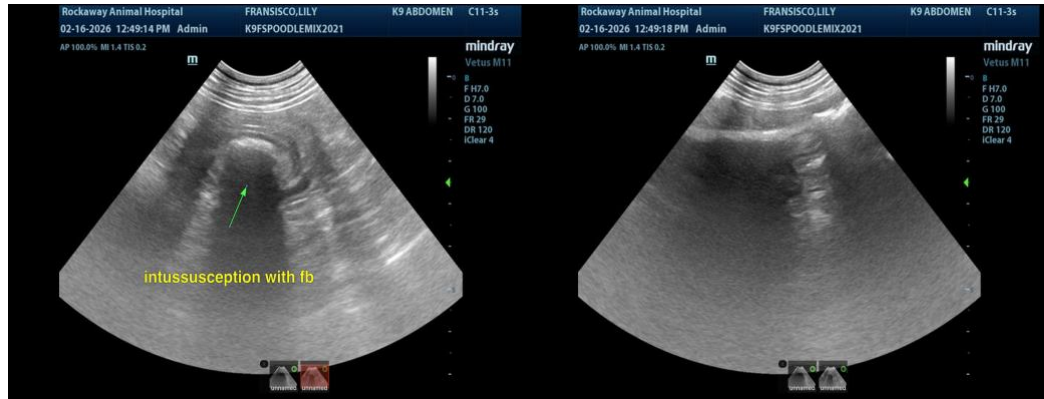Dr. Schiess

INVOICE

13821

DATE

02/16/26



The information and recommendations provided are based on the images presented by the referring veterinarian/sonographer. No evaluation can be communicated regarding pathology that was not visible in the image/video clips provided.

Thank you for this referral. If the clinical or image interpretation does not parallel your findings or if I can be of any further assistance, please contact me.

Eric Lindquist, DMV, DABVP(CFM), Cert. IVUSS,

CEO, Owner, Founder -- SonoPath.com

info@SonoPath.com