

## PATIENT

Princess Contreras

## SPECIES

Canine

## BREED

Maltese

## SEX

Spayed Female

## AGE

10 Years

## WEIGHT

11.1 Pounds

## PRESENTING CLINICAL SIGNS

History: Patient with history of seizures, presents for heart murmur, distended abdomen, abdominal ascites seen on radiographs, enlarged liver. Current meds: Phenobarb for seizures, Pimobendan 1.25 mgs BID.

Abnormal PE/Chem/CBC/UA Results: WBC 19,500, SAP 411, SGOT 243.

## ULTRASONOGRAPHIC EXAMINATION OF THE HEART

CANINE CARDIAC PARAMETERS	MR VMAX (m/s)	TR VMAX (m/s)	LA/AO (Boon method)	LA/AO (Heart Base; Swe)	FS (%)	EF (%)	EPSS (cm)
NORMAL PARAMETER	4.5-5.5	<2.7	1.3	<1.3	28-40	40-100	<0.6
PATIENT	6.0	5.0	2.0	1.4	48	83	0.1
CANINE CARDIAC PARAMETERS	HR (BPM)	AV VMAX (m/s)	PV MAX (m/s)	BODY WEIGHT (kg)	LA 2D short axis Base view (cm)	LVIDd Avg; 2D and m-mode short axis (cm)	LVIDs Avg; 2D and m-mode short axis (cm)
NORMAL PARAMETER	50-100	0.7-1.7	0.7-1.6				
PATIENT	126	1.27	3.5	--	--	1.67	--

## INTERPRETED BY

Eric Lindquist, DMV  
DABVP, Cert. IVUSS

## IMAGING PERFORMED BY

Kelly Vazquez

## HOSPITAL NAME

North Haledon VC

## REFERRING VET

Dr. Mansfield

## Cardiac Presentation

The **echocardiogram** presented a prominent **right heart** with mild **right ventricular** hypertrophy, and normal **right atrial** size. Severe tricuspid insufficiency was noted. No evidence of neoplasia was noted in the right auricle, or elsewhere in the heart. Pulmonic insufficiency was noted. No overt heartworms were noted in the main or visible deep pulmonary arteries, yet theoretically heartworms could be present in the deep pulmonary vasculature out of visible sonographic range. More likely, however, this prominent right heart is due to excessive intra-thoracic pressures caused by chronic respiratory disease or potentially excessive intra-thoracic fat (Pickwickian syndrome). Left atrial size was mildly enlarged (2.7 cm). Mitral insufficiency was noted. The **left ventricular outflow** demonstrated normal flow patterns and velocities through the aortic valve. No evidence of tumor. The visible **extra-cardiac** tissues were uniformly linear without evidence of masses, infiltrative or inflammatory mediastinal tissue. No evident arrhythmic activity was noted during the exam. This is a moderate change.

\*The hepatic veins and vena cava (1.07 cm at the level of the diaphragm) were dilated. A moderate amount of ascites was noted. Hepatic nodular changes were noted.

## INVOICE

21132

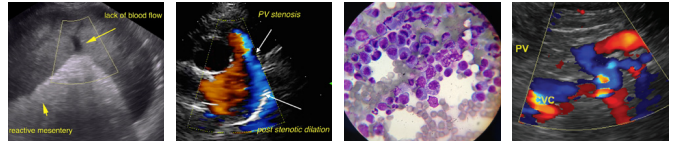
## DATE

2/16/23

## ULTRASONOGRAPHIC FINDINGS

- Right sided heart failure
- Mitral and tricuspid insufficiency
- Severe pulmonary hypertension

## INTERPRETATION OF THE FINDINGS & FURTHER RECOMMENDATIONS



**PATIENT**

Princess Contreras

The tricuspid insufficiency is a primary issue in this patient. I recommend adding to the Pimobendan, Sildenafil 1 mg/kg BID, increasing to 1.5 mg/kg BID after 2 weeks. Ace-inhibitor therapy 0.5 mg/kg SID and Spironolactone 1-2 mg/kg BID is indicated. Palliative abdominocentesis could be considered in this patient, given the abdominal distention. Prognosis is extremely guarded to poor. Recheck echo in one month. Patient is sudden death risk.

**SPECIES**

Canine

**BREED**

Maltese

**SEX**

Spayed Female

**AGE**

10 Years

**WEIGHT**

11.1 Pounds

**INTERPRETED BY**

Eric Lindquist, DMV  
DABVP, Cert. IVUSS

**IMAGING PERFORMED BY**

Kelly Vazquez

**HOSPITAL NAME**

North Haledon VC

**REFERRING VET**

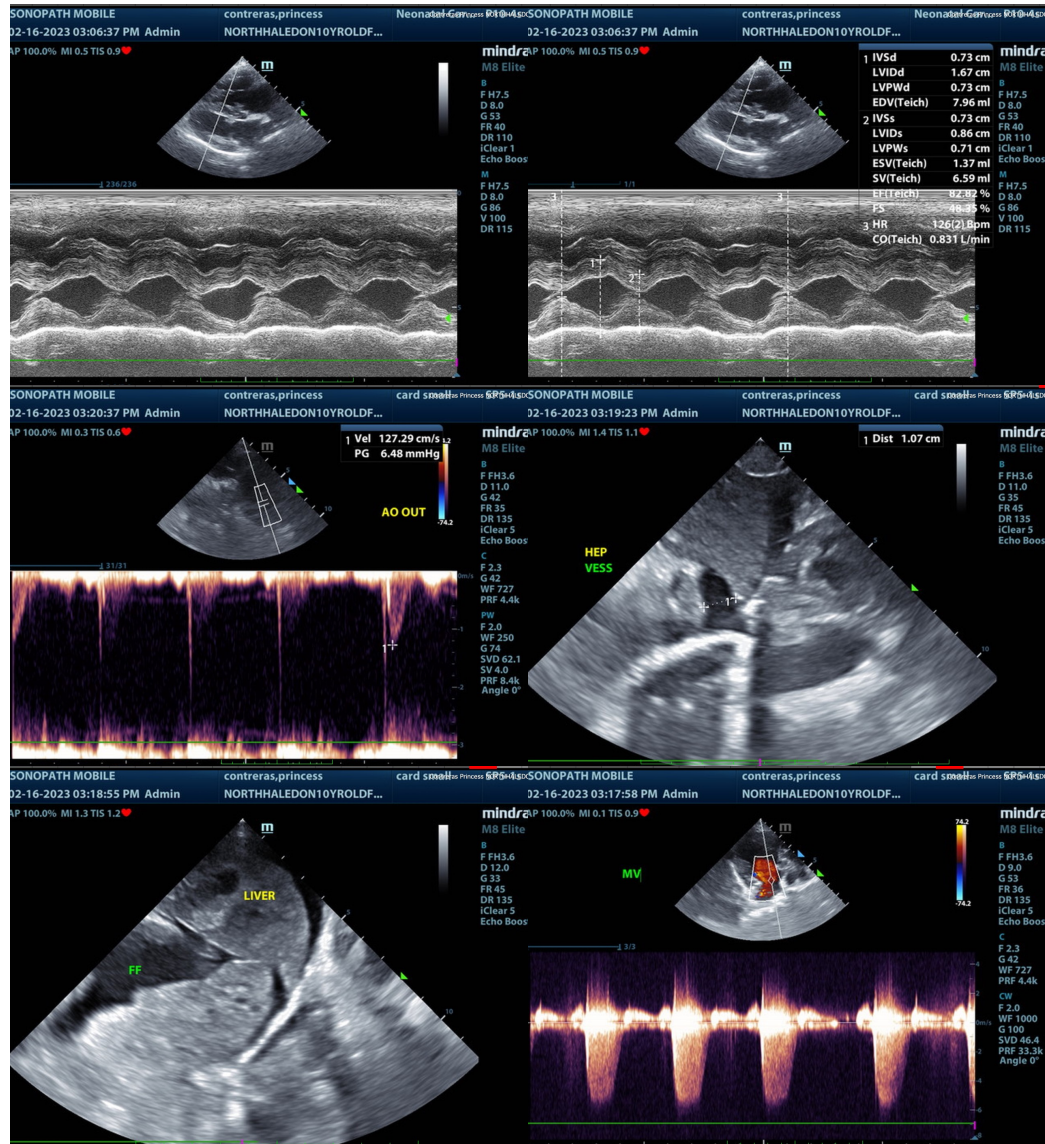
Dr. Mansfield

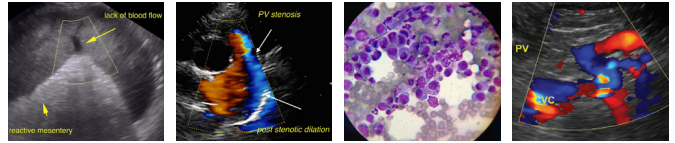
**INVOICE**

21132

**DATE**

2/16/23





**PATIENT**

Princess Contreras

**SPECIES**

Canine

**BREED**

Maltese

**SEX**

Spayed Female

**AGE**

10 Years

**WEIGHT**

11.1 Pounds

**INTERPRETED BY**

Eric Lindquist, DMV  
DABVP, Cert. IVUSS

**IMAGING PERFORMED BY**

Kelly Vazquez

**HOSPITAL NAME**

North Haledon VC

**REFERRING VET**

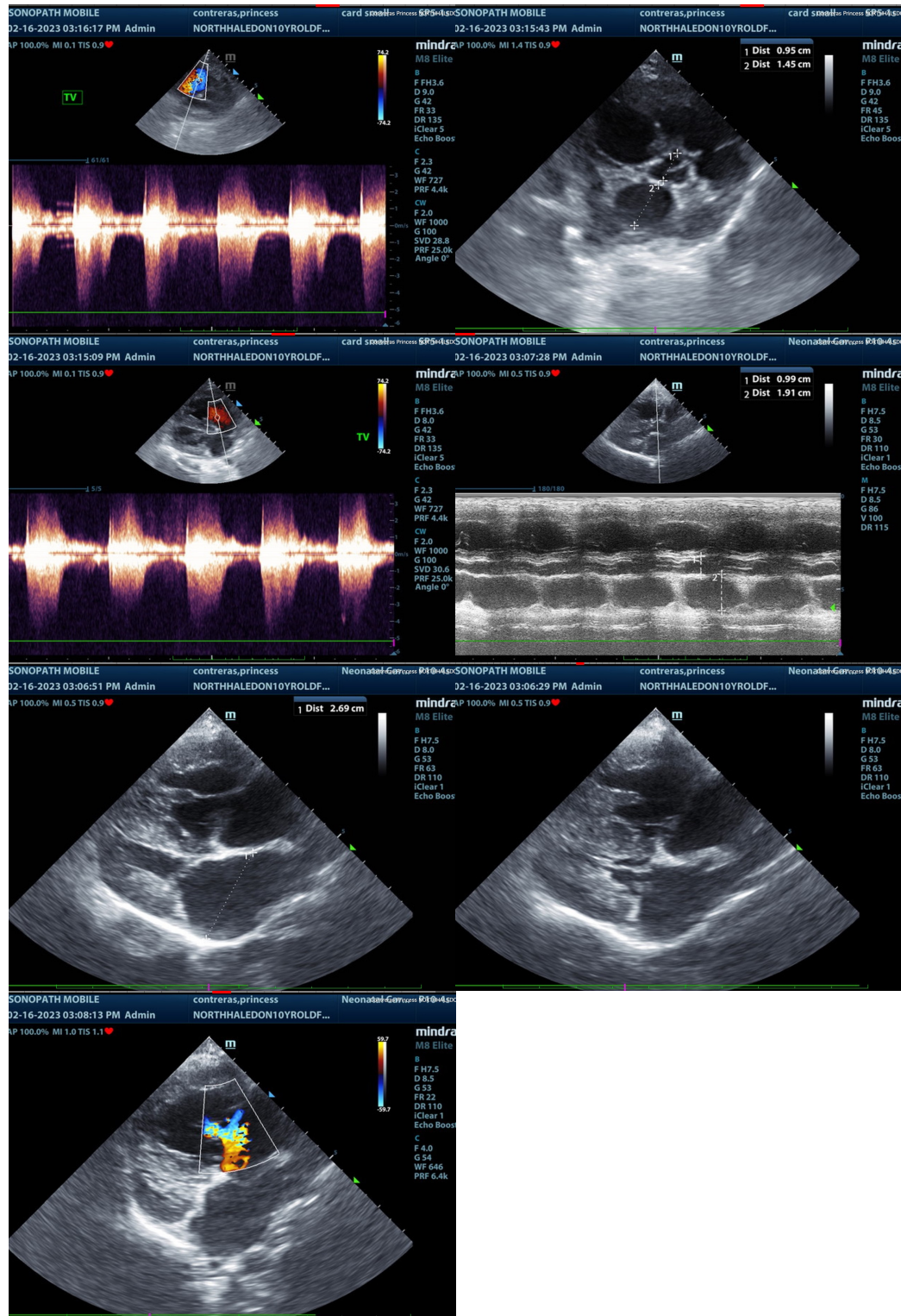
Dr. Mansfield

**INVOICE**

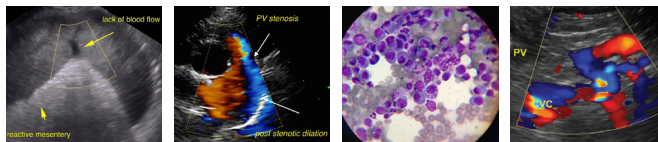
21132

**DATE**

2/16/23



The information and recommendations provided are based on the images presented by the referring veterinarian. No evaluation can be communicated regarding pathology that was not visible in the image/video clips provided.



**PATIENT**

Princess Contreras

Thank you for this referral. If the clinical or image interpretation does not parallel your findings or if I can be of any further assistance please contact me.

**SPECIES**

Canine

**Eric Lindquist**, DMV, DABVP, Cert. IVUSS, CEO of SonoPath.com  
info@SonoPath.com

**BREED**

Maltese

**SEX**

Spayed Female

**AGE**

10 Years

**WEIGHT**

11.1 Pounds

**INTERPRETED BY**

Eric Lindquist, DMV  
DABVP, Cert. IVUSS

**IMAGING  
PERFORMED BY**

Kelly Vazquez

**HOSPITAL NAME**

North Haledon VC

**REFERRING VET**

Dr. Mansfield

**INVOICE**

21132

**DATE**

2/16/23