



PATIENT

Misty Holman

SPECIES

Feline

BREED

Domestic Shorthair

SEX

Spayed female

AGE

8 months

WEIGHT

8.9 lbs

PRESENTING CLINICAL SIGNS

History: Patient had a URI in October, seemed improved until December but she was coughing more with some sneezing and notable upper airway noise. Trial of abx did resolve the matter until 2 weeks ago. The congestion noise is notable and the coughing has returned.

Abnormal PE/Chem/CBC/UA Results: AbPE: Notable upper inspiratory and expiratory noise, occasional cough. OWNL. Pending: PCR and culture for URI Thoracic X-rays do not reveal significant concerns, normal silhouette Skull rads do reveal slight increase opacity (more fluid) of the sinuses, no obvious architectural damage noted. Oral exam - only noted discharge, no obvious polyps

ULTRASONOGRAPHIC EXAMINATION OF THE HEART

The echocardiogram in this patient demonstrated normal **left atrial** size based on 3 separate LA measurements. The cranial and caudal **mitral** valve leaflets presented normal linear structure and kinetics. The **left ventricle** presented normal thicknesses with linear contour and was not dilated nor restricted. The **myocardium** presented normal echogenicity without subjective evidence of significant fibrotic or ischemic disease. **Contractility** of the ventricular walls was adequate and in normal range for this patient evidenced by the fractional shortening measurement and subjective evaluation of the different regions and angles of the myocardium. The **left ventricular outflow** tract demonstrated normal laminar flow and subjective structural integrity. The **right atrium** and auricle revealed normal size, structure and content. No evidence of masses was noted or chamber overload. Trivial **tricuspid** insufficiency was noted, yet not clinically significant. The **right ventricle** was of normal size (1/3 diameter of LV), chordae structure, myocardial echogenicity and thickness. **Pulmonic** tract assessment revealed normal valve structure, laminar flow, and diameter (approx. 1:1 pa/ao ratio). No visible **pericardial** or free pleura fluid was noted or extra cardiac pathology in the visible planes. The cranial **mediastinum and pericardial regions** were free of masses in the visible window.

INTERPRETED BY

Eric Lindquist, DMV
DABVP, Cert. IVUSS

IMAGING PERFORMED BY

Dr. Krell

HOSPITAL NAME

Paws and Prairie ACq

REFERRING VET

Dr. Krell

INVOICE

42860

DATE

2/16/23

FELINE CARDIAC PARAMETERS	BODY WEIGHT (kg)	HR (BPM)	IVSd (cm)	LVIDd (cm)	LVWd (cm)	FS (%)	EF (%)
NORMAL PARAMETER	-----	150-240	0.3-0.6	1.0-2.1	0.25-0.6	35-67	80-100
PATIENT		NM	0.5	1.4	0.5	50	
FELINE CARDIAC PARAMETERS	LA/AO (Boon)	LA/AO HEART BASE (Sisson)	LA 2D 4-chamber long axis AS to FW (Sisson) (cm)	LVOT VEL. (m/s)	RVOT VEL. (m/s)	IVRT (m/)	
NORMAL PARAMETER	<1.5	0.88-1.79	0.7-1.7	<1.6	<1.3	40-60	
PATIENT	1.2	1.1	1.14	NM	0.8	NM	
Adapted from June Boon, Veterinary Echocardiography, 1998 Sisson D et al. JVIM 1991; 5: 232, Jacobs et al. Am J Vet Res 1985; 46:1705							



PATIENT

Misty Holman

ULTRASONOGRAPHIC FINDINGS

Normal echocardiogram with trivial tricuspid insufficiency.

SPECIES

Feline

INTERPRETATION OF THE FINDINGS & FURTHER RECOMMENDATIONS

There is no evidence of cardiac disease. Primary respiratory protocol is warranted given the patient's history. There is no cardiac influence upon the respiratory signs.

BREED

Domestic Shorthair

SEX

Spayed female

AGE

8 months

WEIGHT

8.9 lbs

INTERPRETED BY

Eric Lindquist, DMV
DABVP, Cert. IVUSS

IMAGING PERFORMED BY

Dr. Krell

HOSPITAL NAME

Paws and Prairie ACq

REFERRING VET

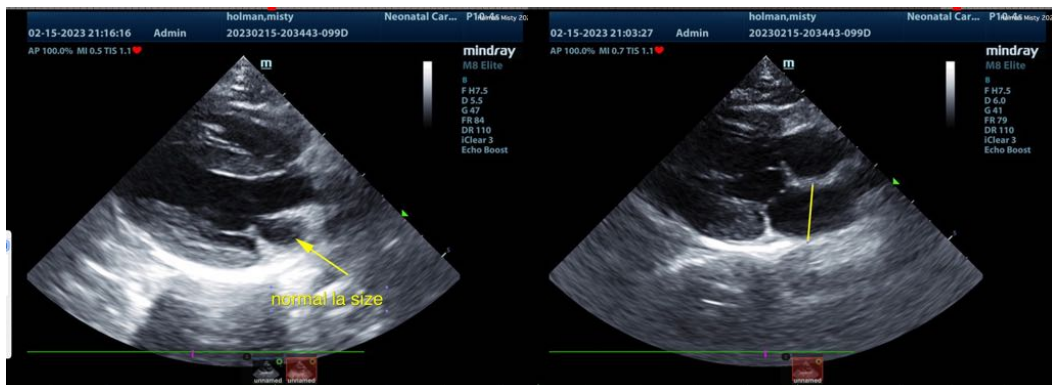
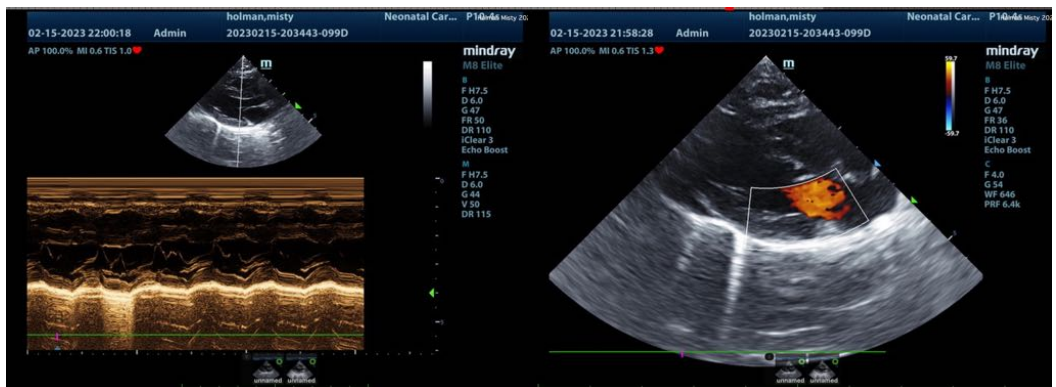
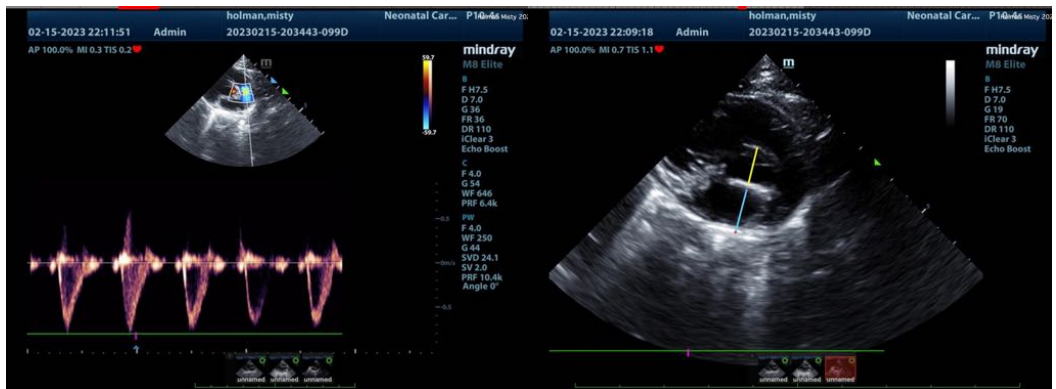Dr. Krell

INVOICE

42860

DATE

2/16/23





PATIENT

Misty Holman

SPECIES

Feline

BREED

Domestic Shorthair

SEX

Spayed female

AGE

8 months

WEIGHT

8.9 lbs

INTERPRETED BY

Eric Lindquist, DMV
DABVP, Cert. IVUSS

**IMAGING
PERFORMED BY**

Dr. Krell

HOSPITAL NAME

Paws and Prairie ACq

REFERRING VET

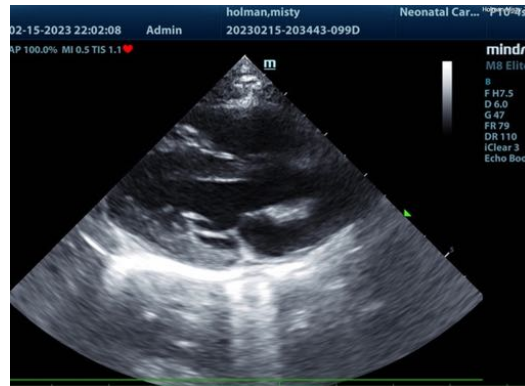
Dr. Krell

INVOICE

42860

DATE

2/16/23



The information and recommendations provided are based on the images presented by the referring veterinarian/sonographer. No evaluation can be communicated regarding pathology that was not visible in the image/video clips provided.

Thank you for this referral. If the clinical or image interpretation does not parallel your findings or if I can be of any further assistance please contact me.

Eric Lindquist, DMV, DABVP, Cert. IVUSS, CEO of SonoPath.com
info@SonoPath.com