SonoPath
Clinical Sonography & Telecytology

EDUCATIONAL TELECONSULTATION SERVICES™

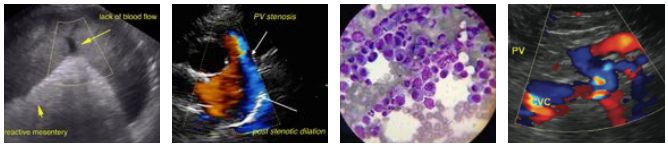

SonoPath.com™
1-800-838-4268 info@sonopath.com

PATIENT

Brody Duren

SPECIES

Canine

BREED

Pomeranain Mix

SEX

Neutered male

AGE

13 years

WEIGHT

15 lbs

INTERPRETED BY

Eric Lindquist, DMV DABVP, Cert. IVUSS

IMAGING PERFORMED BY

Jill Rumachik

HOSPITAL NAME

Clarity Imaging LLC

REFERRING VET

Tanya Hoffman

INVOICE

42859

DATE

2/16/23

PRESENTING CLINICAL SIGNS

History: Increasing heart murmur noted in the past several years; elevated proBNP noted earlier this month; elevated SDMA/BUN in the past month; elevated ALT, AST, ALP (not new - but rising); pursuing echo for pre-op dental (3/4 periodontal disease)

ULTRASONOGRAPHIC EXAMINATION OF THE HEART

The echocardiogram in this patient demonstrated normal **left atrial** size based on 3 different LA measurement methods. Chamber volumes and echogenicity were normal. The cranial and caudal **mitral** valve leaflets presented vegetative thickening consistent with endocardiosis. Doppler indicated measurable insufficiency. The **left ventricle** presented thicknesses with linear contour and was not dilated nor restricted. The **myocardium** presented normal echogenicity without subjective evidence of significant fibrotic or ischemic disease. **Contractility** of the ventricular walls was adequate and in normal range for this patient evidenced by the fractional shortening measurement and subjective evaluation of the different regions of the myocardium. The **left ventricular outflow** tract demonstrated normal laminar flow and subjective structural integrity. The **right atrium** and auricle revealed normal size, structure and content. No evidence of masses was noted or chamber overload. **Tricuspid** valvular assessment demonstrated adequate linear morphology. The **right ventricle** was of normal size (1/3 diameter of LV), chordae structure, myocardial echogenicity and thickness. **Pulmonic** tract assessment revealed normal valve structure, laminar flow, and diameter (approx.1:1 pa/ao ratio). No visible **pericardial** or free pleura fluid was noted. No echographically detectable evidence of infiltrative disease was visible. The cranial **mediastinum and pericardial regions** were free of masses in the visible window.

CANINE CARDIAC PARAMETERS	MR VMAX (m/s)	TR VMAX (m/s)	LA/AO (Boon method)	LA/AO (Heart Base;)	FS (%)	EF (%)	EPSS (cm)
NORMAL PARAMETER	4.5-5.5	<2.7	1.3	<1.6	28-40	40-100	<0.6
PATIENT			1.4	1.8			0.1
CANINE CARDIAC PARAMETERS	**HR** (BPM)	**AV VMAX** (m/s)	**PV MAX** (m/s)	**BODY WEIGHT**	**LA** 2D short axis Base view (cm)	**LVIDd** Avg; 2D and m-mode short axis (cm)	**LVIDs** Avg; 2D and m-mode short axis (cm)
NORMAL PARAMETER	50-100	0.7-1.7	0.7-1.6	BELOW	BELOW	BELOW	BELOW
PATIENT		1.1	NM	15 lbs	3.8 max	3.4	

SonoPath
Clinical Sonography & Telecytology

EDUCATIONAL TELECONSULTATION SERVICES™

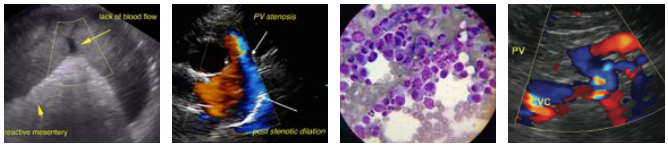

SonoPath.com™
1-800-838-4268 info@sonopath.com

PATIENT

Brody Duren

SPECIES

Canine

BREED

Pomeranain Mix

SEX

Neutered male

AGE

13 years

WEIGHT

15 lbs

INTERPRETED BY

Eric Lindquist, DMV
DABVP, Cert. IVUSS

IMAGING PERFORMED BY

Jill Rumachik

HOSPITAL NAME

Clarity Imaging LLC

REFERRING VET

Tanya Hoffman

INVOICE

42859

DATE

2/16/23

ULTRASONOGRAPHIC FINDINGS

Mitral insufficiency.

Mild left atrial enlargement.

Early stage B2 valvular disease.

INTERPRETATION OF THE FINDINGS & FURTHER RECOMMENDATIONS

The heart has some volume overload and is working to compensate for the valvular insufficiency. Target respiratory rate is < 20 resp/minute after therapy. After initiating therapy, I recommend recheck on the clinical exam, BUN, Creatinine, USG, Chest radiographs & Blood pressure in 5-7 days. Recheck echo in 1 month. Earlier if clinical decompensation is occurring. I do not recommend anesthesia at this time until stabilization has occurred on the recommended medications. Repeat preanesthetic echo is ideal if anesthesia is eventually necessary

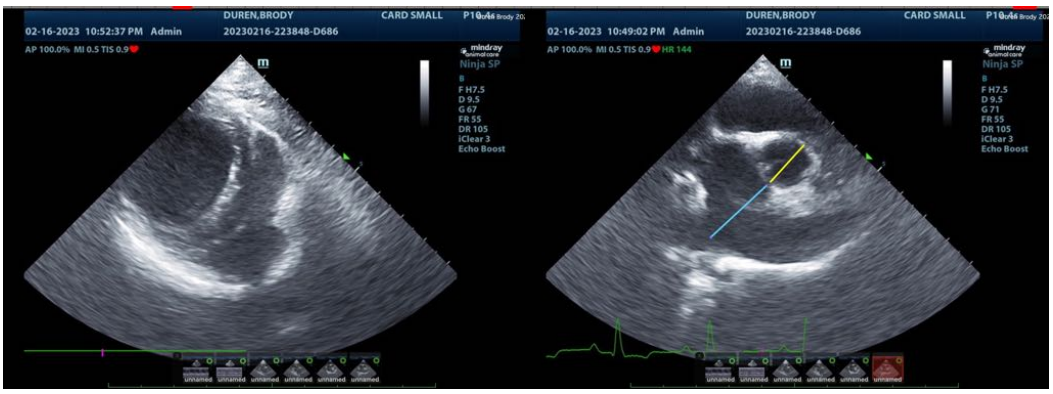

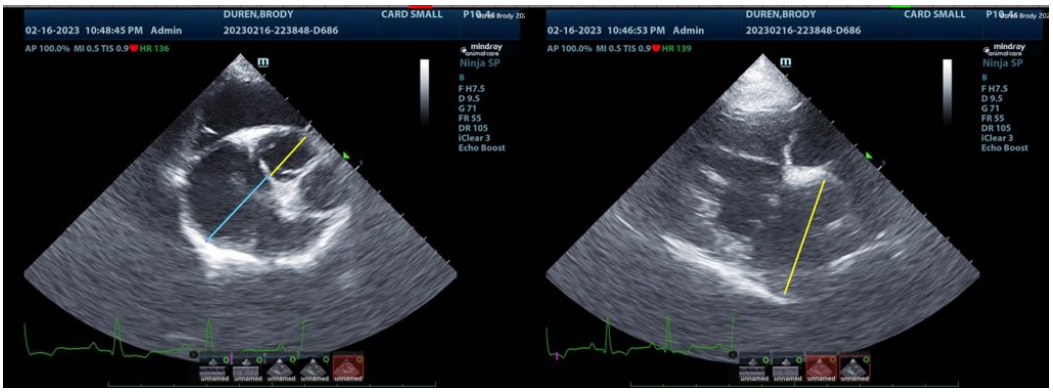

SonoPath
Clinical Sonography & Telecytology

EDUCATIONAL TELECONSULTATION SERVICES™

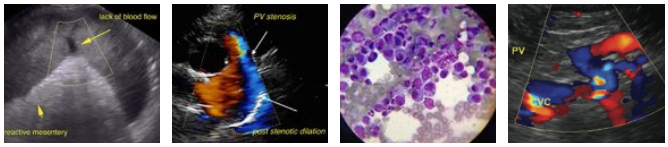

SonoPath.com™
1-800-838-4268 info@sonopath.com

PATIENT

Brody Duren

SPECIES

Canine

BREED

Pomeranain Mix

SEX

Neutered male

AGE

13 years

WEIGHT

15 lbs

INTERPRETED BY

Eric Lindquist, DMV DABVP, Cert. IVUSS

IMAGING PERFORMED BY

Jill Rumachik

HOSPITAL NAME

Clarity Imaging LLC

REFERRING VET

Tanya Hoffman

INVOICE

42859

DATE

2/16/23

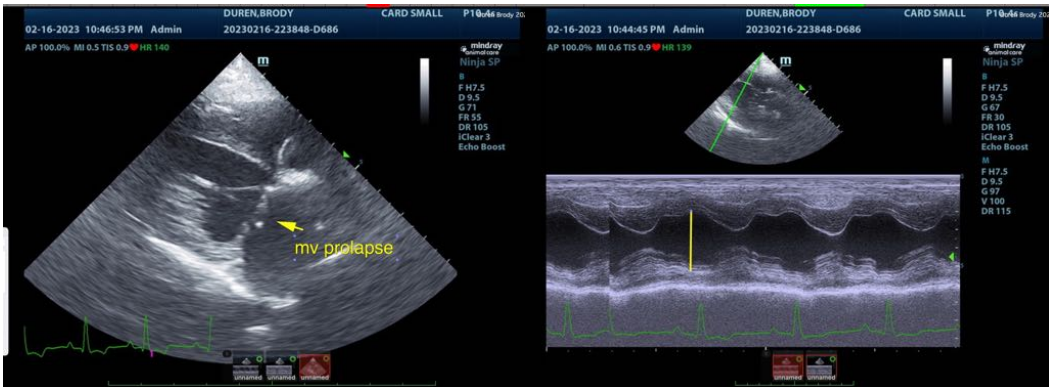

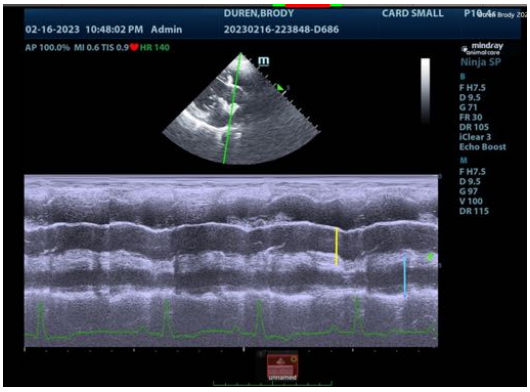

The information and recommendations provided are based on the images presented by the referring veterinarian/sonographer. No evaluation can be communicated regarding pathology that was not visible in the image/video clips provided.

Thank you for this referral. If the clinical or image interpretation does not parallel your findings or if I can be of any further assistance please contact me.

Eric Lindquist, DMV, DABVP, Cert. IVUSS, CEO of SonoPath.com
info@SonoPath.com