



**PATIENT**

Tiki Hammell

**SPECIES**

Canine

**BREED**

Beagle Mix

**SEX**

Neutered male

**AGE**

14 years

**WEIGHT**

48 lbs

**INTERPRETED BY**

Eric Lindquist, DMV  
DABVP, Cert. IVUSS

**IMAGING PERFORMED BY**

Dr. ammeraal

**HOSPITAL NAME**

Sova AH

**REFERRING VET**

Dr. Ammeraal

**INVOICE**

42847

**DATE**

2/15/23

**PRESENTING CLINICAL SIGNS**

History: Presenting for chronic Hematuria , Had a course of Doxycycline and Enrofloxacin , Hematuria stops then returns  
Abnormal PE/Chem/CBC/UA Results: Hairloss ventral abdomen, Grade 3/4 dental disease

**ULTRASONOGRAPHIC EXAMINATION OF THE ABDOMEN**

**Urinary System**

The **urinary bladder**, trigone, and pelvic urethra presented normal thicknesses and normal tone. The ureters were not visible which is normal. The bladder revealed dependent and suspended debris and concentric mural thickening. Minor micropolypoid changes were noted.

The residual prostate measured 1.0 cm.

The left kidney revealed an expansive parenchymal mass that measured 6.0 cm with an adjacent anechoic cyst. The cyst measured 2.0 cm. Regional inflammation was noted without capsular escape. The left kidney measured 6.6 cm. The right kidney was unremarkable and measured 7.4 cm.

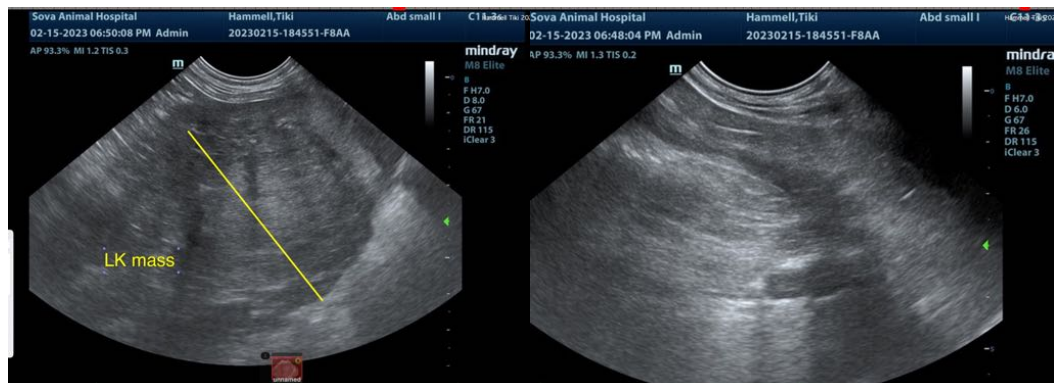
**ULTRASONOGRAPHIC FINDINGS**

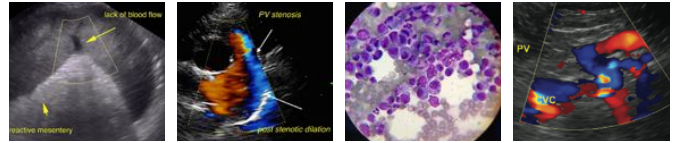
Left renal mass. Suspect carcinoma, hemangiosarcoma and less likely round cell neoplasia.

Chronic cystitis bladder pattern.

**INTERPRETATION OF THE FINDINGS & FURTHER RECOMMENDATIONS**

I recommend full abdominal sonogram +/- abdominal and chest CT to assess for metastatic disease followed by left nephrectomy. Some of the debris may be blood clots deriving from the renal pathology.





**PATIENT**

Tiki Hammell

**SPECIES**

Canine

**BREED**

Beagle Mix

**SEX**

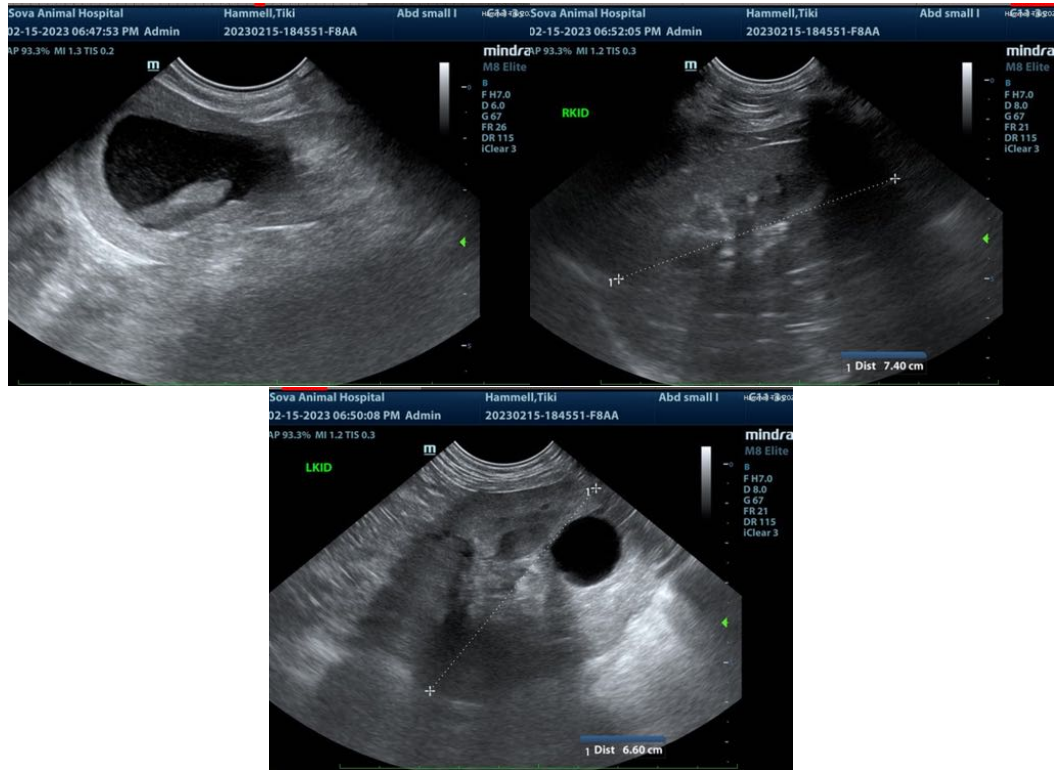
Neutered male

**AGE**

14 years

**WEIGHT**

48 lbs



**INTERPRETED BY**

Eric Lindquist, DMV  
DABVP, Cert. IVUSS

**IMAGING PERFORMED BY**

Dr. ammeraal

**HOSPITAL NAME**

Sova AH

**REFERRING VET**

Dr. Ammeraal

**INVOICE**

42847

**DATE**

2/15/23

The information and recommendations provided are based on the images presented by the referring veterinarian/sonographer. No evaluation can be communicated regarding pathology that was not visible in the image/video clips provided.

Thank you for this referral. If the clinical or image interpretation does not parallel your findings or if I can be of any further assistance please contact me.

**Eric Lindquist, DMV, DABVP, Cert. IVUSS, CEO of SonoPath.com**  
info@SonoPath.com