

**DATE**

2/15/23

PRESENTING CLINICAL SIGNS

History of increased thirst/urination, good appetite. Hx elevated liver values, pot bellied appearance, muscle wasting

PATIENT

Lucky Chiang

Current Medications: HG and NG.

SPECIES

Canine

Lab Results: CBC - unremarkable (hct 47.9%, WBC 8.1K, plt 393K)

Chem - BG 57 (L) (sample sitting out for extended period of time?); ALT 184 (H); AST 61 (H); ALKP 241 (H); TP 7.6 (mild H; ref 5.5-7.5); Cl 104 (L). Rest of chem WNL. (BUN 31, CRE 0.8, tbili 0.1). Total T4 - 2 (normal). UA: USG 1.019, pH 7.0, protein 1+, RBC 6-10/hpf, WBC 0-2/hpf, non crystalline debris.

Date of Previous IntraPet Ultrasound: No previous.

BREED

Standard Schnauzer

Sedation: Not required to complete full diagnostic ultrasound.

Stat Report: Not requested.

Imaging Performed By: Rachel Brillhart, RDMS.

SEX

Neutered Male

ULTRASONOGRAPHIC EXAMINATION OF THE ABDOMEN**AGE**

5/1/07

Urinary System

The **urinary bladder**, trigone, and pelvic urethra presented normal thicknesses and normal tone. The ureters were not visible which is normal. No uroliths or sediment were visualized and anechoic urine was present. No evidence of inflammatory or neoplastic changes were noted. Ureteral papillae were normal.

WEIGHT

11.2 Pounds

The residual prostate was uniform at 1.22 cm.

INTERPRETED BY

Eric Lindquist, DMV
DABVP, Cert. IVUSS

The **kidneys** revealed largely normal size and structure, corticomedullary definition and ratio (cortex 1/3 of medulla) were essentially maintained with some age-related loss of curvilinear patterns regarding the capsule and C/M junction. The cortices presented largely uniform texture with some increased echogenicity expected for his age patient. Medullary structure differed distinctly from that of the cortex and no evidence of pelvic dilation was present. Mineralization noted in both kidneys, non-obstructive. The right kidney measured 2.92 cm. The left kidney measured 4.53 cm.

HOSPITAL NAME

Clarksville PetVet

Adrenal Glands

Both **adrenal glands** were visualized and recognized as having normal shape, size, position and echogenicity for this breed. The phrenic vasculature, glandular echogenicity and detail were unremarkable. Capsule, cortex, and medullary definition were normal for this age patient. The right adrenal gland measured 2.12 cm x 0.47 cm at the caudal pole and 0.46 cm at the cranial pole. The left adrenal gland measured 1.43 cm x 0.48 cm at the caudal pole and 0.49 cm at the cranial pole.

REFERRING VET

Dr. Martof

Spleen

The **spleen** was largely smooth with subtle heterogeneous parenchymal changes while maintaining normal echogenic relationship to the liver and kidney. These changes are consistent with normal age-related alteration. The capsule was smooth without noticeable impingement from within the spleen or from pathology in the adjacent abdomen. The splenic vasculature demonstrated normal volume without signs of congestion or significant contraction. No evidence of active acute or chronic inflammatory, neoplastic, or infarctual changes were noted.

INVOICE

45161

Liver

The **liver** presented heterogenous parenchyma with increased portal markings and coarse architecture. Slight undulating capsular contour was noted. The gallbladder and common bile duct were unremarkable. This is consistent with chronic inflammatory hepatopathy.

Gastrointestinal

Examination of the **gastrointestinal tract** revealed a stomach and intestine free of stasis, of normal wall thickness, acceptable curvilinear mural detail, and peristaltic activity. Small and large intestine demonstrated normal luminal chyme and stool consistency respectively. No obstructive or overt infiltrative disease was noted. No associated abnormal lymphatic activity was noted.

Pancreas

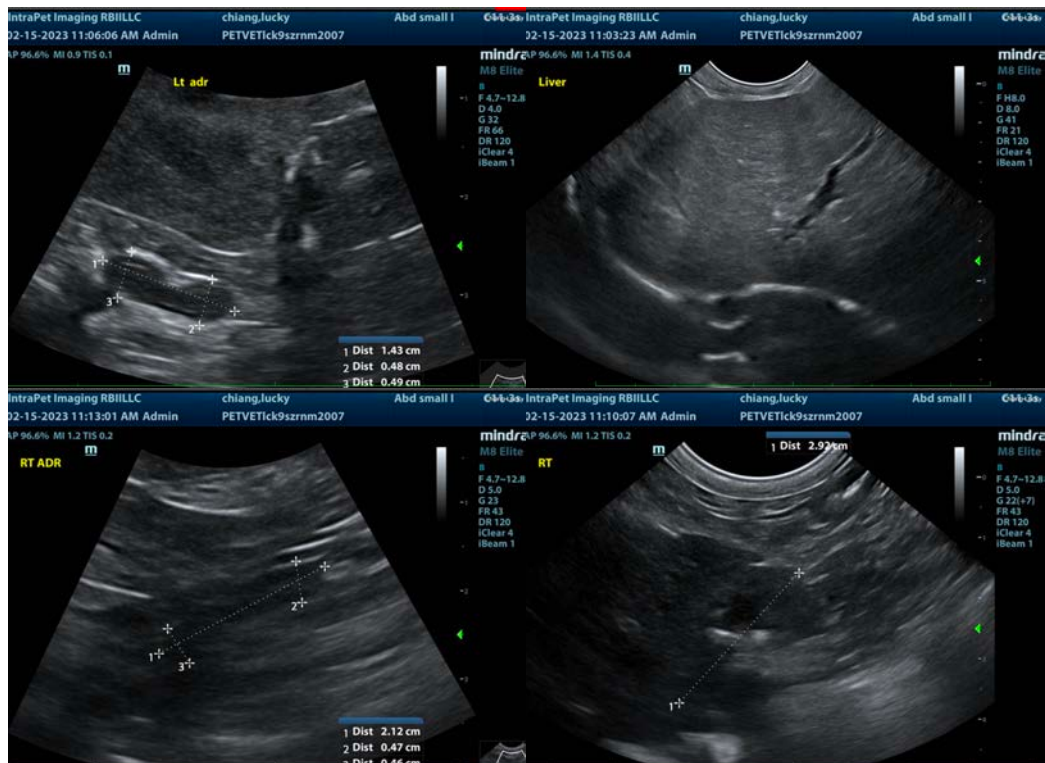
The base and limbs of the **pancreas** were observed to be largely isoechoic to surrounding omental fat. Pancreatic duct and capsular contour were acceptably normal and parenchyma respected normal curvilinear patterns. No overt evidence of active inflammatory or neoplastic disease was noted.

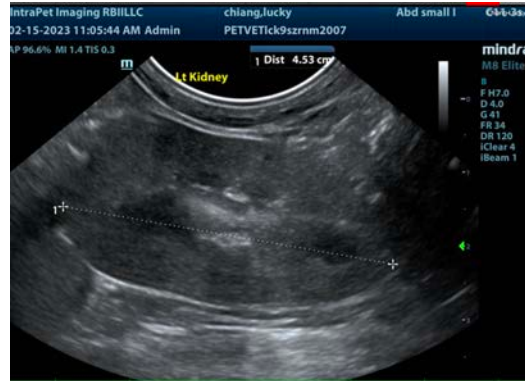ULTRASONOGRAPHIC FINDINGS

- Subjectively benign hepatopathy with remodeling and inflammatory component – subjectively benign.
- Age related renal changes with mineralization, non-obstructive
- Age related splenic changes

INTERPRETATION OF THE FINDINGS & FURTHER RECOMMENDATIONS

Screening FNA of the liver and spleen could be considered for further definition. However, subjectively they appear benign. The cause of PU/PD is unclear. However, periodic passage of calculi may be playing a role. Emerging PDH possible even though the adrenals are structurally normal at this time.





The information and recommendations provided are based on the images presented by the referring veterinarian/sonographer. No evaluation can be communicated regarding pathology that was not visible in the image/video clips provided.

Thank you for this referral. If the clinical or image interpretation does not parallel your findings or if I can be of any further assistance please contact me.

Eric Lindquist, DMV, DABVP, Cert. IVUSS, CEO of SonoPath.com
info@SonoPath.com