



**PATIENT**

Laguna Dorris

**SPECIES**

Canine

**BREED**

Labrador Retriever

**SEX**

Spayed female

**AGE**

1 year

**WEIGHT**

46.8 lbs

**INTERPRETED BY**

Eric Lindquist, DMV  
DABVP, Cert. IVUSS

**IMAGING PERFORMED BY**

Dr. Dorris

**HOSPITAL NAME**

County Line VC

**REFERRING VET**

Dr. Dorris

**INVOICE**

42849

**DATE**

2/15/23

**PRESENTING CLINICAL SIGNS**

History: dribbling urine, vomiting bile at least 4 times a week  
Abnormal PE/Chem/CBC/UA Results: blood work and urinalysis WNL

**ULTRASONOGRAPHIC EXAMINATION OF THE ABDOMEN**

**Urinary System**

The **urinary bladder**, trigone, and pelvic urethra presented normal thicknesses and normal tone. The ureters were not visible which is normal. No uroliths or sediment were visualized and anechoic urine was present. No evidence of inflammatory or neoplastic changes was noted. Ureteral papillae were normal.

The **kidneys** revealed normal size and structure, corticomedullary definition and ratio for this age. The cortices presented largely uniform texture with normal echogenic relationship to liver and spleen. Medullary structure differed distinctly from the cortex and no evidence of pelvic dilation was present. The capsules were acceptably uniform without significant irregularities. The left kidney measured 5.4 cm. The right kidney measured 6.0 cm.

**Adrenal Glands**

The left adrenal gland was visualized obliquely and measured 0.5 cm. The right adrenal gland was visualized obliquely and measured 0.6 cm.

**Spleen**

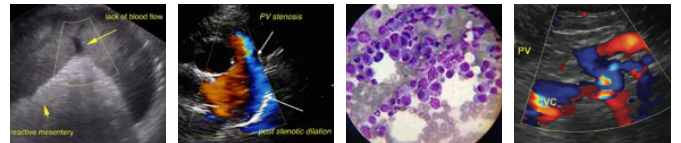
The **spleen** presented a smooth homogeneous parenchyma hyperechoic to liver and renal cortical parenchyma. The capsule was smooth without noticeable expansion or deviation from within the spleen or adjacent pathology. The splenic vasculature demonstrated normal volume without signs of congestion or thrombosis. No sonographic evidence of acute or chronic inflammatory, neoplastic, or infarctual changes was noted.

**Liver**

The **liver** images submitted revealed subjectively normal liver size, contour, and structure. Parenchymal echogenicity was naturally coarse and hypoechoic to the spleen. Vascular and biliary tracts were of normal volume with no evidence of congestion. The gallbladder presented acceptably thin walls with primarily anechoic content. The cystic and common bile ducts were normal. No pathological hepatic lymphadenopathy was evident. No overt structural evidence of inflammatory, infiltrative or regenerative pathology was evident.

**Gastrointestinal**

Examination of the **gastrointestinal tract** revealed a stomach and intestine free of stasis, of normal wall thickness, acceptable curvilinear mural detail, and peristaltic activity. Small and large intestine



**PATIENT**

demonstrated normal luminal chyme and stool consistency respectively. No obstructive or overt infiltrative disease was noted. No associated abnormal lymphatic activity was noted.

Laguna Dorris

**SPECIES**

**Pancreas**

Canine

The base and limbs of the **pancreas** were observed to be largely isoechoic to surrounding omental fat. Pancreatic duct and capsular contour were acceptably normal and parenchyma respected normal curvilinear patterns. No overt evidence of active inflammatory or neoplastic disease was noted.

**BREED**

Labrador Retriever

**ULTRASONOGRAPHIC FINDINGS**

**SEX**

Normal urinary tract.

Spayed female

**INTERPRETATION OF THE FINDINGS & FURTHER RECOMMENDATIONS**

**AGE**

There was no evidence of ectopic ureters that I would expect to see in a patient of this age with these views. Primary incontinence is suspected. Assessment for vaginal vestibular pathology as contributing clinical signs and/or behavioral issues. CT with contrast can be considered to assess for ectopic ureter further, yet all of the typical regions of ureteral ectopy were imaged without evidence of abnormalities.

1 year

**WEIGHT**

46.8 lbs

**INTERPRETED BY**

Eric Lindquist, DMV  
DABVP, Cert. IVUSS

**IMAGING PERFORMED BY**

Dr. Dorris

**HOSPITAL NAME**

County Line VC

**REFERRING VET**

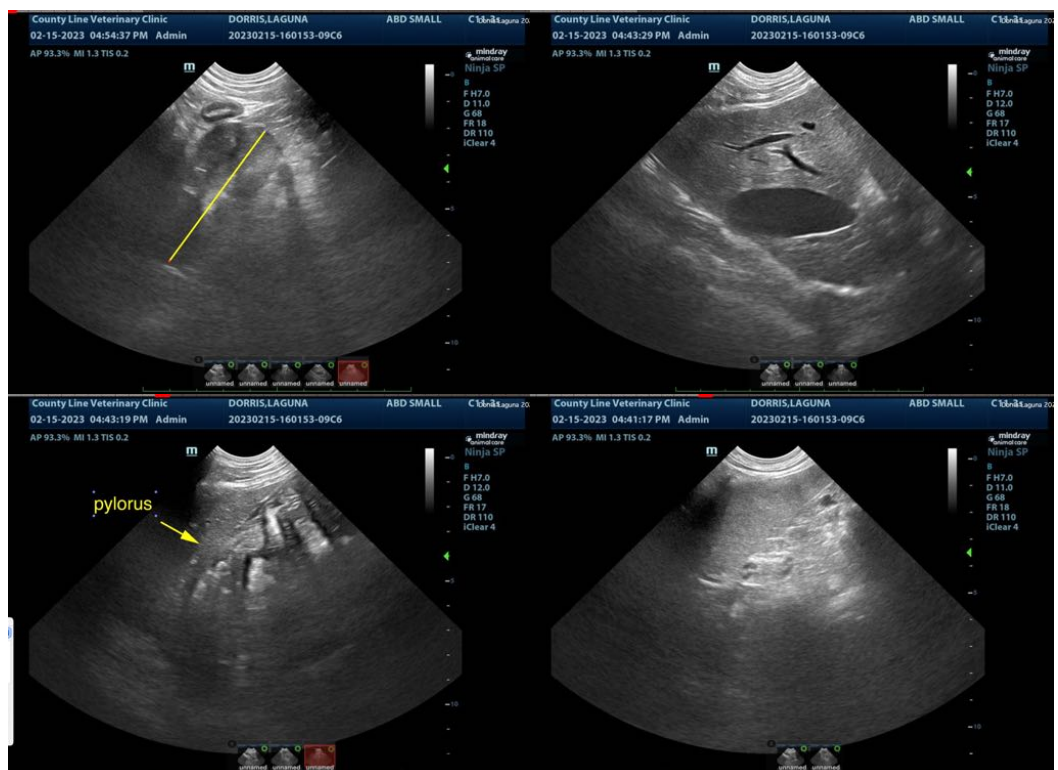Dr. Dorris

**INVOICE**

42849

**DATE**

2/15/23





**PATIENT**

Laguna Dorris

**SPECIES**

Canine

**BREED**

Labrador Retriever

**SEX**

Spayed female

**AGE**

1 year

**WEIGHT**

46.8 lbs

**INTERPRETED BY**

Eric Lindquist, DMV  
DABVP, Cert. IVUSS

**IMAGING PERFORMED BY**

Dr. Dorris

**HOSPITAL NAME**

County Line VC

**REFERRING VET**

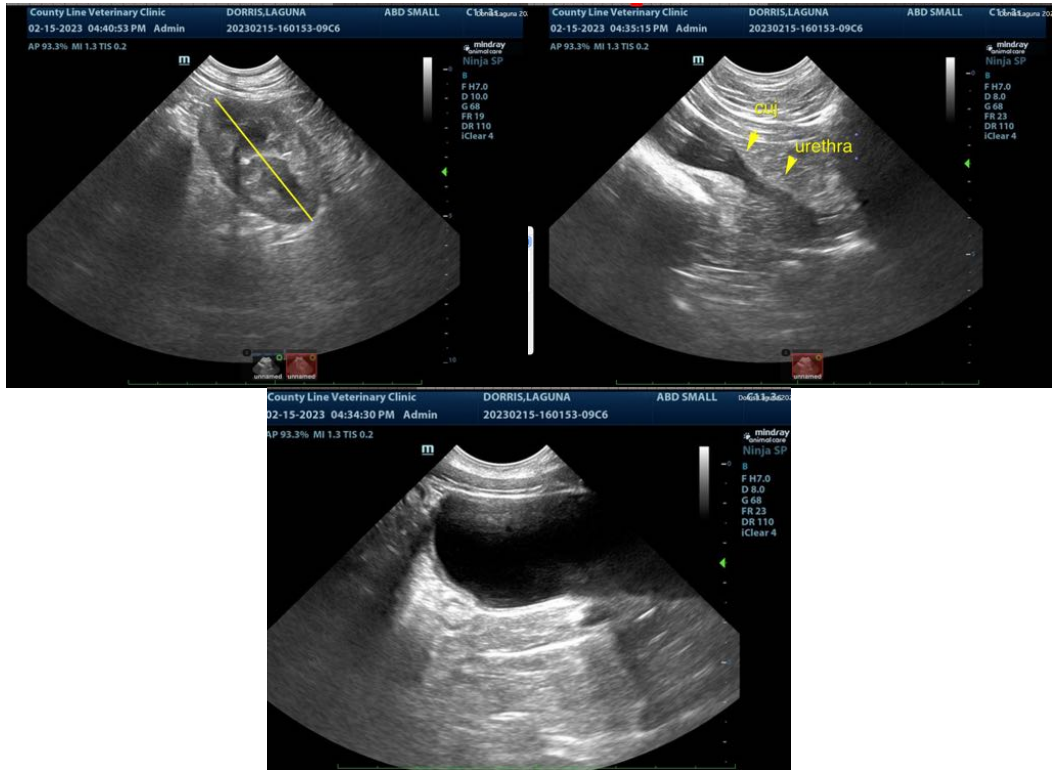
Dr. Dorris

**INVOICE**

42849

**DATE**

2/15/23



The information and recommendations provided are based on the images presented by the referring veterinarian/sonographer. No evaluation can be communicated regarding pathology that was not visible in the image/video clips provided.

Thank you for this referral. If the clinical or image interpretation does not parallel your findings or if I can be of any further assistance please contact me.

**Eric Lindquist, DMV, DABVP, Cert. IVUSS, CEO of SonoPath.com**  
info@SonoPath.com